Bojan Dj. Ćirić

ULTRASOUND-ASSISTED LIPOSUCTION
and ancillary procedures

ULTRAZVUKOM -ASISTIRANA LIPOSUKCIJA
i komplementarne tehnike

ULTRASOUND-ASSISTED LIPOSUCTION

and ancillary procedures

advanced aesthetic surgery and anesthesia

ULTRAZVUKOM-ASISTIRANA LIPOSUKCIJA

i komplementarne tehnike

moderna estetska hirurgija i anestezija

Bojan Dj. Ćirić

Author

Bojan Dj. Ciric, Dr. med. (MD)
Aesthetic, Plastic and Reconstructive surgeon, Laser Surgery, Cosmetic Phlebology. Director of Aesthetic, Plastic & Laser Surgery Deparment at the "Royal" Aesthetic Laser Center (ALC), Belgrade, Serbia

Coauthors

Gordan Malivukovic, Dr. med. (MD)
Anesthesiology, Reanimation and Pain Management. Director of Anesthesiology, Reanimation & Pain Management Deparment at the "Royal" Aesthetic Laser Center (ALC), Belgrade, Serbia

Ljiljana Paunkovic, Dr. med. (MD)
Plastic Reconstructive Surgery, Hand Surgery, Plastic Surgery Department at the University Hospital in Nis, Serbia

Predrag Kovacevic, Dr. med. (MD PhD)
Plastic Reconstructive Surgery, Hand Surgery, Plastic Surgery Department at the University Hospital in Nis, Serbia

Vesna Lackovic, Dr. med. (MD PhD)
Professor at the Institute of Histology and Embryology "Aleksandar Dj. Kostic" at the University of Belgrade, Serbia

Foreword in signature

Milan Visnjic, MD, PhD.
Professor of the plastic and reconstructive surgery, dean of the Medical faculty in Nis, Serbia

Bruce Connell, MD
Professor of plastic and reconstructive surgery, University Clinic Irvine, California

Michele Zocchi, MD, Ph.D.
Associate Professor in Plastic and Reconstructive Surgery and Honorary President of International Society of Ultrasound Surgery (ISUS), Torino, Italy. Inventor of UAL technology and UAL technique

Rod J. Rochrich, MD. Ph. D.
Professor and Chairman, Department of Plastic Surgery, Holder of Crystal Charity Ball Distinguished Chair in Plastic Surgery, The University of Texas Southwestern Medical Center, Dalas, Texas. Author of first complete UAL Book in the world

Carlo Gasperoni, MD, Ph.D.
Professor of Astehetic Surgery, Rome

Stanoje Glisic, MD, Ph.D.
Professor of Anesthesia and Reanimation at the University of Belgrade, Serbia

Julius Newman, MD. Ph.D.
Aesthetic, Plastic and Reconstructive Surgeon, Former President of American Academy of Cosmetic Surgery, publisher of the Journal of Aesthetic and Restorative Surgery. USA

Excerpt from the Review

The Book under the title:

"Ultrasound-assisted Liposuction and ancillary procedures" makes a valuable contribution to the practical work, especially as the subject matter has been examined from the aspect of surgery and anaesthetics. The second part of the book deals with dermolipectomy which very often must be compatible with liposuction, as it is irrelevant whether it is undertaken prior or after liposuction.

This book should be a good groundwork for all doctors who are about to begin practising liposuction as well as for doctors doing specialization courses.

Nišu, 04th June 2003.

Reviewed by

Prof. Dr Milan M. Visnjic

Full professor at the Medical Faculty, University of Nis

Specialist in plastic, reconstructive and general surgery

Izvod iz Recenzije

Knjiga pod nazivom:

"Ultrazvukom asistirana liposukcija i komplementarne tehnike", predstavlja dobar doprinos u praktičnom radu, posebno zato što je sagledan sa aspekta hirurgije i anestezije. U drugom delu knjige je prikazana i dermolitektomija koja vrlo često mora da bude kompatibilna sa liposukcijom, bez obzira da li se radila pre ili nakon liposukcije.

Ova knjiga bi trebalo da bude dobra osnova za sve lekare koji započinju da rade liposukciju i za lekare na specijalizaciji.

U Nišu, 04.06.2003.

Recenzent

Prof. dr Milan M. Višnjić

Redovni profesor Medicinskog fakulteta u Nišu

Specijalista plastične, rekonstruktivne i opšte hirurgije

This practical and scientific review reveals some of the most secretly kept tricks and trumps of UAL surgery and anesthesiology. We have the honor to be the first to publish a bilingual book in the field of medicine in English and Serbian. This work is dedicated to our colleagues and colleagues-to-be, to all esthetic surgeons and anesthesiologists. Our goal is to allow for the permanent and continuous education.

* * *

Ovaj praktični i naučni pregled otkriva neke od najbolje čuvanih trikova i aduta ultrazvukom asistirane liposukcije i anesteziologije. Mi imamo čast da smo prvi koji izdajemo dvojezičnu knjigu iz oblasti medicine, i to na engleskom i srpskom jeziku. Ovaj svoj rad posvećujemo kolegama i budućim kolegama, svim plastičnim hirurzima i anesteziolozima. Naš cilj je da omogućimo permanentno i kontinuirano dalje obrazovanje.

Foreword

This book would never have been written were it not for my parents, Vidosava and Djordje Ciric, who are both engineers. In addition to being extremely grateful for the genes I inherited from them, I would like to thank them for their endeavors to simultaneously develop and encourage my artistic and intellectual potentialities which they have done so unselfishly and with lots of love ever since my earliest childhood.

I would also like to thank my colleagues and friends, Dr Gordan Malivukovic, MD, anesthesiologist, for his assistance in making of a part of this book concerned with anesthesia, and Dr Ljiljana Paunkovic, MD, from the Plastic Surgery Department of the Clinical Center in Nis, and the Medical School of the Nis University, for the part of this book concerning dermolipectomy.

Special thanks to my great friend and director of the Anatomy Department at the Institute of the Medical Faculty in Belgrade, Professor Dr. A. Ilic, for his immeasurable help in making this book, both as an expert and as a friend.

Sincerest thanks to the European professors, innovators and friends, Kessering, Illouz, Fournier, Gasperoni, Gasparotti, Toledo, Katalinic and Zocchi, for the ingenious ideas, comprehensive scientific research, and experience they have unselfishly conveyed to us, their young colleagues.

Many thanks to the experts from Dallas, professor Rochrich and his associates for the methodical approach, expertise and sincerity they invested in making of their first book on UAL, which has been very helpful to me while writing this book. ■

Uvod

Ova knjiga sigurno ne bi bila napisana, da nije bilo mojih roditelja Vidosave i Đorđa, dipl. inženjera tehnologije. Osim genetike koju sam nasledio od njih, zahvalan sam im što su nesebično i sa puno ljubavi od ranog detinjstva paralelno razvijali i podsticali moje umetničke i intelektualne sposobnosti.

Zahvalan sam kolegama i prijateljima Dr. sci. med. Gordanu Malivukoviću, anesteziologu, na saradnji u izradi dela knjige vezanog za anesteziju i Dr. med. Ljiljani Paunković sa klinike za plastičnu hirurgiju Kliničkog centra Niš, Medicinskog fakulteta Univerziteta u Nišu za izradu dela vezanog za dermolipektomiju.

Posebno hvala mom velikom prijatelju, direktoru Instituta za anatomiju Beogradskog medicinskog fakulteta, Profesoru Dr. sci. med. Aleksandru Iliću, na neizmernoj stručnoj i prijateljskoj pomoći u izradi ovog pisanog dela.

Veliko hvala evropskim profesorima, inovatorima i prijateljima Kessering-u, Illouz-u, Fournier-u, Gasperoni-ju, Gasparotti-ju, Toledu, Katalinić-u i Zocchi-ju na genijalnim idejama, iscrpnom naučnom radu i iskustvu koje su nesebično prenosili na nas, mlađe kolege.

Zahvaljujem se ekspertima iz Dallas-a, Profesoru Rochrich-u i ostalim kolegama na sistematičnosti, stručnosti i iskrenosti u izradi njihove prve knjige o UAL, koja mi je u mnogome bila od pomoći u izradi ovog dela. ■



Preface

My First Contact with Liposuction

It was back in 1989 in Germany when I first met with liposuction. To my amazement, a very famous and capable plastic surgeon tried to convince me that the real aesthetic liposuction was a very simple intervention which comes down to reduction of the subcutaneous fatty tissue. Reduction liposuction, as its name says, is related to the aspiration of deep layers of fatty tissue in adipose patients. Liposculpting of the fine problem zones is still a taboo.

Shortly after Gasperoni and Gasparotti published their works on superficial liposuction, I met M. Gasparotti in 1993. By the middle of 1994, the two of us organized the first *Course on Superficial Liposuction* under auspices of the German Association for Esthetic Plastic Surgery in Nuernberg, Germany. We were met with great suspicions, but after the successful completion of the Course, the colleagues realized that this was one of the greatest accomplishments in the field of esthetic surgery.

By the end of 1994, at the UAL courses in Germany I discovered the ultrasound method. In 1995 I began to use it. However, before starting to use the ultrasound system, I realized how necessary it is to possess an exceptionally good knowledge of the ultrasound physics as well as the fundamental experience with SAL. Thorough education on ultrasound application and at least one hands-on training are preconditioning a successful operation and minimizing possible complications.

The initial enthusiasm and euphoria related to the use of ultrasound use are abating. This is less due to the published complications of thermal skin damages and necrosis in a small number of patients, but rather to the

Predgovor

Prvi kontakt sa liposukcijom

Moj prvi susret sa liposukcijom bio je u Nemačkoj 1989. godine. Bio sam iznenađen izjavom tako poznatog i sposobnog plastičnog hirurga da me ubedi da je prava estetska liposukcija vrlo jednostavan zahvat koji se svodi na redukciju potkožnog masnog tkiva. Redukciona liposukcija, kao što samo ime kaže, vezana je za aspiraciju dubokih slojeva masnog tkiva kod adipoznih osoba. Skulpturiranje određenih anatomskih regija veoma dugo je bilo tabu za primenu liposukcije.

Neposredno posle objavljivanja Gasperoni-jevih I Gasparotti-jevih radova vezanih za Superficijelnu liposukciju, upoznajem se 1993. god. sa M. Gasparottijem i sredinom 1994. organizujemo prvi *Kurs Superficijalne Liposukcije* pod pokroviteljstvom Nemačkog udruženja za estetsku plastičnu hirurgiju u Nürnbergu (Nemačka). Dočekani smo sa velikom skepsom, ali nakon uspešnog Kursa kolege su uvidele da to predstavlja jedan od najvećih dometa estetske hirurgije.

Krajem 1994. prvi put se srećem sa Ultrazvučnom metodom na kursevima za UAL (ultrazvukom potpomognutu liposukciju) u Nemačkoj, a 1995. počinjem da koristim UAL metodu. Pre samog početka rada sa ultrazvučnim sistemom shvatio sam da je neophodno izuzetno poznavanje fizike ultrazvuka i prethodno uspešno iskustvo sa SAL. Detaljna edukacija u radu sa ultrazvukom i minimalno jedan praktični trening preduslov su za estetski rezultat bez, ili sa neznatnim ali retkim komplikacijama.

Početni entuzijazam i euforija vezana za upotrebu ultrazvuka smanjuje se tokom vremena, ne toliko zbog objavljenih komplikacija termičkog oštećenja kože i nekroze kod vrlo malog broja pacijenata, već zbog visoke

high price of the apparatus itself and the surgeon's fear of the unfamiliar and new high technologies.

Complications such as burns and necrosis are the consequences of the inadequate knowledge of physics, unfamiliarity with ultrasound mechanisms, incorrect power setting, inappropriate use of the solid probe, as well as inappropriate selection of patients (heavy smokers and/or diabetics). However, every advanced high-tech method is a privilege of a small number of technically educated and talented plastic surgeons, specialized for the field of esthetic surgery.

In 1998, Rorich, Beran and Kenkel, plastic surgeons from Dallas, published a book on ultrasound-assisted liposuction. This book was the first to present the carefully processed data, beginning with the physics and ultrasound waves mechanisms, through the numerous advises on high technology application and exceptional postoperative results, to the hazards laying in inappropriate application of the high-tech apparatuses in UAL. ■

cene samog uređaja i nepoznavanja nove visoke tehnologije od strane plastičnog hirurga.

Opisane komplikacije tipa opekotine i nekroze nastaju kao posledica nedovoljnog znanja iz oblasti fizike, nepoznavanja mehanizma dejstva ultrazvuka, pogrešnog podešavanja snage, neodgovarajuće upotrebe sonde, kao i neadekvatnog izbora pacijenata (teški pušači i/ili dijabetičari). Ipak kao svaka moderna napredna high-tech metoda, UAL je privilegija manjeg broja tehnički obrazovanih i talentovanih plastičnih hirurga, usko specijalizovanih na polju estetske hirurgije.

Rorich, Beran i Kenkel, plastični hirurzi iz Dallasa 1998. objavljuju knjigu o ultrazvučnoj liposukciji. U toj knjizi se prvi put pojavljuju brižljivo obrađeni podaci vezani za izvođenje UAL, mehanizme dejstva ultrazvučnog talasa, i načina izvođenja same UAL. Primenom UAL koja je bazirana na principima visoke tehnologije oni su izneli veoma pozitivne rezultate sa malobrojnim i beznačajnim komplikacijama. ■



Contents

Sadržaj

SAL
(Suction-Assisted Liposuction)

Suction-Assisted Liposuction - SAL (closed aspiration lipectomy) is today a most frequently performed plastic surgery procedure. UAL is the youngest esthetic surgery operation rapidly evolving with the global high-tech development.

A Short History of the Liposuction Development

Ever since the beginning of time, women dreamt of being slim and attractive. It would be wrong to think that in any era in the past women sincerely considered fat layers around the body to be the ideal of beauty (Y.G. Illouz).

In 1929, Dujarrier tried to model a famous ballet dancer's leg with a sharp cannula. His endeavor resulted in amputation of the leg necessitated by injury of large blood vessels.

In 1972, German author Schrude described a method of sharp curettage with a small incision and use of gynecological cannulas. This technique of fatty tissue curettage above fascia was rejected because of the post-operative complications such as extensive bleeding and necrosis.

By the middle 70's, A. G. Fischer separated fatty tissue with so-called "Plantom" which is afterwards electro-triturated and absorbed. In female patients with "saddlebag" area, contemporary statistics recorded more than 30% seroma incidence after this procedure.

In 1976, Kesselring and Mayer, plastic surgeons from Geneva were aspirating fatty tissue with big sharp suction-cannulas connected to the aspiration apparatus. This method was rejected because of the numerous

SAL
(Standardna aspiraciona Liposukcija)

Liposukcija uopšte (zatvorena aspiraciona lipektomija) je trenutno najčešće rađena estetska operacija u svetu. Međutim, UAL je jedna od najsavremenijih estetskih operacija, čiji je napredak uslovljen naglim razvojem visoke tehnologije.

Kratki istorijat i razvoj liposukcije

Od antičkih vremena žene sanjaju o tome da budu vitke i atraktivne. Bilo bi pogrešno ako bi verovali da je u bilo kom od prošlih vekova neka od žena iskreno smatrala da su debljina i obruči masti oko tela ikada bili ideal lepote (Y.G. Illouz).

Dujarrier 1929. je pokušao da modelira nogu jedne poznate balerine pomoću oštre kanile. Ovaj pokušaj završio se amputacijom noge usled povrede velikih krvnih sudova.

Nemac Schrude 1972. opisao je metodu oštre kiretaže kroz malu inciziju uz upotrebu ginekoloških kanila. Ova tehnika kiretaže masnog tkiva tik iznad fascije je odbačena usled postoperativnih komplikacija kao što su obilno krvarenje i nekroze.

Sredinom sedamdesetih godina A. G. Fischer razdvaja masno tkivo koristeći tzv. "Plantom" da bi ga nakon toga uz pomoć električne freze samleo i usisao. Ova procedura praćena je kod pacijentkinja sa jahaćim pantalonicama sa pojavom seroma iznad 30%

Kesselring i Mayer, 1976, plastični hirurzi iz Ženeve, pokušali su da upotrebom oštrih velikih sukcionih kanila povezanih sa aspiracionim aparatom urade sukciju masnog tkiva. Zbog velikog broja komplikacija metoda je odbačena.

complications it evoked.

In 1977, a French surgeon Y.G. Illouz developed a concept of fatty tissue tunneling with fine, rounded suction-cannulas. That was a beginning of the so-called deep dry liposuction era.

We should mention a tremendous contribution of Fournier as a representative of the French school of liposuction and underline his exceptional role in popularization and development of both the traditional and modified liposuction method.

American dermatologist Klein introduced tumescent technique in 1977. This technique involves infiltration of a large quantity of solution in combination with local anesthetic and adrenaline (several liters) to the point of edema or tumescence, ratio of infiltrate and aspirate being 1:3.

This technique is undergoing multitudinous modifications.

In 1988 Italian plastic surgeon Gasperoni published his technique of so-called Superficial liposuction.

In 1989, Italian author Marco Gasparotti published a book titled Superficial Liposuction. His technique is based on the controlled retraction of skin and sub-dermal fatty tissue through cicatrization of the numerous fine, intersecting, superficially-placed tunnels. An accurately made, very thin lipocutaneous flap will enable excellent skin retraction and help avoid gravitation-induced sagging of the fat flap which is a frequent occurrence in deep liposuction. The same cannulas are used for final contouring of the problem zone borders, but the suction process is now replaced by hand modeling (importance of G-point for creation of the perfect gluteal silhouette is described below).

In our opinion, Gasperoni's, Gasparotti's and Toledo's work delineated the summit and signaled the end of the isolated SAL epoch. We are now at the beginning of the age of ultrasound-assisted liposuction as the independent or SAL-combined method applied according to the principle similar to that favored by Illouz, Gasperoni and Gasparotti. It is important to underline that in SAL following UAL procedure, very fine cannulas do not evacuate particles of the "solid" fatty tissue but the ultrasound-induced emulsion.

In 1988, Michele Zocchi introduced a new method of ultrasound liposuction that enabled selective reduction of fatty tissue by use of ultrasound energy. He extended its application to all parts of the body and face.

Francuski hirurg Illouz 1977. razvija koncept tuneliranja masnog tkiva uz upotrebu tupih tanjih sukcionih kanila. Time otpočinje era takozvane duboke suve liposukcije.

Treba navesti izuzetni doprinos Fournier-a kao predstavnika francuske škole liposukcije i naglasiti njegov značaj u popularizaciji i razvoju tradicionalne i modifikovane metode liposukcije.

Američki dermatolog Klein 1987 uvodi Tumescentnu tehniku. Ova tehnika podrazumeva infiltraciju velike količine rastvora u kombinaciji sa lokalnim anestetikom i adrenalinom (nekoliko litara), do odnosa infiltrata i aspirata od 1:3.

Ova tehnika doživljava mnogobrojne modifikacije.

Italijanski profesor Gasperoni objavljuje svoj koncept vezan za superficijalnu liposukciju a neposredno nakon toga Marco Gasparotti 1989. objavljuje svoju tehniku u knjizi "Superficijalna liposukcija". Gasparotijeva tehnika bazirana je na kontrolisanoj retrakciji kože i subdermalnog masnog tkiva putem cikatrizacije mnoštva ukrštenih uskih superficijalno plasiranih tunela. Preciznim kreiranjem vrlo tankog lipokutanog režnja (*cutaneous adipose flap*) omogućava se odlična retrakcija kože i izbegava gravitacijom uslovljeni pad debelog režnja (*sagging*) kao u duboke liposukcije. U finalnom konturiranju granica problem zona, koristi iste kanile ali je sukcija zamenjena ručnim modeliranjem (u daljem tekstu je opisana važnost G-point-a u kreiranju perfektne glutealne siluete).

Smatramo da se sa Gasperonijevim i Gasparotijevim radovima dostiže vrhunac i završava era izolovane SAL (*Suction Assisted Liposuction*). Počinje era Ultazvučne UAL liposukcije kao samostalne metode ili kao kombinovane sa SAL po principu sličnom Illouz-vom i Gasparotti-jevom. Bitno je naglasiti da se kod SAL nakon izvedene UAL vrlo tankim kanilama aspirira emulzija nastala radom ultrazvuka ne partikule "čvrstog" masnog tkiva.

Michele Zocchi 1988. uvodi novu metodu ultrazvučne liposukcije koja omogućava selektivnu redukciju masnog tkiva pomoću energije ultrazvuka i proširuje aplikaciju na sve delove tela i lica. ■

Definition of the Standard Suction-Assisted Liposuction (SAL)

Liposuction is a method of vacuuming fatty tissue with blunt-tip cannulas inserted into the subcutaneous

Definicija Standardne aspiracione liposukcije (SAL)

Liposukcija je metoda aspiracije potkožnog masnog tkiva snagom vakuuma. Kod liposukcije se plasiraju tupe

fatty tissue through incisions on the skin. Liposuction cannula has one or more side openings close to the tip. On the opposite end, it is connected to the vacuum aspirator through a silicone tube. The aspirate suctioned through the cannula opening is then vacuumed through the cannula cavity and silicone tube and deposited in a glass or plastic jar of the aspiration system. Through the embedded filter, the silicone tube connects the opposite end of a depot-jar directly to the aspiration apparatus. Role of the filter is to prevent the aspirate transition into the aspiration system.

Survey of Different SAL Techniques:

- Dry Liposuction Technique: Performed without previous infiltration by cannulas of large radius. Operation is relatively simple, but involves blood loss up to 45 % of the total aspirate volume.
- Wet Technique: Involves infiltration of the physiological solution into the fatty tissue in combination with adrenaline. Introduction of this method in the beginning of the 80's lowered blood loss by 15 to 30%.
- "Superwet" Technique: Involves infiltration of the solution into the fatty tissue in a ratio of 1:1 infiltrate to aspirate. Fodor presented this technique in 1986.
- Tumescent Technique: Involves infiltration of the solution to produce tissue turgor or fatty tissue edema in the ratio of 3:1 infiltrate to aspirate. This revolutionary technique was presented by Klein in 1987 and today it is considered state-of-the-art in the Standard Aspiration as well as a precondition for Ultrasound Liposuction execution.

Advantages of the tumescent technique:

Pressure of the injected liquid with adrenaline in the fatty tissue (and pressure on the skin) invoke capillary spasm and result in minimal blood and serum loss. A part of the infiltrated liquid (see details in the heading referring to the anesthesia) is resorbed during the intervention and thus compensates for the loss of liquid. Tumescent technique enables much larger aspirate volume and consequently more precise contouring of the infiltrated region. By adding the local anesthetic into the solution, the intervention can be performed under local anesthesia; the patient is cooperative, he can control his musculature, which provides better insight into the relief of the treated region. ■



kanile kroz kožne incizije u potkožno masno tkivo. Liposukciona kanila poseduje jedan ili više otvora sa strane, lociranih blizu vrha kanile. Na drugom kraju je preko silikonskog creva povezana sa vakuum aspiratorom. Aspirat usisan preko otvora kanile vučen snagom vakuuma prolazi kroz šupljinu kanile, kroz silikonsko crevo i deponuje se u staklenoj ili plastičnoj posudi na aspiracionom sistemu. Depo posuda je na drugom kraju povezana silikon crevom preko umetnutog filtera direktno za aspiracioni uređaj. Filter sprečava eventualni prolazak aspirata u sam aspiracioni sistem.

Pregled različitih Sukcijom Asistiranih Liposukcija (SAL):

- Suva Liposukcija: Izvodi se bez prethodne infiltracije rastvora kanilama velikog promera . Operacija je relativno jednostavna, ali je vezana za gubitak krvi, do 45% od totalnog volumena aspirata.
- Vlažna Liposukcija: Podrazumeva infiltraciju fiziološkog rastvora u masno tkivo u kombinaciji sa adrenalinom. Početkom osamdesetih godina počela je da se primenjuje ova metoda koja dovodi do minimalnih gubitaka krvi, od 15 do 30% u odnosu na totalni volumen aspirata.
- Supervlažna Liposukcija: Podrazumeva infiltraciju rastvora u masno tkivo u takvoj količini, da odnos ubrizganog rastvora bude jednak sa aspiriranom količinom. Tehnika je prezentovana 1986. od strane Fodor-a.
- Tumescentna Liposukcija: Podrazumeva infiltraciju rastvora u potkožno masno tkivo do stvaranja tkivnog otoka na čijoj površini je koža zategnuta i bleda. Odnos između infiltracije i aspiracije je 3:1. Ova revolucionarna tehnika je predstavljena od strane Klein-a 1987. i predstavlja visoki estetski domet u Standardnoj Aspiracionoj i preduslov je za izvođenje Ultrazvučne Liposukcije.

U odnosu na prethodne metode tumescentna tehnika ima mogobrojne prednosti:

Pritisak ubrizgane tečnosti sa adrenalinom u masnom tkivu izaziva spazam kapilara i dovodi do minimalnog gubitka krvi i seruma. Jedan deo infiltrirane tečnosti (detalji u delu vezanom za anesteziju) se za vreme intervencije resorbuje i nadoknađuje gubitak tečnosti. Tumescentna tehnika omogućava aspiraciju daleko većih količina masnog tkiva i egzaktnije modeliranje infiltriranog regiona. Dodavanjem lokalnog anestetika u rastvor intervencija se može izvesti u lokalnoj anesteziji. Pacijent je kooperativan i u stanju je da kontroliše svoju muskulaturu, što pruža bolji uvid u reljef tretiranog regiona. ■

Ultrasound-Assisted Liposuction (UAL)

Definition

Ultrasound-Assisted Liposuction (UAL) is sculpting of fatty tissue of face and body by using the ultrasound wave energy emitted by the solid probe inserted into the subcutaneous tissue of the face or body through a small incision on the skin.

UAL is not a substitute for Suction Assisted Liposuction or SAL, but rather it is a complementary procedure to improve results. UAL uses different method of fatty tissue removal, but quantity and type of the removed fatty tissue are the same. UAL is complementary to the SAL method in optimization and maximization of the face and body contouring. UAL is a perfect method for correction of the unevenness and cavities resulting from the traditional SAL.

Principle of operation

UAL is performed through emulsification of the adipose tissue by principle of fatty tissue implosion provoked by the fatty cell resistance to the ultrasound wave spreading, while the whole process is known as the cavitation process.

Ultrazvukom Asistirana Liposukcija (UAL)

Definicija

Ultrazvukom Asistirana Liposukcija (UAL) podrazumeva skulpturiranje masnog tkiva tela i lica pomoću energije ultrazvučnog talasa koju emituje titanijumska sonda uvedena u potkožno tkivo kroz malu inciziju na koži.

UAL ne predstavlja zamenu za SAL, već uspešnu nadgradnju za sukcijom asistiranu liposukciju, tzv. SAL. UAL se razlikuje u načinu odstranjivanja masnog tkiva, ali ne u količini i tipu masnog tkiva koje je odstranjeno. UAL je komplementarna metoda SAL metodi u optimiranju i maksimiranju konturiranja lica i tela. UAL je idelna metoda za korekciju neravnina i jamica nastalih nakon tradicionalne SAL.

Princip rada

Otpor masnih ćelija prema prostiranju ultrazvučnih talasa dovodi do emulzifikacije adipoznog tkiva koja nastaju po principu implozije masnih ćelija, što uslovljava stvaranje manjih ili većih šupljina, odnosno kavitacija.

Cellulite and Striae (Stretchmarks)

Cellulite is a fairly observable skin alteration caused by specific architecture of the septal system of the subcutaneous fatty tissue.

Strechmarks are skin alterations with brighter pigmented stripes, with thinner and non-elastic surface, and are usually consequence of unadaptability of specific skin regions to changes of subcutaneous fatty tissue. In ultrasound therapy, stretchmarks are significantly and apparently diminished.

PHYSICS OF THE ULTRASOUND

Ultrasound waves are high-frequency mechanical waves, not to be confused with electromagnetic waves used in medicine (radio-surgery, lasers, etc.). In everyday life (vibrations from the city traffic, industrial and home appliances), as well as in medicine (diagnostic ultrasound, ultrasound scalpel used in neuro-surgery and ophthalmology), we are continuously in contact with ultrasound waves. There are no adverse effects unless we are exposed to a huge quantity of ultrasound energy.

Ultrasound selectively destroys fatty tissue simultaneously respecting the surroundings. Bleeding is insignificant, so-called "red component" in the yellow aspirate is less than 1% of the total aspirate quantity and max. 2% in the ultrasound superficial treatment of cellulite. The movement of the probe through the subcutaneous fatty tissue must be smooth, rectilinear and without twisting of the probe. The lifting effect on the skin is achieved by superficially applied ultrasound, i.e. by the smooth movement of probe directly below the skin. (Dr Santiago Trunó Reina, Barcelona; extract from his *Medicina Estetika*, published by the Spanish Association of Aesthetic Medicine.)

THE CONCEPT OF THE ULTRASOUND
More Efficient Liposuction and Safety Issues

Regardless of the fact that plastic surgeons readily accept new clinical techniques such as UAL, they are not always enthusiastic about familiarizing themselves with physical characteristics which are the base of these technologies' operation. However, a basic working knowledge of ultrasound physics is essential to perform this procedure appropriately and safely. UAL has distinct advantages for body contouring surgery, but there are also potential hazards that must be understood and respected. Understanding how UAL functions is a key for the safe operation of equipment and prevention of serious complications related to this procedure.

Celulitis i strije

Celulitis je dobro uočljiva promena na koži koja je uslovljena specifičnom arhitekturom septalnog sistema potkožnog masnog tkiva.

Strije su promene na koži u vidu svetlije pigmentovanih pruga čija je površina istanjena i neelastična, a obično nastaju kao rezultat neadaptibilnosti određenih regija kože na promenu u potkožnom masnom tkivu. U ultrazvučnoj terapiji strija dobija se bitno i vidljivo poboljšanje.

FIZIKA ULTRAZVUKA

Ultrazvučni talas je mehanički talas visoke frekvencije. Bitno je naglasiti da se Ultarzvuk (UZ) nikako ne treba mešati sa elektromagnetnim talasima u medicini (npr. radiohirurgija, laseri). Kako u svakodnevnom životu (vibracije od gradskog saobraćaja, industrijski kućni uređaji) tako i u medicini (dijagnostički ultrazvuk, ultrazvučni skalpel u neurohirurgiji i oftalmologiji) konstantno smo u kontaktu sa ultrazvučnim talasima. Ultrazvučni talasi nemaju štetno dejstvo na organizam sem ako nismo eksponirani ogromnoj količini UZ energije.

Ultrazvuk daje selektivnu destrukciju masnog tkiva ne oštećujući pri tome okolno tkivo. Pri primeni UZ kod UAL krvarenje je minimalno. Količina "crvene komponente" u zutom aspiratu je ispod 1% na totalnu količinu aspirata, a maksimalno 2% u slučaju ultrazvučnog superficijalnog tretmana celulitisa. Pomeranje sonde kroz potkozno masno tkivo mora biti lagano, usmereno pravolinijski i bez uvrtanja sonde. Lifting efekat kože se postiže superficijalnom aplikacijom ultrazvuka, tj, laganim pomeranjem sonde tik ispod kože. (Dr. Santiago Trunó Reina, Barcelona; izvod iz *Medicina Estetika*, izdanje Spanish Association of Aesthetic Medicine).

SHVATANJE ULTRAZVUKA
Efikasnija liposukcija i aspekti sigurnosti

Bez obzira na činjenicu da plastični hirurzi vrlo rado prihvataju nove kliničke metode kao što je UAL, oni, u osnovi, nisu uvek spremi da nauče sve principe koji su neophodni za uspešnu i sigurnu primenu novih tehnologija. Ipak, osnovno poznavanje fizike ultrazvuka je neophodno za adekvatno i bezbedno izvođenje ove procedure. UAL ima jasne prednosti kod hirurških zahvata konturiranja tela, ali postoje i potencijalne opasnosti koje se moraju shvatati i poštovati.

Dobra teoretska priprema i manuelna spretnost su ključ za bezbedno rukovanje opremom i prevencija ozbiljnih komplikacija koje su moguće kod ovog postupka.

What is ultrasound?

Sound is a form of mechanical energy that propagates in waves. The waves transfer energy from one point to another, but the means of transmission, the medium, does not actually move. These waves travel longitudinally through a medium containing matter such as air, water, or metal but cannot be transferred in a vacuum.

Sound waves can be graphically represented by a sine wave. The peak is the maximal positive deviation and the trough is the greatest negative deviation. The distance from peak to peak is the wavelength. The greatest distance above or below the average value is the amplitude. A cycle is one complete revolution from peak to trough to peak. Frequency is the number of cycles per second as measured in Hertz.

Ultrasound is acoustic energy, a mechanical wave at a frequency above 16,000 kHz, the upper limit of human hearing. Ultrasound has a variety of medical uses that take advantage of different ultrasound frequencies both for diagnostic and therapeutic purposes.

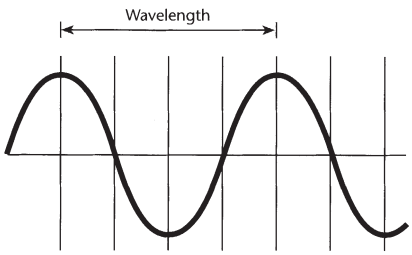

The transmission of sound waves is dependent on the medium through which they flow. Sound will not propagate within a vacuum, and the density of the medium is directly related to the speed of sound. Increased density correlates with increased speed. For example, sound propagates almost three times faster in bone than in fat.

Material	Velocity (m/sec)
Fat	1475
Liver	1570
Blood	1570
Muscle	1580
Bone	3360

The pressure changes produced by sound reflect its wave behavior. As the sound wave approaches a fixed point, the pressure will increase. As the wave passes this point, the pressure drops and a relative vacuum is created. It is this cyclic pressure change that creates cavitation (empty space) and cell implosion during UAL.

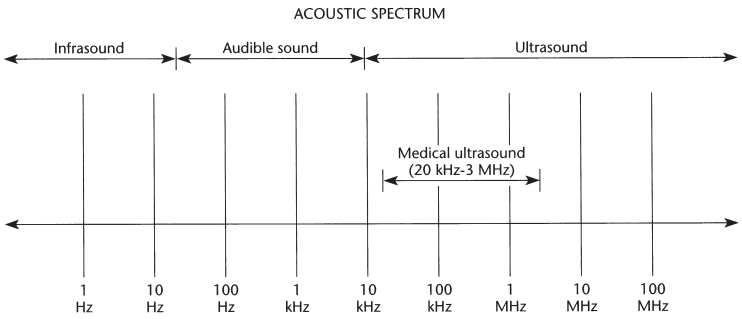

Šta je ultrazvuk?

Zvuk je oblik mehaničke energije koja se transmituje u obliku talasa. Zvučni talasi prenose energiju sa jedne na drugu tačku, dok se sredstvo transmisije ne pomera. Ovi talasi se kreću longitudialno kroz sredinu koja sadrži materiju kao što je vazduh, voda ili metal ali se ne mogu preneti u vakuum.

Talasi zvuka se mogu grafički prikazati sinusoidom. Vrh sinusoide je maksimalna pozitivna, a udubljenje je najniža negativna devijacija. Razdaljina između dva vrha predstavlja dužinu talasa. Najveća razdaljina iznad ili ispod prosečne vrednosti predstavlja amplitudu. Ciklus predstavjla jednu kompletnu revoluciju od vrha do dna pa do sledećeg vrha. Frekvencija je broj ciklusa u sekundi merena hercima.

Ultrazvuk je akustična energija, mehanički talas, na frekvenciji iznad 16.000 kHz, što predstavlja gornji nivo ljudskog sluha. Ultrazvuk ima različite primene u medicini koje koriste svojstva različitih frekvencija ultrazvuka, kako u dijagnostičke, tako i u terapijske svrhe.

Prenošenje, transmisija zvučnih talasa zavisi od sredine kroz koju talasi prolaze. Zvuk se ne prenosi u uslovima vakuuma, a gustina sredine je u direktnoj vezi s brzinom zvuka. Veća gustina je recipročno povezana sa povećanom brzinom. Na primer, zvuk prolazi tri puta brže kroz koštano nego kroz masno tkivo.

Materija	Brzina (m/sec)
Masno tkivo	1475
Jetra	1570
Krv	1570
Mišići	1580
Kost	3360

Promene pritiska izazvane zvukom održavaju se na ponašanje njegovih talasa. Dok se zvučni talas približava fiksiranoj tački, pritisak raste. Kada talas prođe ovu tačku pritisak opada i stvara se vakuum. Upravo ova ciklična promena pritiska izaziva kavitaciju (prazne prostore) i imploziju ćelija tokom UAL zahvata.

PRODUCTION OF ULTRASOUND

Ultrasound energy is created through the conversion of electric energy into mechanical energy. Mechanical energy, in form of high-speed vibrations, is amplified and directed to achieve the desired effects.

All modern surgical ultrasound technology uses one of two existing methods to produce sound waves: the piezoelectric crystal in UAL and the magnetostrictive transducer in the Cavitron Ultrasonic Surgical Aspirator (CUSA). Although both technologies are capable of transforming electric energy into mechanical energy, all current UAL technology uses piezoelectric crystals.

The magnetostrictive transducer used in the CUSA and other older technologies consists of nickel alloy wrapped around a core. An alternating electric current is run through the wire and mechanical vibrations are produced. These vibrations are then amplified and directed to the target tissue. Although this technology is still used in surgical dissectors, no current UAL technology uses this means to produce ultrasound.

The piezoelectric effect is the ability of certain crystals to undergo predictable deformation when subjected to alternating electric current. The application of electric energy to select crystals results in the displacement of ions and the expansion or contraction of the crystal. When these deformations are induced by the alternating current, the crystal will expand and contract with each electric cycle. These microscopic fluctuations, about 100 μm, produce vibrations at ultrasound frequencies.

STVARANJE ULTRAZVUKA

Ultrazvučni talasi nastaju pretvaranjem električne u mehaničku energiju. Mehanička energija se, u vidu brzih vibracija, pojačava i usmerava kako bi se postigao željeni efekat.

Postoje dve osnovne metode za stvaranje ultrazvučnih talasa: piezoelektrični kristal u UAL-u i magnetostrikcioni prenosni uređaj kod ultrazvučnog hirurškog aspiratora (CUSA). Bez obzira što ove tehnologije imaju sposobnost da električnu energiju pretvaraju u mehaničku, sve UAL tehnologije koje se danas primenjuju koriste piezoelektrične kristale.

Magnetnostriktivni prenosni uređaj koji se koristi u CUSA i kod još nekih starijih tehnologija sastoji se od legure nikla obmotane oko jezgra. Prolaskom naizmenične električne struje kroz žicu stvaraju se mehaničke vibracije. Ove vibracije se zatim pojačavaju i usmeravaju na određeno tkivo. Bez obzira što se ova tehnologija još uvek koristi kod hirurške disekcije, kod UAL se ne koristi ovaj metod za stvaranje ultrazvuka.

Piezoelektrični efekat je sposobnost nekih kristala da se deformišu odnosno da poprime unapred predviđeni oblik, kada se na njih deluje naizmeničnom električnom strujom. Kao rezultat primene električne energije kod određenih kristala dolazi do razmeštanja jona i do širenja ili kontrakcije kristala. Kada ovakve deformacije nastanu kao rezultat naizmenične struje, kristal se širi i skuplja pri svakom električnom ciklusu. Ovakve mikroskopske fluktuacije, od oko 100 mikrometara, stvaraju vibracije na ultrazvučnim frekvencijama.

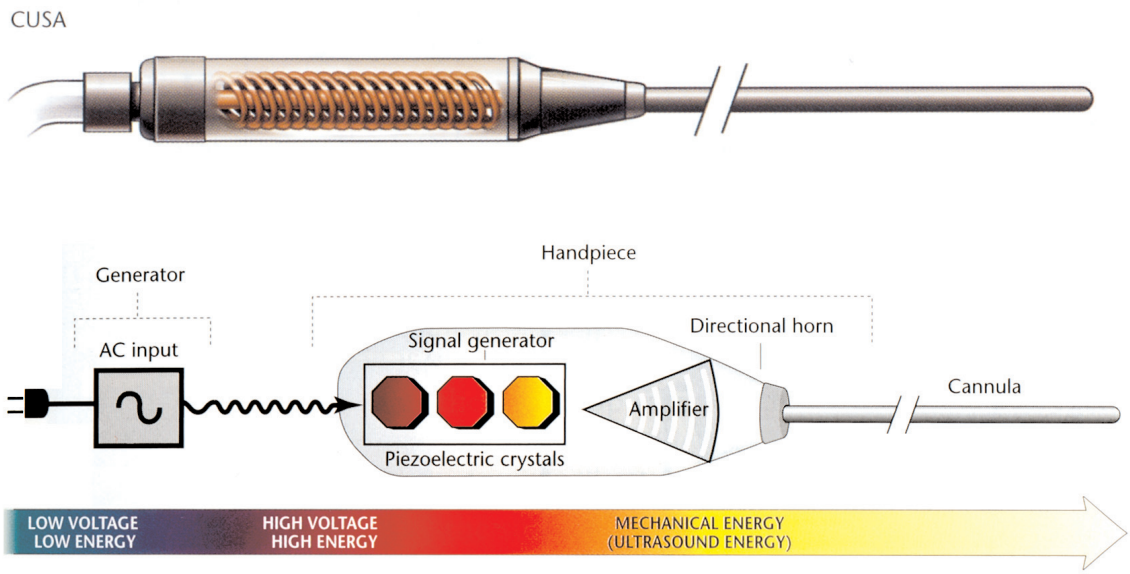

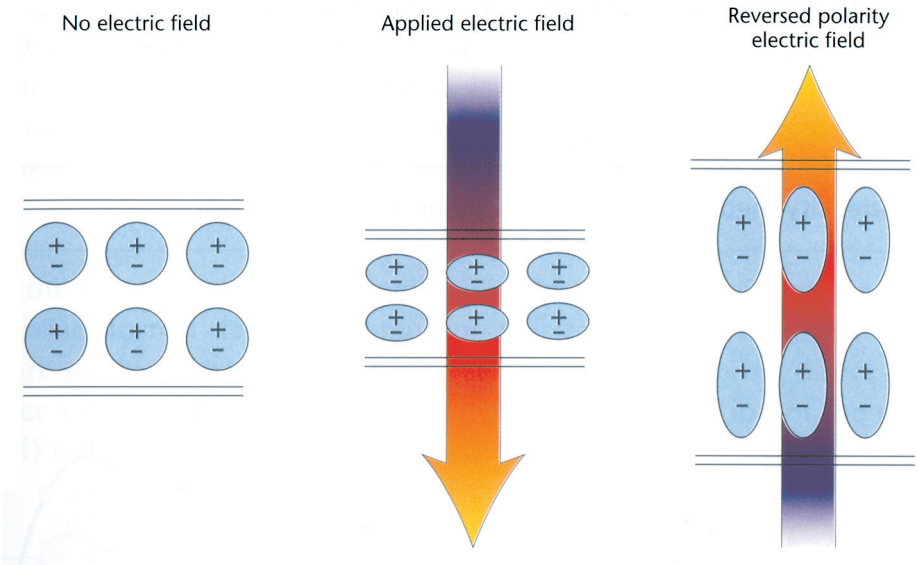

Piezoelectric crystals converse electric energy into mechanical vibrations or the ultrasound waves.

These vibrations are too weak to be sensed by humans or to have any tissue effects on their own; therefore the vibrations are relayed to an amplifier. The amplified sound is then directed to a probe and through the probe to the tissue.

EFFECTS ON THE TISSUE

There are three principal biologic effects of low-frequency ultrasound to the tissue: cavitation, thermal conversion and micromechanical disruption.

Cavitation

Introduction of the ultrasound probe into subcutaneous fatty tissue causes compression followed by rarefaction produced by ultrasound waves. This results in formation of gas microbubbles within the fat cell, which soon will implode, and the fat cell will loose the membrane integrity and its contents in the form of emulsion. This is how cavitation occurs. Low-density media such as adipose tissue have weak cohesive bonds and respond to the pressure drop of passing sound waves by forming microbubbles within potential spaces. Dense structures such as fascia or bone have strong molecular cohesive forces that resist the formation of microbubbles. Cavitation is a phenomenon restricted to low-density tissues.

Low-density media such as fat readily undergo cavitation.

The microbubbles within the fatty cell, caused by the ultrasound waves, may be stable or unstable. If the

Piezoelektrični kristali pretvaraju električnu energiju u mehaničke vibracije ili ultrazvučne talase.

Ove vibracije su slabe da bi ih čovek osetio i nemaju bilo kakvog uticaja na tkivo. To znači da se vibracije moraju pojačati, a to se postiže specijalnim aparatom (pojačavač). Pojačani ultrazvuk se zatim usmerava u sondu a kroz sondu u tkivo.

UTICAJ NA TKIVO

Postoje tri osnovna biološka uticaja koji nisko-frekventni ultrazvuk ima na tkivo: kavitacija, termička konverzija i mikromehanički proboj.

Kavitacija (stvaranje šupljina)

Uvođenjem UZ sonde u potkožno masno tkivo pod dejstvom UZ talasa dolazi do kompresije a zatim dekompresije, čiji je rezultat stvaranje gasnih mikromehurića u masnoj ćeliji koji ubrzo implodiraju a masna ćelija gubi integritet ćelijske membrane i svoj sadržaj u obliku emulzije. Na ovakav način nastaju šupljine odnosno kavitacije. Masno tkivo ima slabe veze spajanja (kohezije) i zato reaguje na pad pritiska zvučnih talasa koji prolaze tako da dolazi do formiranja mikromehurića na određenim mestima. Guste sredine kao što je fascia ili kost imaju jake molekularne kohezivne sile koje ne dozvoljavaju stvaranje mikromehurića. Kavitacija je fenomen koji se javlja jedino kod tkiva male gustine.

Kod sredina sa malom gustinom kao što je masno tkivo uvek dolazi do stvaranja kavitacija.

Mikromehurići u masnoj celiji, nastali dejstvom UZ talasa, mogu da budu stabilni i nestabilni. Ako su mikro-

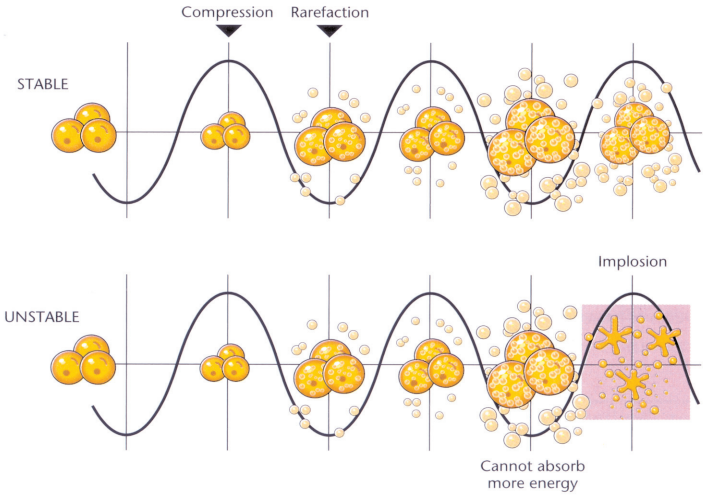

microbubbles are small and stable, they will expand and contract with each wave cycle, but cellular integrity will not be affected. If the microbubbles reach critical size, about 170 nm, they become unstable, implode and release their contents. The microbubbles are larger in the rarefaction phase when they are less frequent than in the compression phase. Gas diffusion in the fatty cell is proportional to surface area and the microbubbles will have a net increase in gas as more diffuses in than out. They will continue to grow larger with each rarefaction phase until they cannot absorb more energy. At this critical point the cell will implode violently, releasing its contents. The time to this critical point is dependent on the frequency and intensity of the sound waves. Higher intensity waves may reach a critical point in one or two cycles; lower intensity waves may take several cycles to reach critical size.

The goal of UAL is to maximize cavitation and minimize thermal and micromechanical effects.

The implosion of the cell releases cellular contents and also results in the production of intense heat. This

mehurići mali i stabilni, oni će se povećati i smanjivati pri svakom dejstvu ciklusa talasa, ali to ne dovodi do promene integriteta masne ćelije. U slučaju da mikromehurići dostignu kritičnu veličinu, oko 170 nm, oni postaju nestabilni, implodiraju i isprazne svoj sadržaj. Mikromehurići su veći u fazi dekompresije kada su ređi nego u fazi kompresije. Difuzija gasa u masnoj ćeliji je proporcionalna površini, i mikromehurići će imati povećanu količinu gasa ako se difuzija vrši prema unutra nego kada se vrši prema spolja. Oni će se povećati kod svake faze razređenja sve dok više nisu u mogućnosti da apsorbuju energiju. Kod ove kritične tačke ćelija će implodirati, oslobađajući svoj sadržaj. Vreme potrebno da se dostigne ova kritična tačka zavisi od frekvencije i intenziteta zvučnih talasa. Talasi većeg intenziteta mogu dostići kritičnu tačku posle jednog odnosno drugog ciklusa; dok će kod talasa manjeg intenziteta biti potreban veći broj ciklusa da bi se dostigla kritična veličina.

Cilj UAL-a jeste da se postigne maksimalna kavitacija i smanje termički i mikromehanički uticaji.

Implozija ćelije oslobađa njen sadržaj i takođe rezul-

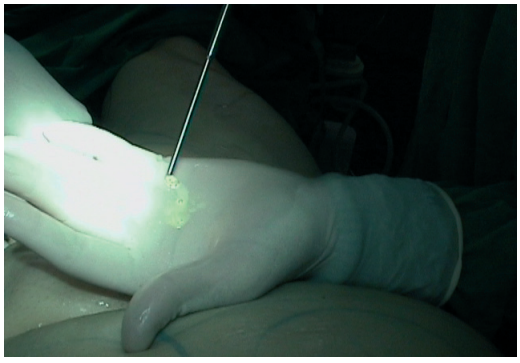

A piece of bloodless fatty tissue in the surgeon's hand and UAL probe / UZ sonda emulzifikuje komadić beskrvnog masnog tkiva na dlanu plastičnog hirurga

heat is localized and rapidly dissipates without any apparent effects on the adjacent tissue or structures. This phenomena of cavitation "collapse" occurs most easily in low-density tissue because the structural cohesion is lower and microbubble formation is more easily induced.

Once the integrity of the cell membrane is lost, the cell contents (fatty tissue, in this case) form a stable fatty emulsion that can be easily removed with low-pressure suction. The rate of fat liquefaction or cavitation is a direct function of three variables: (1) oscillatory amplitude, (2) composition of the medium, and (3) rate of the probe tip movement.

Oscillatory amplitude is the amount of cannula tip movement or excursion, measured in microns, per energy cycle. The optimal rate of excursion for maximal cavitation is 40 to 130 μm. The range of the ultrasound effect is very limited.

Lipodestruction and emulsification, "liposculpting" using ultrasound takes place within 2 mm of the cannula tip.

The composition of the medium influences the efficiency of fat emulsification. A low-density medium has less cohesion and is therefore less resistant to the deformational changes needed to induce microbubble formation. It is also less resistant to oscillatory changes at the cannula tip and therefore permits more efficient micromovement of the tip. Microbubble formation and cavitation can also occur in the intercellular spaces, a process facilitated by the use of wetting solutions. Wetting solutions are integral part of the UAL technique and serve to enhance cavitation and dissipate heat.

The rate of cannula tip movements relates directly to efficiency. Although UAL is a dynamic technique, cavitation cannot occur if insufficient time is allowed for microbubble formation. The cannula must be moved slowly through the tissues with minimal resistance as cellular disruption allows passage of the tip. From a practical standpoint, this means that body contouring surgeons accustomed to the to and fro movement of the cannula in the traditional liposuction must slow down to a rhythmic "violin bowing" movement. In essence, the rate of fat emulsification should control the rate of cannula movement. The end point of UAL is the complete or near complete loss of tissue resistance with cannula movement.

Unlike traditional liposuction, rapid cannula movement is less effective in UAL than slow, rhythmic strokes.

tuje snažnom proizvodnjom toplote. Ova toplota je lokalizovana i brzo se disipira bez prividnog efekta na okolno tkivo i strukture. Ovaj fenomen "kolapsa" kavitacije se najčešće pojavljuje u tkivu manje gustine pošto je strukturalna kohezija slabija i time lakše dolazi do formiranja mikro-mehurića.

Onog trenutka kada se izgubi integritet (celovitost) ćelijske membrane, sadržaj ćelije (u ovom slučaju masno tkivo) stvara stabilnu masnu emulziju koja se može jednostavno odstraniti isisavanjem pod niskim pritiskom. Brzina pretvaranja u tečno stanje ili kavitacija je direktno zavisna od promenljivih veličina: (1) amplituda oscilacije, (2) sastav sredine i (3) brzina pomeranja vrha sonde.

Oscilatorna amplituda je veličina pomeranja vrha sonde koja se meri u mikronima, po jednom ciklusu energije. Optimalna brzina pomeranja kako bi se postigla maksimalna kavitacija iznosi od 40 do 130 μm. Opseg efekta ultrazvuka je veoma ograničen.

Lipodestrukcija i emulzifikacija "liposculpting" pomoću ultrazvuka se vrši u opsegu od 2mm od vrha sonde.

Sastav sredine utiče na efikasnost pretvaranja masti u tečno stanje, tj. emulziju. Sredina ređe gustine je manje kohezivna pa time i manje otporna na deformacione promene potrebne da bi se proizvele mikromehuraste formacije. Ona je i manje otporna na oscilatorne promene vrha sonde pa time omogućuje mnogo efikasnije mikropokrete samog vrha. Formiranje mikromehurića (*micro bubbles*) i kavitacija (*cavitation*) je moguća i u intercelularnim prostorima, proces koji se može potpomoći upotrebom infiltracionih rastvora (*wetting solutions*). Rastvori za infiltraciju su integralni deo UAL tehnike i služe da ubrzaju kavitaciju i raspu toplotu.

Efikasnost u prvom redu zavisi od brzine pomeranja vrha sonde. I ako je UAL dinamična tehnika, neće doći do kavitacije ako vreme nije dovoljno dugo da bi se formirali mikromehurići. Sonda treba lagano da se pomera kroz tkivo sa minimalnim otporom pošto proboj ćelija omogućuje prolaz vrha. Iz praktičnog ugla gledanja, to znači da hirurzii koji su naviknuti na pomeranja sonde gore dole, kod tradicionalnih metoda liposukcije, moraju da smanje brzinu pokreta na onu kao kod pomeranja gudala violine. U osnovi brzina emulzifikacije masti treba da odredi brzinu pomeranje sonde. Krajnji ishod UAL-a je da se postigne manji otpor tkiva pri pokretima sonde.

Nasuprot tradicionalne liposukcije, kod UAL-a naglo i brzo pomeranje sonde daje slabije efekte, nego spori, ritmički pokreti.

Thermal conversion

Ultrasound energy may be converted to thermal energy when sound waves are absorbed by tissue rather than reflected or transmitted through tissue. The small amount of heat released from cavitation is insignificant. However, resistance along the cannula will cause conversion of mechanical energy, ultrasound, to heat energy and possibly create burns. Therefore torquing or bending the UAL cannula may result in skin loss along the entry site or the skin surface. Thermal injury may also occur as a result of repetitive contact between the cannula and the undersurface of the dermis.

To avoid thermal injury, always use skin protection and never torque or bend the cannula. Degree of skin damage if protector is not used depends on intensity and duration of ultrasound application.

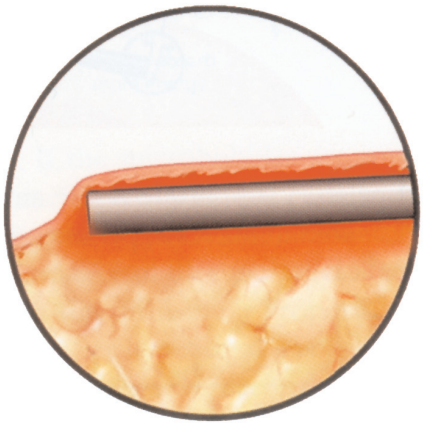

Skin Pathohistology after application of the high-intensity ultrasound energy without using skin protector / Patohistologija kože nakon primene ultrazvučne energije visokog intenziteta, bez korišćenja zaštitnika za kožu

Termička konverzija

Ultrazvučne talase tkivo može da apsorbuje i tom slučaju oni se pretvaraju u termičku energiju. Kada se ovi talasi prenose i reflektuju kroz tkivo, veoma mali njihov deo se pretvara u toplotni efekat. Količina toplote koja se stvara kod primene UAL, odnosno kod nastajanja kavitacija je neznatna. Ipak, otpor koji se stvara duž UZ sonde izaziva pretvaranje mehaničke energije ultrazvuka u toplotnu energiju, što može dovesti do termičkih oštećenja potkožnog masnog tkiva i kože. Zato uvrtanje ili savijanje UAL sonde može dovesti do gubitka kože duž mesta ulaska sonde ili na površini kože. Termička oštećenja se takođe mogu javiti kao rezultat ponavljanog kontakta sonde sa potkožnim delom derme.

Da bi se izbegle termičke povrede, neophodno je koristiti zaštitnik za kožu (skin protector) i nikada ne treba uvijati ili savijati tkivo ispred UAL sonde. Stepen oštećenja kože u slučaju ne korišćenja protektora zavisi od podešene snage uređaja i dužine aplikacije ultrazvuka.

Micromechanical disruption

The micromechanical or "jackhammer" effect is the local and direct trauma to structures adjacent to the cannula tip caused by the pressure of the ultrasound wave. Unlike cavitation, structural disruption is not related to microbubble formation. The micromechanical effect will injure any tissue adjacent to the tip and may result in damage to denser structures such as nerves as well as to fat cells. However, the micromechanical effect as a whole is thought to be minimal when the procedure is performed in a proper way.

The goal of UAL is to maximize the cavitation effect to selectively emulsify fat cells and to minimize the thermal and micromechanical effects to reduce the potential for complications. ■

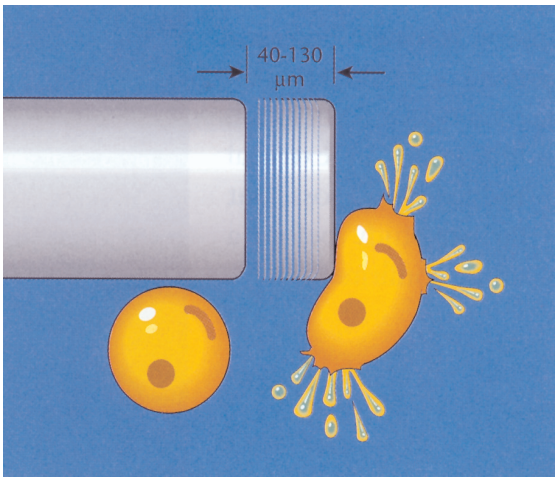

Mikromehanički proboj

Mikromehanički, ili takozvani efekat "bušilice", nastaje usled neposrednog dejstva vrha sonde koji izaziva mehanički pritisak potpomognut snažnim UZ talasima. Nasuprot kavitaciji, proboj kroz tkivo nije uslovljen pojavom mikromehurića. Mikromehanički efekat oštećuje svako tkivo u okolini vrha sonde i može prouzrokovati štetu na gušćim strukturama kao što su nervi, kao i na masnim ćelijama, a posebno ona koja imaju čvstu konzistenciju. Najveće oštećenje je u predelu vrha sonde. Međutim, mikromehanički efekat gledan u celini kod dobro vođene procedure je neznatan.

Cilj UAL-a je da poveća efekat kavitacije, što dovodi do selektivne emulzifikacije masnih ćelija, i da smanji termičke i mikromehaničke efekte da bi se smanjila mogućnost komplikacija. ■

Operative Principles and Basic Procedures

- *Morphological characteristics of subcutaneous fatty tissue depending on the anatomic area*

The most commonly suctioned area is the intermediate layer of fatty tissue. Although there are no distinct boundaries with the superficial and deep layer, intermediate layer can be defined as the middle one third of the subcutaneous fat that lies between the superficial and deep fat layers.

- *Superficial, Intermediate and Deep Layer of the fatty tissue*

Gluteal fatty tissue is often loose and flaccid because it's intermediate layer is thick. Consequently, overresection of the deep layer may result in unacceptable ptosis of the skin and fatty tissue. This happens because of the failure of the fat cutano-adipose flap to retract. The intermediate fatty layer in the back is thin. Therefore, the effects on the skin surface are insignificant. In contrast, because the intermediate layer of the thigh is thick, treatment of this layer will have insignificant effects on the skin surface.

Operativni principi i osnovne procedure

- *Morfološke karakteristike potkožnog masnog tkiva u pojedinim predelima tela.*

Najčešće tretitrani sloj masnog tkiva je intermedijalni sloj. Iako ne postoje jasne granice prema superficijalnom i dubokom sloju, intermedijalni sloj se može definisati kao srednja trećina između površinskog i dubokog sloja.

- *Superficijalni, intermedijalni i duboki sloj masnog tkiva.*

Kod glutealnog masnog tkiva intermedijalni sloj je najdeblji, i zato je ono neelastično i često opušteno. Zbog toga, preterano sečenje dubokog sloja može dovesti do ptoze kože i masnog tkiva. Ovo se događa kada debeli lipokutani režanj ne uspe da se retrahuje. Intermedijalni masni sloj na leđima je tanak tako da su kod liposukcije ovog predela efekti na koži beznačajni. Nasuprot tome intermedijalni sloj na butinama je jako debeo tako da tretman ovog predela nema značajniji efekat na površinu kože.

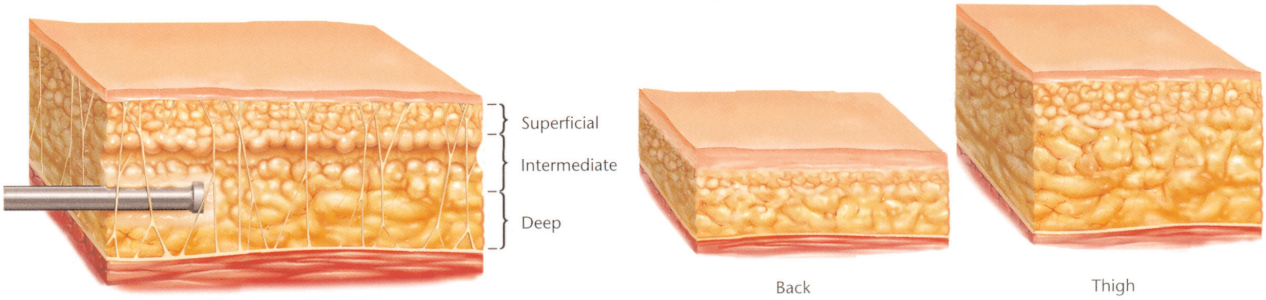

M.D., Ph.D Vesna Lackovic ***and*** ***M.D. M.S. Irena Vukovic***
Professor of Histology and Embriology, University of Belgrade Ass.

HISTOLOGICAL STRUCTURE OF THE SKIN

The skin is the outer covering of the body and the body's largest organ. It develops from the ectoderm and mesoderm and the cells of the nerve crest and the bone marrow take part in the growth of the skin; all this points to the complexity of its structural organization and function. In an adult, the surface of the skin is 1.2 to 2.3 m^2.

A very complex histological organization of the skin allows it to carry out numerous functions vital to the body. It acts as a barrier between an individual body and the external environment preventing entry of microorganisms, ultraviolet rays and loss of water from the body. Skin also protects the body from the action of harmful physical and chemical agents, it plays a role in the regulation of body temperature, in immunological processes, in the D vitamin synthesis. In addition, the skin has a secretory, sensory, respiratory and sexual function. From the psychological aspect, the skin is an important organ because there is a number of psychological disorders with dermatological symptomatology and stress-linked dermatological disorders and somatopsychological reactions.

HISTOLOŠKA ORGANIZACIJA KOŽE

Koža prekriva spoljašnju površinu tela i predstavlja najveći organ u našem organizmu. Razvija se od ektoderma i mezoderma, a u njenom razvoju učestvuju i ćelije nervnog grebena i kostne srži što ukazuje na kompleksnost njene strukturne organizacije i funkcije. Kod odrasle osobe njena površina iznosi 1,2 do 2,3 m^2.

Vrlo složena histološka organizacija kože omogućava joj da vrši niz funkcija koje su od vitalnog značaja za organizam. Ona deluje kao barijera između jedinke i okoline sprečavajući prodor mikroorganizama, ultraljubičastih zraka i gubitak vode iz organizma. Koža štiti telo od dejstva štetnih fizičkih i hemijskih agenasa, učestvuje u regulaciji telesne temperature, u imunološkim procesima, u sintezi vitamina D. Ona takođe ima sekretornu, senzornu, respiratornu i seksualnu funkciju. Sa psihološkog aspekta koža je takođe veoma važan organ jer postoje brojni psihijatrijski poremećaji sa dermatološkom simptomatologijom, zatim dermatološki poremećaji povezani sa stresom i somatopsihičke reakcije.

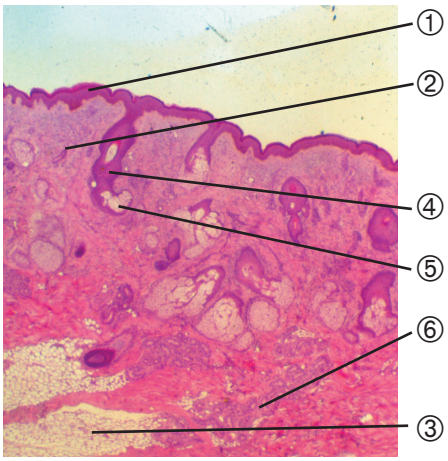

Fig 1. **Skin - thin** (H/E; small magnification). 1. epidermis, 2. dermis, 3. hypodermis, 4. hair follicle, 5. sebaceous glands, 6. sweat glands.

Slika 1. **Koža - tanka** (H/E; lupa). 1. epidermis, 2. dermis, 3. hypodermis, 4. folikul dlake, 5. lojne žlezde, 6. znojne žlezde.

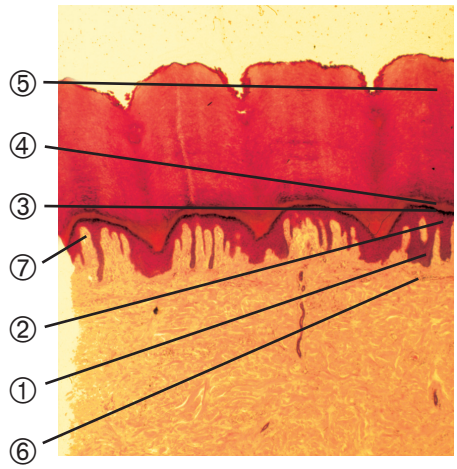

Fig. 2. **Skin of the finger - thick** (H/E; small magnification). 1. stratum basale, 2. stratum spinosum, 3. stratum granulosum, 4. stratum lucidum, 5. stratum corneum, 6. dermal papillary layer, 7. Wagner-Meisner corpuscule.

Slika 2. **Koža prsta - debela** (H/E; malo uvećanje). 1. stratum basale, 2. stratum spinosum, 3. stratum granulosum, 4. stratum lucidum, 5. stratum corneum, 6. papilarni sloj dermisa, 7. Vagner-Majsnerov (Wagner-Meissner) korpuskul.

The skin consists of three layers which differ in structure, function and embryonal development: an epidermis, dermis and hypodermis (*fig. 1*). Its structure varies with the body region it covers. Variations can be observed in the skin thickness, degree of keratinization, presence of the hair and glands, degree of pigmentation and organization of vascularization and innervation.

Epidermis

The epidermis, stratified squamous keratinizing epithelium, is an outer impermeable layer of the skin which has a protective role. The thickness of the epithelium varies with different regions of the body. It is thickest on the palms of the hands and soles of the feet (*fig. 2*). It develops from the ectoderm covering the outer surface of the embryo. The main and the most numerous cells in the epidermis are **keratinocytes**. They produce keratins, specific sulphur-rich and highly resistent proteins forming keratin filaments. In addition, they synthesize proteins of the inner horny envelope, glycophospholipid molecules of the lamellar granules, cytokines, enzymes, adhesion molecules, basal lamine proteins, molecules of the intercellular junctions as well as various inflammatory mediators.

The epidermis consists of a number of keratinocyte layers with different cytological characteristics representing successive phases of keratinization, the terminal phase being the formation of dead, horny cells of the stratum corneum. The process of cornification of the epiderims is called orthokeratinization.

In addition to keratinocytes, the epidermis is composed of diffusely distributed cells of different embryonal origins, phenotypical characteristics and functions which do not play a part in the keratinization process. This group of cells includes Langerhans cells, melanocytes and Merkel cells. A small number of limphocytes can be identified in the skin.

The epidermis lies on the basement membrane, a thin glycoprotein layer of the extracellular matrix which seperates the epidermis from the dermis. The epidermis gives rise to hair follicls, nails, sebaceous and sweat glands.

Layers of the epidermis

The keratinocytes in the epidermis are divided into four layers representing different phases of differentiation i.e. keratinization: stratum basale, stratum spinosum, stratum granulosum and stratum corneum. In some skin regions, such as the palms of the hands and the soles of the feet, the epidermis has another layer called stratum lucidum.

Koža se sastoji od tri sloja različite strukture, funkcije i embrionalnog porekla: epidermisa, dermisa i hipodermisa (*sl. 1*). Njena struktura je varijabilna u zavisnosti od regiona tela koji prekriva. Varijacije se ogledaju u debljini kože, stepenu keratinizacije, prisustvu dlaka i žlezda, stepenu pigmentacije, kao i organizaciji vaskularizacije i inervacije.

Epidermis

Epidermis, pločasti slojeviti epitel sa orožavanjem, je površinski, nepermeabilni sloj kože koji ima protektivnu ulogu. Ovaj epitel je varijabilne debljine u različitim regionima tela. Najdeblji je u koži dlanova i tabana (*sl. 2*). Razvija se od ektoderma koji pokriva spoljašnju površinu embriona. Glavne i najbrojnije ćelije epidermisa su **keratinociti**. Oni produkuju keratine, specifične, sumporom bogate i veoma rezistentne proteine koji formiraju keratinske filamente. Pored toga sintetišu proteine unutrašnje orožale ovojnice, glikofosfolipidne molekule lamelarnih granula, citokine, enzime, adhezione molekule, proteine bazalne lamine, molekule intercelularnih spojeva, kao i različite inflamatorne medijatore.

Epidermis se sastoji od nekoliko slojeva keratinocita različitih citoloških karakteristika koje predstavljaju sukcesivne faze keratinizacije čija je terminalna faza formiranje mrtvih, orožalih ćelija stratuma korneuma. Proces orožavanja epidermisa naziva se ortokeratinizacija.

Pored keratinocita u sastav epidermisa ulaze i difuzno raspoređene ćelije različitog embrionalnog porekla, fenotipskih karakteristika i funkcija koje ne učestvuju u procesu keratinizacije. U ovu grupu ćelija, spadaju Langerhansove ćelije, melanociti i Merkelove ćelije. U koži se može identifikovati i mali broj limfocita.

Epidermis naleže na bazalnu membranu, tanak glikoproteinski sloj ekstracelularnog matriksa, koji ga odvaja od dermisa. Od epidermisa nastaju dlaka, nokat, lojna i znojna žlezda.

Slojevi epidermisa

Keratinociti epidermisa su organizovani u četiri sloja koji predstavljaju različite faze diferencijacije odn. keratinizacije: stratum basale, stratum spinosum, stratum granulosum i stratum corneum. U nekim delovima kože, kao što su dlanovi i tabani u epidermisu se uočava još jedan sloj koji se naziva stratum lucidum.

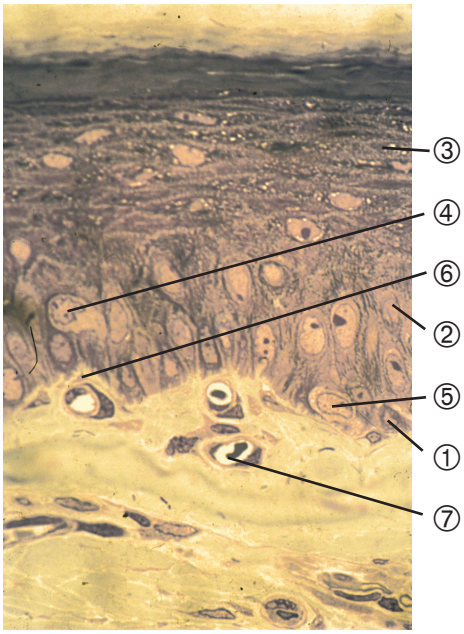

Fig. 3. **Epidermis** (semi-thin section, toluidine/blue, immersion).
1. stratum basale, 2. stratum spinosum, 3. stratum granulosum,
4. Langerhans cell, 5. melanocyte, 6. dermal papilla, 7. capillaries.

Slika 3. **Epidermis** (polutanki isečak; toluidin/azur; imerzija).
1 stratum basale, 2. stratum spinosom, 3. stratum granulosum ,
4. Langerhansova ćelija, 5. melanocit, 6. papila dermisa, 7. kapilari.

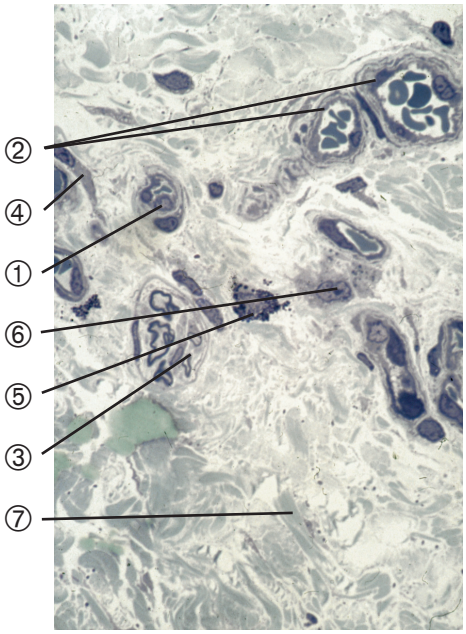

Fig. 4. **Dermis** (semi-thin section, toluidine/blue, immersion).
1. capillaries, 2. venules, 3. nerve fibers, 4. fibrocyte, 5. mastocytes,
6. macrophages, 7. collagen fibers.

Slika 4. **Dermis** (polutanki isečak; toluidin/azur; imerzija).
1. kapilari, 2. venule, 3. nervna vlakna, 4. fibrociti, 5. mastociti,
6. makrofazi, 7. kolagena vlakna.

Stratum basale (germinativum) is the deepest layer of the epidermis composed of a layer of cylindrical, basophil and synthetically active cells attached to each other by numerous desmosomes, while they are attached to the basal lamina by hemidesmosomes and intergrins (*fig. 3*). In the basal cells the synthesis of keratine filaments is initiated and as a result their quantity increases in the cells of next layers. The keratins that are synthetized on free ribosomes of this layer are K5 and K14 type.

The basal layer is characterized with intensive mitotic activities of certain stem cells. By the division, differentiation and migration of these cells into higher layers the entire epidermis is renewed. For this reason this layer is also known as the germinative layer. The stem cells constitute 10% of the cell population of this layer. These cells further divide and produce transitional cells (50%) which are subsequently subject to a limited number of divisions and produce postmitotic basal cells (40%). The postmitotic basal cells migrate upward and are terminally differentiated into horny cells. In humans the entire process of renewal of the epidermis takes about 28 days.

Stratum basale (germinativum) je najdublji sloj epidermisa sastavljen od jednog sloja cilindričnih, bazofilnih i sintetski aktivnih ćelija koje su međusobno spojene brojnim dezmozomima, dok su sa bazalnom laminom povezane hemidezmozomima i integrinima (*sl. 3*). U bazalnim ćelijama počinje sinteza keratinskih filamenata, čija količina raste u ćelijama sledećih slojeva. Keratini koji se sintetišu na slobodnim ribozomima ovog sloja su tipa K5 i K14.

Bazalni sloj se karakteriše intezivnom mitotskom aktivnošću pojedinih matičnih (stem) ćelija čijom se deobom, diferencijacijom i migracijom u više slojeve obnavlja ceo epidermis. Zbog toga se još naziva germinativni sloj. U ovom sloju stem ćelije čine 10% ćelijske populacije. Ove ćelije se dalje dele i daju tranzitne ćelije (50%), koje zatim podležu ograničenom broju deoba i produkuju postmitotske bazalne ćelije (40%). Postmitotske bazalne ćelije migriraju naviše i terminalno se diferenciraju u orožale ćelije. Kod čoveka ceo proces obnavljanja epidermisa traje oko 28 dana.

The stratum spinosum is composed of several layers of large, polyhedral cells attached by desmosomes (*fig. 3*). The points with desmosomes on the histological preparations look like spiky extensions (*spinae*); that is why this layer is called stratum spinosum. In addition to desmosomes which are the most numerous junctions of the epidermis, adherens junctions (*zonula adherens*) and gap junctions can also be found between the keratinocytes. The adherens junctions provide for mechanical stability of the epidermis, while gap junctions establish metabolic and functional integration of the keratinocytes. The number of gap junctions is higher in highly differentiated keratinocytes of the epidermis outer layers where they participate in their metabolism, growth and differentiation.

The synthesis of keratin filaments is continued in the stratum spinosum cells. In addition to the K5 and K14 keratin types, the synthesis of specific K1 and K10 type keratins, keratinization markers, is initiated in these cells. The different expressions of the keratin type are very important in diagnostics because with some diseases, such as psoriasis and keratosis, changes in keratin type expressions and emergance of new types such as K6 and K16 occur. Differentiation of oval, lamellar granules with lipid content is initiated in the top layers of this layer, although the main site of their activity is the next granular layer.

The keratinocytes of the spinosum and basal layers contain perinuclearly distributed melanosomes.

The stratum granulosum is characterized with several layers of flat polygonal keratinocytes with a centrally located euchromatic nucleus (*fig. 2, 8*). In addition to keratin filaments, the cytoplasm of these cells is filled with numerous basophil **keratohyaline granules** (hence the name of the layer) which are not enveloped with a membrane. The granules are composed of several types of protein: specific proteins that will be the matrix in the horny layer where keratin filaments are to be embedeed, proteins that bundle keratin filaments (profilagrin, a precursor of the filagrin protein) and proteins that are part of the inner horny envelope possessed by the cells of the horny layer (loricrin, involukrin). The keratohyaline granules are in the immediate vicinity of free ribosomes which produce them.

In addition to keratohyaline granules, the cell of the granular layer contain a larger number of **lamellar granules** (Odland bodies, keratinisomes) which were given this name for the lamellar appearance of their hydrophobic contents, i.e. because of successive distribution of thicker and thinner lamellas. By egzocytosis these granules discharge their glycophospholipid contents into the intercellular space around the cells of the

Stratum spinosum se sastoji od više slojeva krupnih, mnogougaonih ćelija međusobno povezanih dezmozomima (*sl. 3*). Mesta na kojima se nalaze dezmozomi na histološkim preparatima se uočavaju kao bodljikavi produžeci (*spinae*), zbog čega se ovaj sloj zove stratum spinosum. Pored dezmozoma koji su najbrojniji spojevi epidermisa, između keratinocita postoje i adherentni spojevi (*zonula adherens*), kao i komunikantni spojevi (gap junctions). Adherentnim spojevima se obezbeđuje mehanička stabilnost epidermisa, dok se komunikantnim spojevima uspostavlja metabolička i funkcionalna integracija keratinocita. Broj komunikantnih spojeva je veći u više diferentovanim keratinocitima spoljašnjih slojeva epidermisa gde učestvuju u njihovom metabolizmu, rastu i diferencijaciji.

U ćelijama spinoznog sloja nastavlja se sinteza keratinskih filamenata. Pored keratina K5 i K14, u ovim ćelijama počinju da se sintetišu i specifični keratini tipa K1 i K10 koji predstavljaju markere procesa keratinizacije. Različita ekspresija tipa keratina je veoma važna u dijagnostici, jer u nekim oboljenjima kože kao što su psorijaza i keratoze, dolazi do promene ekspresije tipa keratina i pojave novih tipova kao što su K6 i K16. U gornjim slojevima ovog sloja počinju da se diferenciraju ovalne, lamelarne granule lipidnog sadržaja , ali je glavno mesto njihove aktivnosti sledeći, granulozni sloj.

U keratinocitima spinoznog, kao i bazalnog sloja nalaze se i perinuklearno raspoređeni melanozomi.

Stratum granulosum karakteriše nekoliko slojeva spljoštenih, poligonalnih keratinocita sa centralno lociranim, euhromatskim nukleusom (*sl. 2, 8*). Citoplazma ovih ćelija je pored keratinskih filamenata ispunjena brojnim, bazofilnim **keratohijalinim granulama** (otuda naziv sloja) koje nisu okružene membranom. U sastav ovih granula ulazi više vrsta proteina: specifični proteini koji će u orožalom sloju predstavljati matriks u koji će biti potopljni keratinski filamenti, zatim proteini koji usnopljavaju keratinske filamente (profilagrin, prethodnik proteina filagrina) i najzad proteini koji ulaze u sastav unutrašnje orožale ovojnice koju poseduju ćelije orožalog sloja (loricrin, involukrin). Keratohijaline granule se nalaze u neposrednoj blizini slobodnih ribozoma koji ih sintetišu.

Pored keratohijalinih granula, ćelije granuloznog sloja sadrže i veći broj **lamelarnih granula** (Odlandova tela; keratinizomi) koje su nazvane tako zbog lamelarnog izgleda svog hidrofobnog sadržaja, odnosno naizmenično raspoređenih debljih i tanjih lamella. Ove granule egzocitozom oslobađaju svoj glikofosfolipidni sadržaj u međućelijski prostor oko ćelija granuloznog i orožalog sloja. Ova lipidna materija ima ulogu cementne supstance koja

granular and horny layer. This lipid material acts as a cementing substance sealing the space between these cells; it forms a barrier to the passage of water from the body - **the epidermal barrier**. Apart from their role in the epidermal barrier, lamellar granules are participants in the process of desquamation of horny keratinocytes. With diseases which imply loss of the content of lamellar granules desquamation of horny cells is impossible which leads to their further thickening and hyperkeratosis.

In addition to granules and keratin filaments, the cells of the granular layer contain lysosomes that will discharge their content into the cytosol and break down all organelles including the nucleus, except keratin filaments and plasmalemma, in the next phases of differentiation i.e. keratinization. At the same time a gradual thickening of the inner surface of the plasmalemma will occur, and the filagrin will multiply keratin filaments. A programmed destruction of organelles (apoptosis) occurs at the point where a granular layer transforms into the horny layer.

Transitional kerotinocytes i.e. T cells (transitional cells) with characteristics of both granular and horny cells can be identified between the granular and horny layers.

The stratum lucidum can only be differentiated in the thicker skin of the palms of the hands and the soles of the feet. This layer is composed of very flat polygonal eozinophil cells attached by desmosomes (*fig. 2, 8*). The interior surface of the plasmaleme grows thicker and the inner horny envelope comprising proteins of the keratochialine granules differentiates. The lucidum layer cells have a homogeneous appearance, as they have neither the nuclues nor the organelles, their cytoplasm being filled with tightly packed keratin filaments attached by the filigrin.

The stratum corneum is made up of 15 to 20 layers of horny, completely flat dead cells with no nucleus (*fig. 2, 3, 8*). The process of keratinization ends here. The cells, also called corneocytes, are filled with keratin filaments, and have a prominent inner envelope beneath the plasmalemma. The corneocytes are separated from each other and gradually disquamate (skin scaling), while during that time the epithelium is renewed by the division and differentiation of stem cells of the basal layer. This layer ensures mechanical protection of the skin and is a barrier against the loss of water from the organism and the entry of soluble matters from the external envorinment. This epidermal barrier is formed by two sections: cellular (keratinocytes filled with keratins) and extracellular (glycophospholipids around the horny cells). Although precursors of the inner horny envelope have been synthesized in the previous layers of the epidermis, it is possible to identify the envelope with certainty only in the cells of the horny layer. This thick protein layer situated beneath

vrši zaptivanje prostora između ovih ćelija, odnosno formira barijeru za prolaz vode iz organizma - **epidermisnu barijeru**. Pored uloge u epidermisnoj barijeri lamelarne granule učestvuju u deskvamaciji orožalih keratinocita. U oboljenjima kod kojih dolazi do gubitka sadržaja lamelarnih granula dolazi do nemogućnosti deskvamacije orožalih ćelija što dovodi do njihovg nagomilavanja i hiperkeratoze.

Ćelije granuloznog sloja pored granula i keratinskih filamenata sadrže i lizozome koji će u sledećim fazama diferencijacije, odnosno keratinizacije osloboditi svoj sadržaj u citosol i razgraditi sve organele uključujući i jedro, osim keratinskih filamenata i plazmaleme. Istovremeno dolazi do postepenog zadebljanja unutrašnje površine plazmaleme, a filagrin umnožava keratinske filamente. Programirana destrukcija organela (apoptoza) dešava se na prelazu granuloznog u orožali sloj.

Između granuloznog i orožalog sloja mogu se identifikovati i prelazini keratinociti , odnosno T ćelije (engl. transitional cells) koje imaju karakteristike i granuloznih i orožalih ćelija.

Stratum lucidum se diferencirana samo u debljoj koži dlanova i tabana, a sastoji se od izrazito spljoštenih, mnogougaonih, eozinofilnih ćelija povezanih dezmozomima (*sl. 2, 8*). Unutrašnja površina plazmaleme je zadebljana i diferencira se unutrašnja orožala ovojnica u čiji sastav ulaze proteini keratohijalinih granula. Ćelije lucidnog sloja imaju homogen izgled, jer ne poseduju ni jedro ni organele, već im je citoplazma ispunjena samo gusto zbijenim keratinskim filamentima povezanih filagrinom.

Stratum corneum se sastoji od 15-20 slojeva orožalih, sasvim pljosnatih, mrtvih ćelija bez jedra (*sl. 2, 3, 8*). Ovde je proces keratinizacije završen. Ćelije, koje se još zovi korneociti, ispunjene su keratinskim filamentima, a ispod plazmaleme imaju izraženu unutrašnju ovojnicu. Korneociti bivaju međusobno odvojeni i postepeno deskvamiraju (perutanje kože), dok se za to vreme deobama i diferencijacijama matičnih ćelija bazalnog sloja obnavlja epitel. Ovaj sloj obezbeđuje mehaničku zaštitu kože i barijeru od gubitka vode iz organizma, kao i ulaska rastvorljivih materija iz spoljašnje sredine. Ovu epidermisnu barijeru formiraju dva odeljka: celularni (keratinociti ispunjeni keratinima) i ekstracelularni (glikofosfolipidi oko orožalih ćelija). Iako se prekurzori unutrašnje orožale ovojnice sintetišu u prethodnim slojevima epidermisa, samo u ćelijama orožalog sloja ovojnica se može definitivno identifikovati. Ovaj gusti proteinski sloj koji se nalazi ispod plazmaleme korneocita sastoji se od više vrsta proteina, kao što su involukrin, lorikrin, keratolinin

the corneocyte plasmalemma is composed of several types of proteins, such as involucrin, loricrin, keratolinin, etc. that are attached to each other and that form an insoluble and highly resistant envelope. In addition to the formation of a horny envelope, a change in the expression of keratin filaments is an indicator of terminal differentiation. 80% of the corneocyte volume is made of keratin with a high molecular mass (upto 60 kDa) while the remaining portion consists of the matrix with keratin filaments.

Nonkeratinocytes of the epidermis

In addition to keratinocytes, the epidermis includes nonkeratinocytes, specific cell entities of various embryonic origin, phenotypical characteristics and function, which do not take part in the process of keratinization. These are melanocytes, Langerhans cells, Merkel cells and T lymphocytes. They are also known as immigrant cells.

Melanocytes are the cells of dendritic shape with extensions; their oval bodies are situated in the basal layers while their extensions are situated between keratinocytes of the basal and spinosum layers. These cells synthesize the pigment melanin which dyes the skin. They are formed by the differentiation of the neural crest cells from where they migrate into the embryonic epidermis and are incorporated into it around the 50th day of the embryonic development. Their nucleus is oval and frequently with indentations, and the cytoplasm contains numerous pigment granules (melanosomes). However, with routine stained histological preparations, the melanocyte cytoplasm remains bright (*fig. 3*). The melanocytes synthesize melanin pigment and accumulate it into melanosomes. In the melanin synthesis process the key role is performed by the enzyme tyrosinase which converts tyrosine into 3.4-dehydroxyphenilalanin (DOPA) which is transformed into melanin after a series of reactions.

The keratinocytes take the melanosomes over by the phagocytosis of the tips of melanocyte cytoplasmatic processes and distribute them either individually or in groups above or close to the nucleus protecting the DNK hromosome from mutagen damage by ultraviolet radiation. After the internalization, the melanosomes fuse with lysosomes which gradually dissolve them. As a result, there is no melanin in the stratum corneum. A group of keratinocytes which is supplied with melanin by a melanocyte is called the epidermal-melanin unit. Around 36 basal and suprabasal keratinocytes are functionally connected (melanosome transfer) to one melanocyte in this unit. Melanocytes do not proliferate in the skin except when the skin is specifically stumulated by untraviolet rays.

i drugi koji su međusobno povezani i formiraju nerastvorljivu i veoma otpornu ovojnicu. Pored stvaranja orožale ovojnice indikator terminalne diferencijacije je i promena u ekspresiji keratinskih filamenata. 80 % zapremine korneocita sačinjavaju keratini velike molekulske mase (do 60 kDa, dok ostali deo čini matriks sa keratinskim filamentima.

Nekeratinociti epidermisa

Pored keratinocita u sastav epidermisa ulaze i nekeratinociti, specifični ćelijski entiteti različitog embrionalnog porekla, fenotipskih karakteristika i funkcije, koji ne učestvuju u procesu keratinizacije. Tu spadaju melanociti, Langerhansove ćelije, Merkelove ćelije i T limfociti. Zovu se još imigrantske ćelije .

Melanociti su ćelije razgranatog, dentritskog oblika čija se ovalna tela nalaze u bazalnom sloju, a produžeci između keratinocita bazalnog i spinoznog sloja. Ove ćelije sintetišu pigment melanin koji daje boju koži. Nastaju diferencijacijom ćelija nervnog grebena odakle migriraju u embrionalni epidermis i inkorporiraju se u njega oko 50-og dana embrionalnog razvoja. Nukleus im je ovalan, često sa indentacijama, a u citoplazmi se nalaze brojne pigmentne granule (melanozomi). Međutim, na rutinski obojenim histološkim preparatima, citoplazma melanocita ostaje neobojena, svetla (*sl. 3*). Melanociti sintetišu pigment melanin i akumuliraju ga u melanozomima. U procesu sinteze melanina ključno dejstvo ima enzim tirozinaza koji pretvara tirozin u 3,4-dihidroksifenilalanin (DOPA) koji se posle niza reakcija transformiše u melanin.

Keratinociti preuzimaju melanozome fagocitozom vrhova citoplazmatskih produžetaka melanocita i raspoređuju ih pojedinačno ili u grupama iznad i pored jedra štiteći DNK hromozoma od mutagenog oštećenja ultraljubučastim zračenjem. Posle internalizacije melanozomi se spajaju sa lizozomima koji ih postepeno razlažu. Zbog toga u stratum korneumu nema melanina. Grupa keratinocita koju melaninom snadbeva jedan melanocit naziva se epidermisno-melaninska jedinica. Oko 36 bazalnih i suprabazalnih keratinocita funkcionalno je povezan (transfer melanozoma) sa jednim melanocitom u ovoj jedinici. Melanociti ne proliferišu u koži osim kada je ona specifično stimulisana ultravioletnim zracima.

The Merkel cells are distributed in a discontinuous manner between the basal keratinocytes in well innervated skin regions, such as the finger tips, lips and outer covering of hair. They are attached to keratinocytes by desmosomes, while their basal section is in contact with the nerve fibre. These polarized cells have an oval shape, clear cytoplasm and lobed nucleus. The apical domain accummulates organelles, and the basal domain accummulates small granules similar to synaptic vesicles of the neurone. Beneath the Merkel cell there are free nerve endings which form a kind of chemical synapse with it. The Merkel cells are slow mechanoreceptors which receive tactile stumuli. Since peptide hormones and biogenic amines have been identified in the granules of these cells, these cells are classified as diffuse neuroendocrine system of the body (DNES).

The Langerhans cells are antigen - presenting cells secreting cytokines, adhesion molecules and other mediators, and they participate in the defense of the body against antigens from the external environment. Save in the epidermis, where they are located in the spinosum layer forming a horizontal suprabasal network, they are also found in other epithelia and lymphopoetic organs. As all other Langerhans cells they have precursors in the bone marrow (CD34+). At an early stage in the embryonic development they migrate from the bone marrow into the circulation and then they are carried by blood vessels of the dermis to the epidermis and constitute 2-8% of its total cell population. From the epidermis they can migrate into the dermis and can further be transferred by lymphatic vessels to local lymph nodes.

The role of the Langerhans cells in the immune response is concerned with the antigen presenting function including recognition, internalization, processing and presentation of the antigen to T-lymphocytes which induce immune response. They are included in the responses of rejection of transplanted skin grafts, as it has been shown that there is no rejection of skin grafts deficient in the Langerhans cells or that rejection occurs much later. It is believed that the Langerhans cells from the graft migrate to lymphatic nodes and stimulate T-lymphocytes of the recepient to initiate a rejection response (central sensibilization).

The Langerhans cells are difficult to identify by routine stained sections so that in their identification other methods are used such as impregnation by silver, immunohistochemical staining to S-100 and CD1a, CD4, CD45 proteins, HLA-DR antigens and ultrastructural examinations. They have branch type form, they are not attached to the adjacent cells and are capable of migration. They have a nucleus of an irregular shape and in the cytoplasm

Merkelove ćelije su diskontinuirano raspoređene između bazalnih keratinocita u delovima kože koji su dobro inervisani, kao što su to vrhovi prstiju, usne i spoljašnji omotač dlake. Sa keratinocitima su povezani dezmozomima, dok su svojim bazalnim odeljkom u dodiru sa nervnim vlaknom. Ove polarizovane ćelije su ovalnog oblika, svetle citoplazme i režnjevitog jedra. U apikalnom odeljku akumulirane su organele, a u bazalnom sitne granule slične sinaptičkim vezikulama neurona. Ispod Merkelove ćelije nalazi se slobodni nervni završetak gradeći sa njom neku vrstu hemijske sinapse. Merkelove ćelije su sporo reagujući mehanoreceptori koji primaju taktilne nadražaje. Međutim, pošto su u granulama ovih ćelija identifikovani peptidni hormoni i biogeni amini, ove ćelije se svrstavaju u difuzni neuroendokrini sistem organizma (DNES).

Langerhansove ćelije su antigen prezentujuće ćelije koje luče citokine, adhezione molekule i druge medijatore, a imaju ulogu u odbrani organizma od antigena spoljašnje sredine. Osim u epidermisu, gde su locirane u spinoznom sloju formijući horizontalnu suprabazalnu mrežu, nalaze se i u drugim epitelima i limfopoetskim organima. Kao i sve druge Langerhansove ćelije i one imaju prekurzore u kostnoj srži (CD34+). Vrlo rano u embrionalnom razvoju migriraju iz kostne srži u cirkulaciju, a zatim krvnim sudovima dermisa dospevaju u epidermis, gde čine 2-8% njegove ukupne ćelijske populacije. Iz epidermisa mogu da migriraju u dermis i dalje limfnim sudovima do lokalnih limfnih čvorova.

Uloga Langerhansovih ćelija u imunskom odgovoru odnosi se na antigen prezentujuću funkciju koja uključuje raspoznavanje, internalizaciju, procesiranje i prezentiranje antigena T limfocitima koji indukuju imunski odgovor. Uključene su u reakcije odbacivanja presađenih kalema kože, jer je pokazano da se kalemi kože koja je deficitarna sa Langerhansovim ćelijama ne odbacuju ili odbacuju znatno kasnije. Smatra se da Langerhansove ćelije iz kalema migriraju u limfne čvorove i stimulišu T limfocite primaoca na počinjanje reakcije odbacivanja (centralna senzibilizacija).

Langerhansove ćelije se teško se mogu identifikovati na rutinski obojenim isečcima, pa se za njihovu identifikaciju koriste metode kao što su impregnacija srebrom, imunohistohemijska bojenja na S-100 i CD1a, CD4, CD45 proteine, HLA-DR antigene i ultrastukturna istraživanja. Razgranatog su oblika, nisu spojene sa susednim ćelija i imaju sposobnost migracije. Poseduju jedro nepravilnog oblika, a u citoplazmi se nalaze karakteristične

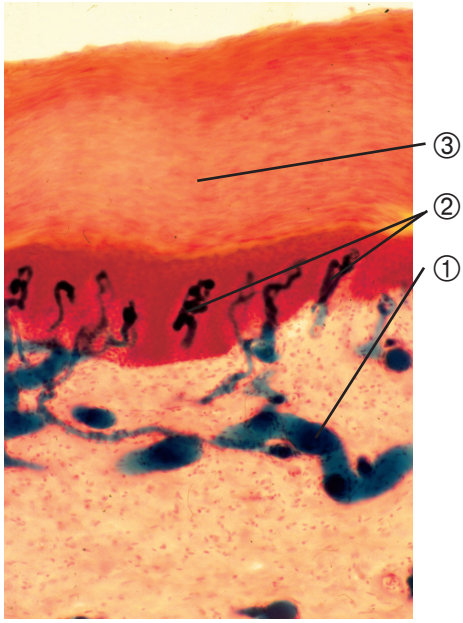

Fig. 5. **Skin vascularization** (injected dye, high magnification). 1. papillary plexus, 2. capillary loops in the dermis papillae, 3. epidermis.

Slika 5. **Vaskularizacija kože** (ubrizgana boja; veliko uvećanje). 1. papilarni pleksus, 2. kapilarne petlje u papilama dermisa, 3. epidermis.

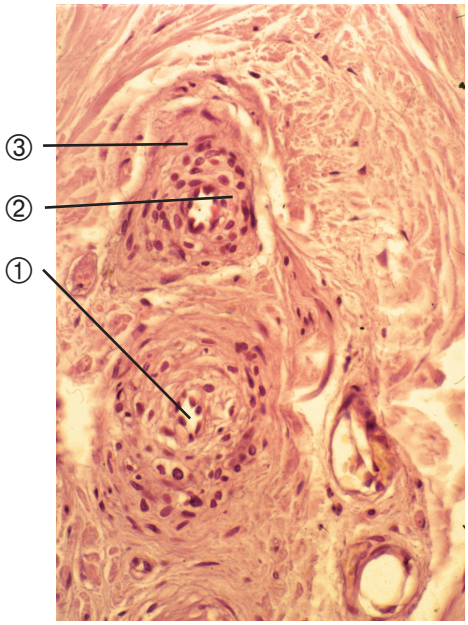

Fig. 6. **Arteriovenous anastomosis (glomus) - dermis** (H/E, high magnification). 1. arteriovenous canal, 2. smooth muscle cells, 3. capsula of the glomus.

Slika 6. **Arteriovenska anastomoza (glomus) - dermis** (H/E; veliko uvećanje). 1. arteriovenski kanal, 2. glatke mišićne ćelije, 3. kapsula glomusa.

there are typical racket-shaped Birbek granules acting as a marker for identification of these cells (*fig. 3)*. They contain neither keratin filaments nor melanosomes.

With inflammatory skin diseases the number of the Langerhans cells increases and it is also possible to identify small nodular aggregates of these cells in the epidermis. With certain diseases such as psoriasis, sarcoidosis, contact dermatitis, the number of these cells decreases. After ultraviolet radiation and ionizing radiation there is a reduction in their number, antigen presenting function and secretion of cytokines causing decline in immunity.

Very small amounts of **T-lymphocytes** are found in the epidermis of health skin (0,5 to 1% of the epidermis cells). The largest number of these cells is of the CD8+ type. It is believed that these cells have been previously senzibilized in the lymph nodes from where they were circulated into the skin.

Intercellular area of the epidermis

This domain of the epidermis is represented by narrow area between kerotinocytes at points where they do not possess desmosomes. From the basement mem-

Birbekove granule reketastog oblika koje služe kao marker za identifikaciju ovih ćelija (*sl. 3*). Ne poseduju keratinske filamente niti melanozome.

U zapaljenjskim oboljenjima kože broj Langerhansovih ćelija raste, a mogu se identifikovati i mali nodularni agregati ovih ćelija u epidermisu. U određenim oboljenjima kao što su psoriaza, sarkoidoza, kontaktni dermatitis broj ovih ćelija se redukuje. Posle ultravioletnog i jonizujućeg zračenja smanjuje se njihov broj, antigen prezentujuća funkcija i lučenje citokina, što dovodi do smanjenja imuniteta.

T limfociti se nalaze u epidermisu zdrave kože u bazalnom sloju u vrlo malom broju (0,5 do 1% ćelija epidermisa). Najveći broj ovih ćelija pripada tipu CD8+. Smatra se da su to ćelije prethodno senzibilisane u limfnim čvorovima odakle su cirkulacijom dospele u kožu.

Intercelularni prostor epidermisa

Ovaj odeljak epidermisa predstavljen je uskim prostorima između keratinocita na mestima gde oni ne poseduju dezmozome. U delu od bazalne membrane do

brane to the horny layer this area is filled with glycoproteins and is an extension of the intercellular area of the dermis. The content of the intercellular area allows for a rapid passage of various molecules and remedial substances from blood vessels of the dermis to the avascular epidermis and vice versa, the passage of kerotinocyte products to the dermis (e.g. vitamin D). The basement membrane acts as a filter barrier limiting the passage of molecules with the mass greater than 40.000.

The intercellular space reaching to the top surface of the granular layer is filled with the content of hydrophilic nature, while the horny layer that is the epidermic barrier contains the content of lipid nature. The characteristics of the intercellular matrix, basement membrane and epidermal barrier determine permeability of the epidermis which is critical to the application of medicaments and cosmetics.

Dermo-epidermal junction

The epidermis is tightly attached to the dermis by a dermo-epidermal junction which is also known as the basement membrane zone. The main function of this zone is to attach the epidermis and dermis, to support the epidermis, to act as a barrier, and to play a role in the embrynic development of the epidermis. This zone is made of a layer formed by the basal domains of keratinocytes with hemidesmosomes, the basement membrane with its sublayers and anchoring fibrils of the papillary dermis. **The hemidesmosomes** are a kind of adhesion junctions having a plaque composed of specific proteins and attached to keratin filaments.**The basement membrane** is a thin continuous layer of the extracellular matrix dividing the epidermis from the dermis (*fig. 3, 8*). This 50-100 nm thick layer is composed of laminin, fibronectin, bullous pemphigoid antigen, IV type collagen and KF-1 antigen as well as other proteins. The basal cells of the epidermis are attached to the basement membrane structures by the hemidesmosomes and integrin receptors.

The ultrastructural examinations have shown that the basement membrane is composed of 3 distinct regions: a) lamina lucida, a clear layer predominantly composed of laminin and bullous pemphigoid antigen, b) lamina densa, a dark layer containing mainly IV collagen and c) a fibroreticular layer binding the basal lamina to the dermis connective tissue and containing thick anchoring fibrils, fibronectin, interstitial collagen (I, III, V and VI), extensions of lamina densa and epidermolisis bullosa antigen. The lamina lucida and lamina densa are called basal lamina, while the fibroreticular layer is called reticular lamina.

The anchoring fibrils are composed of type VII collagen and connect the basement membrane with the dermis.

orožalog sloja prostor je ispunjen glikoproteinima i predstavlja nastavak intercelularnog prostora dermisa. Sadržaj intercelularnog prostora omogućava brz prolaz različitih molekula i lekovitih substanci iz krvnih sudova dermisa u avaskularni epidermis i suprotno, prelazak produkata keratinocita u dermis (npr. vitamin D). Bazalna membrana deluje kao filter barijera ograničavajući prolaz molekula čija je masa veća od 40.000.

Međućelijski prostor koji dopire do gornje površine granuloznog sloja ispunjen je sadržajem hidrofilne prirode, dok je u orožalom sloju, odnosno epidermisnoj barijeri, sadržaj lipidne prirode. Osobine intercelularnog matriksa, bazalne membrane i epidermisne barijere određuju propustljivost epidermisa, što je značajno za aplikaciju lekova i kozmetičkih sredstava.

Dermo-epidermni spoj

Epidermis je čvsrto povezan sa dermisom dermoepidermnim spojem koji se još zove zona bazalne membrane. Glavna funkcija ove zone je međusobno povezivanje epidermisa i dermisa, potpora epidermisu, barijerna uloga, uloga u embrionalnom razvoju epidermisa. Ovu zonu čini sloj koga formiraju bazalni odeljci keratinocita sa hemidezmozomima, bazalna membrana sa svojom podslojevima i usidravajući fibrili papilarnog dermisa. **Hemidezmozomi** predstavljaju vrstu adherentnog spoja čilji je plak sastavljen od specifičnih proteina i povezan je sa keratinskim filamentima. **Bazalna membrana** je tanak, kontinuirani sloj ekstracelularnog matriksa koji razdvaja epidermis od dermisa (*sl. 3, 8*). U sastav ovog sloja, debljine 50-100 nm, ulaze laminin, fibronektin, bulozni pemfigoidni antigen, kolagen tipa IV i KF-1 antigen, kao i drugi proteini. Bazalne ćelije epidermisa povezane su sa strukturama bazalne membrane hemidezmozomima i integrinskim receptorima.

Ultrastrukturna istraživanja su pokazala da bazalnu membranu čine 3 različita regiona: a) lamina lucida, svetli sloj sastavljen pretežno od laminina i buloznog pemfigoidnog antigena, b) lamina denza, tamni sloj koji uglavnom sadrži kolagen IV i c) fibroretikularni sloj koji povezuje bazalnu laminu sa vezivnim tkivom dermisa i sadrži debele usidravajuće fibrile, fibronektin, intersticijalne kolagene (I,III, V i VI) , ekstenzije lamine denze i epidermolisis buloza antigen. Lamina lucida i lamina denza zovu se bazalna lamina, a fibroretikularni sloj retikularna lamina.

Usidravajući fibrili se sastoje od kolagena VII i povezuju bazalnu membranu sa dermisom.

Dermis

The dermis is a connective tissue lying immediately beneath the epidermis from which it is divided by the basement membrane (*fig. 1, 2, 3, 6*). It supports the epidermis, supplies it and interacts with it in embryogenesis, morphogenesis and wound healing processes. The dermis is composed of connective fibres (collagen, elastic and reticular), the ground substance (proteoglycans) and cells (fibroblasts, mastocytes, macrophages). The collagen is the dominant (the most widely distributed) protein in this layer.

The dermis is made of two layers: the outer papillary layer (stratum papillare) and the inner considerably thicker layer (stratum reticulare).

Papillary layer is made of a loose connective tissue which extends into the epidermis in the form of numerous papillae. The papillae have a rich network of blood vessels supplying the epidermis (*fig. 5*). Any skin with thicker epidermis has more and longer papillae. The connective tissue of papilae in certain regions of the skin contains various sensitive receptors (*fig. 8*).

Dermis

Dermis predstavlja vezivno tkivo koje se nalazi neposredno ispod epidermisa od koga ga razdvaja bazalna membrana (*sl. 1,2,3,6*). On daje potporu epidermisu, ishranjuje ga i interreaguje sa njim u procesima embriogeneze, morfogeneze i zarastanja rana. Sastoji se od vezivnih vlakana (kolagena, elastična i retikularna), osnovne supstance (proteoglikani) i ćelija (fibroblasti, mastociti, makrofazi). Kolagen je najzastupljeniji protein u ovom sloju.

Dermis sačinjavaju ga dva sloja: površni, papilarni sloj (stratum papillare) i unutrašnji, znatno deblji sloj (stratum reticulare).

Osnovu **papilarnog sloja** dermisa čini rastresito vezivno tkivo koje se u vidu brojnih papila uvlači u epidermis. Papile sadrže bogatu mrežu krvnih sudova kojima ishranjuju epidermis (*sl. 5*). Kod kože sa debelim epidermisom papile su brojnije i duže. Vezivno tkivo papila u određenim regionima kože sadrži i različite senzitivne receptore (*sl. 8*).

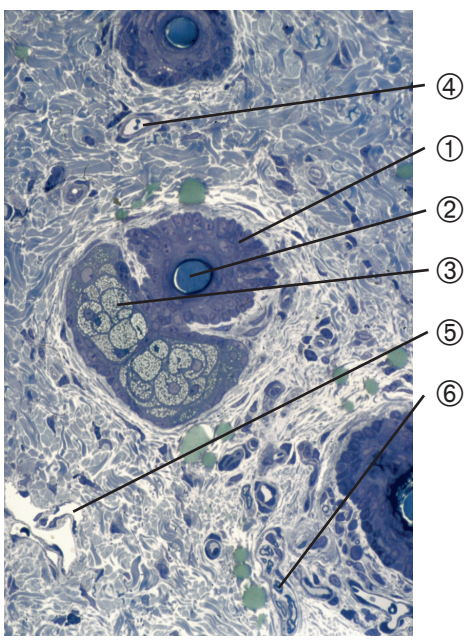

Fig. 7. **Dermis** (semi-thin section, toluidine/blue, medium magnification). 1. hair follicle, 2. hair shaft, 3. sebaceous gland, 4. blood capillaries, 5. lymphatic capillaries with valves, 6. nerve fibers.

Slika 7. **Dermis** (polutanki isečak; toluidin/azur; srednje uvećanje) 1. folikul dlake, 2. stabljika dlake, 3. lojna žlezda, 4. krvni kapilari, 5. limfni kapilari sa zaliscima, 6. nervna vlakna.

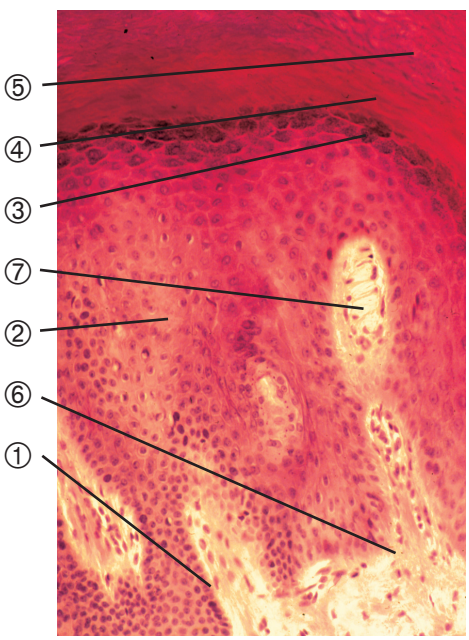

Fig. 8. **Dermal papillary layer - skin of the finger** (H/E; high magnification). 1. stratum basale, 2. stratum spinosum, 3. stratum granulosum, 4. stratum lucidum, 5. stratum corneum, 6. basement membrane, 7. Wagner-Meissner corpuscule.

Slika 8. **Papilarni sloj dermisa-koža prsta** (H/E; veliko uvećanje). 1. stratum basale, 2. stratum spinosum, 3. stratum granulosum, 4. stratum lucidum, 5. stratum corneum, 6. bazalna membrana, 7. Vagner-Majsnerov (Wagner-Meissner) korpuskul.

Reticular layer contains a dense network of horizontally distributed thick collagen fibres which provide the skin with mechanical stability, a network of elastic fibres, nerve fibres as well as the ground substance which, besides its other functions, affects the skin turgor due to its hydrophily.

The greatest number of the dermis components, fibres and the ground substance are synthetized by **fibroblasts**, cells with abundant cytoplasm and numerous processes with well-developed biosynthetic and secretory organelles (*fig. 4*). The composition and viscosity of the dermis ground substance and permeability are regulated by perivascularily distributed **mastocytes** through their autocrine secretion (*fig. 4*). The cytoplasm of mastocytes is filled with numerous large granules containing glycosaminoglycanes, histamine, hondroitin sulphate, neutral protease, beta glycuronidasa and eosinophil factors of anaphilaxis. Massive discharge of the contents of granules occurs in allergic responses. Phagocytosis of microorganisms, damaged or dead cells, and other various particles in the dermis is carried out by **macrophages**, a heterogeneous population of mononuclear-phagocyte system cells (*fig. 4*). Their cytoplasm contains a large number of primary and secondary lysosomes.

In addition to acting as the support to the epidermis, the dermis influences the process of its differentiation. The dermis structures determine whether the epidermis will differentiate into a thin type (the skin of the body trunk, head and limbs) or a thick skin type (the palms and soles).

Hypodermis

The hypodermis is the deepest skin layer. It is composed of fatty tissue lobules (*panniculus adiposus*) divided by connective fibrous septas containing nerve fibers and blood and lymph vessels (*fig. 1, 9*). The hypodermis is a thermal insulator and a store of energy. Besides, its structures serve to attach the skin to the muscles and bones and allow its mobility. Inflammatory changes affecting the hypodermis can be manifested as septal panniculitis, where the inflammatory process is primarily localized in the fibrous trabeculae (e.g. *eritema nodosum*) or lobular panniculitis which is primarily located in fatty lobules. These changes may be accompanied with vasculitis which may attack both small and large blood vessels of the hypodermis. The main function of the subcutaneous fatty tissues is to store energy. Apart from this, this tissue plays an important part in the regulation of heat, mechanical protection and allows movement of the skin relative to the structure it covers. In the face, neck and sculp region there is a layer of skeletal muscle cells (*panniculus carnosus*) close to the hypodermis fatty tissue.

Retikularni sloj dermisa sadrži gustu mržu horizontalno raspoređenih, debelih kolagenih vlakana koja koži obezbeđuju mehaničku stabilnost, mrežu elastičnih vlakana, nervna vlakna, kao i osnovnu supstancu, koja pored drugih funkcija, utiče na turgor kože, zahvaljujući svojoj hidrofilnosti.

Najveći deo komponenti dermisa, vlakna i osnovnu supstancu sintetišu **fibroblasti**, ćelije obilne citoplazme i brojnih produžetaka sa dobro razvijenim biosintetsko-sekretornim organelama (*sl. 4*). Sastav i viskozitet osnovne supstance dermisa, kao i permeabilitet regulišu perivaskularno raspoređeni **mastociti** svojom autokrinom sekrecijom (*sl. 4*). Citoplazma mastocita ispunjena je brojnim, krupnim granulama u kojima se nalaze glikozaminoglikani, histamin, hondroitin sulfat, neutralne proteaze, beta glukuronidaza i eozinofilni faktor anafilakse. Masivno oslobađanje sadržaja granula dešava se u alergijskim reakcijama. Fagocitozu mikroorganizama, oštećenih ili mrtvih ćelija, kao i raznovrsnih čestica u dermisu obavljaju **makrofazi**, heterogena populacija ćelija mononukleusno-fagocitnog sistema (*sl. 4*). Njihova citoplazma sadrži brojne primarne i sekundarne lizozome.

Pored toga što predstavlja potporu epidermisu, dermis utiče na proces njegove diferencijacije. Strukture dermisa određuju da li će se epidermis diferencirati u tanak tip (koža trupa, glave i ekstremiteta) ili debeo tip kože (dlanovi i tabani).

Hipodermis

Hipodermis je najdublji sloj kože. Sastoji se od lobulusa masnog tkiva (*panniculus adiposus*) odeljenih vezivnim, fibroznim septama u kojima se nalaze nervna vlakna i krvni i limfni sudovi (*sl. 1, 9*). Hipodermis je toplotni izolator i depo energetskog materijala. Pored toga njegove strukture povezuju kožu sa mišićima i kostima i omogućavaju njenu pokretljivost. Inflamatorne promene koje obuhvataju hipodermis mogu se manifestovati septalnim panikulitisom, u kome je inflamatorni proces primarno lokalizovan u fibroznim trabekulama (npr. *eritema nodosum*) ili lobularnim panikulitisom koji je primarno smešten u masnim lobulusima. Ove promene mogu biti udružene sa vaskulitom, koji može zahvatiti male i velike krvne sudove hipodermisa. Osnovna funkcija potkožnog masnog tkiva je skladištenje energije. Pored toga ovo tkivo ima važnu ulogu u toplotnoj regulaciji, mehaničkoj zaštiti i omogućavanju pomeranje kože u odnosu na strukture koje pokriva. U predelu lica vrata i poglavine uz masno tkivo hipodermisa nalazi se i sloj skeletnih mišićnih ćelija (*panniculus carnosus*).

The hypodermis contains plexus of blood vessels (*rete cutaneum*) extending horizontally to the border with the dermis (*fig. 5*). It can also contain extensions of the skin structure such as deeper part of hair follicles and apocrine and eccrine sabaceous glands (*fig. 1, 9*).

The thickness of the hypodermis is variable. Distribution of fatty cells differs with the sex. In females they are predominantly found in the buttocks and thighs, while in males they are mainly situated in the abdomen area.

Vascularization of the skin

Blood enters into the skin through muscle arteries which in the hypodermis form a plexus (called **rete cutaneum**) parallel to the skin surface. Extensions from this deeper localized plexus give rise to a surface plexsus, **rete subpapillare**, which supplies the epidermis (*fig. 5*). The subpapillary plexus extends into capillaries making loops in the papillae. Each dermal papilla has one capillary loop. The blood runs through horizontal venous plexuses which are parallel to the arterial plexuses.

For the vascularization of the skin it is critical that numerous **arteriovenous anastomoses** formed between terminal arterioles and muscular venules are present. These are short coiled blood vessels with a thick vascular wall composed of smooth richly innervated muscle cells. In the skin of the finger tips arteriovenous anastomoses organizations may be more complex when they form special ball-type bodies, the so-called **glomera** (*fig. 6*).

The smooth muscle cells of arteriovenous anastomoses are innervated with vasomotor nerves regulating the flow of blood through them and in this way they are included in the thermoregulating process. The contraction of smooth muscle cells closes the anastomosis lumen at its front end and directs the blood into the capillary loop, while the relaxation opens the lumen and releases the blood direct into the venule, bypassing the capillary network. Besides neural control, skin vascularization is influenced by cataholamines, angiotensin II, acethylcholin, histamine, bradykinin, serotonin, substance P, prostaglandins, oxygen and pH.

Skin vasularization can be compromised by a number of causes and can be manifested as urtikaria, ischaemia, vasospasm, inflammation (vasculitis), venous stasis as well as alterations in the development of blood vessels of the skin (haemangioma).

Lymphatic vessels of the skin

The lymphatic system of the skin is very well-developed and is made of two large plexuses situated in the dermal

Hipodermis sadrži pleksus krvnih sudova (*rete cutaneum*), koji se horizontalno pruža na granici sa dermisom (*sl. 5*). Takođe može sadržati i produžetke strukture kože kao što su dublji delovi folikula dlake i apokrine i ekkrine lojne žlezde (*sl. 1, 9*).

Hipodermis je veoma varijabilne debljine. Masne ćelije su različito raspoređene u zavisnosti od pola. Kod žena su predominantno raspoređene u sedalnom predelu i butinama, dok su kod muškarca u najvećoj meri smeštene u abdominalnom predelu.

Vaskularizacija kože

U kožu krv dolazi mišićnim arterijama koje u hipodermisu formiraju pleksus paralelan površini kože, koji se zove **rete cutaneum**. Od ovog, dublje lokalizovanog pleksusa, grananjem nastaje površinski splet, **rete subpapillare**, koji ishranjuje epidermis (*sl. 5*). Od subpapilarnog pleksusa izdvajaju se kapilari koji prave petlje u papilama. Svaka dermalna papila poseduje jednu kapilarnu petlju. Venska krv teče horizontalnim venskim pleksusima koji su paralelni arterijskim pleksusima.

Značajno za vaskularizaciju kože je postojanje brojnih **arteriovenskih anastomoza** formiranih između terminalnih arteriola i mišićnih venula. To su kratki izuvijani krvni sudovi koji imaju debeo vaskularni zid sastavljen od glatkih mišićnih ćelija bogato inervisanih. U koži vrhova prstiju arteriovenske anastomoze mogu biti kompleksnije organizacije kada formiraju specijalna loptasta telašca, tzv. **glomuse** (*sl. 6*).

Glatke mišićne ćelije arteriovenskih anastomoza inervisane su vazomotornim nervima koji regulišu protok krvi kroz njih, čime su uključeni u procese termoregulacije. Kontrakcija glatkih mišićnih ćelija zatvara lumen anastomoze na njenom početku i usmerava krv u kapilarnu petlju, dok njihova relaksacija otvara lumen i pušta krv direktno u venulu, zaobilazeći kapilarnu mrežu. Pored nervne kontrole, na vaskularizaciju kože utiču kateholamini, angiotenzin II, acetilholin, histamin, bradikinin, serotonin, substanca P, prostaglandini, kiseonik i pH.

Vaskularizacija kože može biti kompromitovana brojnim uzrocima i manifestovati se urtikarijom, ishemijom, vazospazmom, inflamacijom (vasculitis), venskom stazom, kao i alteracijama razvoja krvnih sudova kože (hemangiomi).

Limfni sudovi kože

Limfni sistem kože je vrlo dobro razvijen i čine ga dva velika pleksusa, koji se nalaze u dermalnom veziv-

connective tissue: superficial and deep lymphatic plexus.

The superficial lymphatic plexus, which begins with lymph capillaries immediately beneath the basal lamina of the epidermis, is situated in the papillary layer of the dermis. This superficial plexus occupies two thirds of the dermis exterior. Vertical lymphatic vessels run from the superficial lymphatic plexus to the **deep lymphatic plexus** which is situated in the bottom third of the dermis, the localization of which corresponds to the deep arterial plexus. Lymph is drained from these plexuses into the lymphatic vessels of the hypodermis and from there to regional lymph glands.

Unlike the lymphatic vessels of the deep plexus which have a large number of valves, the lymphatic vessels of the superficial plexus generally do not have valves (*fig. 7*). Although the entire lymphatic system is well-developed, certain regions, such as the fingers, palms, soles and scrotum contain a larger number of lymphatic vessels. Apart from this variation in number, regional differences are also observed in the shape of lymphatic vessels. In regions where the skin is thicker and more firm, lymphatic vessels have a uniform shape, while in regions where the skin is thin their shape is variable due to different pressure exerted by the structures of interstice on the walls of lymphatic vessels.

Skin innervation

The skin has somatic and autonomic innervation. Somatic nerves are sensitive and they convey information about pain, temperature, touch and pressure from the receptor to relevant centers. In the skin they are found either as free or incapsullated nerve endings such as Vater-Pacini and Wagner-Meissner corpuscles which are receptors for pressure and touch (*fig. 8*).

Free nerve endings, receptors for pain, abound in the skin. They are especially abundant in the dermal papillae, immediately beneath the basement membrane through which they pass to the epidermis, where they can be found as free nerve endings or are attached to the Merkel cells. It has been found that a single nerve ending with ramifications can contact approximately up to 50 Merkel cells.

Incapsullated nerve endings show variable regional distribution. They can only be found in the hairfree skin, such as the skin of the sole of the foot, the palm of the hand and glans penis.

Autonomic nerve fibres of the skin are of the SY nature. They follow somatic nerves and innervate sweat glands, smooth muscle cells of blood vessels and m. arrector pili.

nom tkivu: superficijalni i duboki limfni pleksus.

Superficijalni limfni pleksus koji počinje limfnim kapilarima neposredno ispod bazalne lamine epidermisa, nalazi se u papilarnom sloju dermisa. Ovaj površinski pleksus zauzima spoljašnje dve trećine dermisa. Od njega polaze vertikalni limfni sudovi do **dubokog limfnog pleksusa** koji je smešten u donjoj trećini dermisa i čija lokalizacija odgovara dubokom arterijskom pleksusu. Od ovih pleksusa limfa se drenira u limfne sudove hipodermisa, a odatle u regionalne limfne žlezde.

Limfni sudovi superficijalnog pleksusa uglavnom ne poseduju zaliske, za razliku od limfnih sudova dubokog limfnog pleksusa kod kojih je broj zalistaka veliki (*sl. 7*). Iako je ceo limfni sistem kože dobro razvijen, pojedini regioni, kao što su prsti, dlanovi, tabani i skrotum sadrže veći broj limfnih sudova. Pored varijacija u broju, regionalne razlike postoje i u obliku limfnih sudova. U delovima gde je koža deblja i čvršća, limfni sudovi su uniformnog obika, dok su u delovima tanke kože vrlo varijabilnog oblika, što se objašnjava razlikama u pritisku struktura intersticijuma na zidove limfnih sudova.

Inervacija kože

Koža ima somatsku i autonomu inervaciju. Somatski nervi su senzitivni i prenose informacije od receptora za bol, temperaturu, dodir i pritisak u odgovarajuće centre. U koži se nalaze kako u vidu slobodnih tako i inkapsuliranih nervnih završetaka kao što su Fater-Pačinijev (Vater-Pacini) i Vagner-Majsnerov (Wagner-Meissner) korpuskul koji predstavljaju receptore za pritisak i dodir (*sl. 8*).

Slobodni nervni završeci, receptori za bol, najzastupljeniji su u koži. Naročito su brojni u papilama dermisa, neposredno ispod bazalne membrane kroz koju prolaze u epidermis, gde se nalaze takođe kao slobodni nervni završeci ili se povezuju sa Merkelovim ćelijama. Ustanovljeno je da jedan razgranat nervni zavšetak može da kontaktira sa do 50 Merkelovih ćelija.

Inkapsulirani nervni završeci pokazuju varijabilnu regionalnu distribuciju. Oni se nalaze samo u koži koja ne poseduje dlake, kao što je koža tabana, dlanova i glans penisa.

Autonomna nervna vlakna kože su SY prirode. Oni prate somatske nerve i inervišu znojne žlezde, glatke mišićne ćelije krvnih sudova i m. arrector pili.

Skin appendages

Differentiation of the epidermis gives rise to the hair, nails, sebaceous glands, apocrine and eccrine glands and mammary gland. The hair follicle, sebaceous gland and arrector pili muscle, which have not been derived from the epidermis, make a pylosebaceous unit of the skin.

A hair is a horny threadlike outgrowth of the epidermis coming out in various thickness and sizes (*fig. 1, 7*). It is found on the entire skin surface, except on the palms and soles, mammary gland areola and part of genital organs. The hair develops from the hair follicle which is a tubular invagination of the epidermis into the dermis and hypodermis covered on the outside with a thin layer of the dermis. The hair follicle is richly innervated and very sensitive to tactile stimuli. The hair follicle lumen, a follicle channel containing the hair, has an opening on the surface of the epidermis and it is relatively easy for microorganism to enter through this opening inside the follicle and cause an inflammatory process. These follicles are the places where acnes develop.

Sebaceous glands are associated with hair follicles in the dermis of the entire skin except on the palms and soles. They are made of acini on the outside of which there is a layer on the basement membrane of flat, basophilic stem cells which undergo differentiation giving rise to sebocytes filled with lipid vacuoles which move forward to the acinus centre (*fig. 1, 7*). At the end of the differentiation process the sebocytes burst and their component parts produce secretion (sebum) composed of triglycerides, free fatty acids, wax esters, holesterol and its esters. This type of secretion is called holocrine secretion. As sebaceous glands have no outlet chanel, sebum flows into the follicle duct and runs along the hair to the opening through which it disperses over the skin surface.

In humans, **sweat glands** are classified into two types: apocrine and eccrine glands. The **apocrine** (epitrichial) glands are branching tubuloalveolar glands situated in the dermis of axilla, perineum and mammary gland areola. Secretory portions, tubuloalveole, consist of a row of cylindrical cells which contain secretory granules (*fig. 9*) in their apical portion. In secretion apical portions of the cell separate together with the secretory granules; this is an apocrine secretion type. The outlet duct of these glands is lined with a two-layered cuboidal epithelium and opens into the hair follicle in the way similar to the sebaceous gland. These glands do not play any part in thermoregulation processes. The secretion of these glands is viscous and coloured and contains proteins, carbohydrates, ammonia, lipid and substances acting like pheromones.

Derivati epidermisa

Diferencijacijom epidermisa nastaje dlaka, nokat, lojna žlezda, apokrine i ekkrine znojne žlezde i mlečna žlezda. Folikul dlake, lojna zlezda i mišić podizač dlake, koji nije derivat epidermisa, čine pilosebacealnu jedinicu kože.

Dlake su orožale, končaste tvorevine epidermisa različite debljine i veličine (*sl. 1, 7*). Nalaze se po celoj površini kože, osim na dlanovima i tabanima, areoli mlečne žlezde i delovima genitalnih organa. Dlaka raste iz folikula dlake koji predstavlja cevasti uvrat epidermisa u dermis i hipodermis, spolja obložen tankim slojem dermisa. Folikul dlake je bogato inervisan i veoma osetljiv na taktilne nadražaje. Lumen folikula dlake, folikulski kanal u kome se nalazi dlaka, otvoren je na površini epidermisa i kroz taj otvor mikroorganizmi relativno lako mogu da prodru u unutrašnjost folikula i da izazovu zapaljenjski proces. Ovi folikuli su mesta nastajanja akni.

Lojne žlezde se nalaze uz folikul dlake u dermisu cele kože osim na dlanovima i tabanima. Sastoje se od acinusa na čijoj se spoljašnjoj strani na bazalnoj membrani nalazi sloj pljosnatih, bazofilnih, matičnih ćelija čijom diferencijacijom nastaju sebociti ispunjeni lipidnim vakuolama koji se sve više pomeraju ka središtu acinusa (*sl. 1, 7*). Na kraju procesa diferencijacije sebociti prskaju, a od njegovih sastavnih delova nastaje sekret (sebum, loj) koji se sastoji od triglicerida, slobodnih masnih kiselina, estara voska, holesterola i njegovih estara. Ovakav način sekrecije naziva se holokrina sekrecija. Sebum se, pošto lojne žlezde nemaju izvodne kanale, uliva u folikuski kanal i teče uz dlaku do otvora kroz koji se razliva po površini kože.

Znojne žlezde se kod čoveka eksprimiraju u dva tipa: apokrine i ekkrine žlezde. **Apokrine** (epitrihijalne) žlezde su razgranate tubuloalveolarne žlezde koje se kod čoveka nalaze u dermisu aksila, perineuma i areole mlečne žlezde. Sekretorni delovi, tubuloalveole, sastoje se do jednog reda cilindričnih ćelija koje u svojim apikalnim delovima sadrže sekretorne granule (*sl. 9*). Pri sekreciji se odvajaju i apikalni delovi ćelije zajedno sa sekretornim granulama što predstavlja apokrini tip sekrecije. Izvodni kanal ovih žlezda obložen je dvoslojnim kockastim epitelom, a otvara se u folikul dlake slično lojnoj žlezdi. Ove žlezde ne učestvuju u procesima termoregulacije. Sekret ovih žlezdi, viskozan i obojen, sadrži proteine, ugljene hidrate, amonijak, lipide i supstance koje deluju kao feromoni. **Ekkrine** (atrihijalne) žlezde

The **eccrine** (atrichial) glands are simple, coiled glands distributed all over the skin (there are a few millions of these cells) except around the skin of the lips, glans penis, clitoris and labia minora. They are made of secretory portion and an outlet duct running through the epidermis and opening onto the skin surface (*fig. 1, 9*). The secretory portion of the gland is situated in the deep dermis and hypodermis. It has the shape of a coiled tubule and a wall made of three cell types - basal (stem), dark and clear cells. The eccrine glands play a part in the regulation of body temperature. When stimulated by heat or physical strain these cells can secrete litres of sweat, hypotonic water solution containing Na, Cl, K, lactat, urea and a very small amount of protein in an hour. Emotional factors also play a part in secretion of sweat.

Mammary glands (*gll. mammariae*), derivatives of the epidermis, are generally modified apocrine sweat glands. Their structure depends on the sex, age and physiological condition of the body i.e. the phases of menstrual cycle, pregnancy period and lactation. In women they become fully developed after puberty, while in men they remain undeveloped. The mammary glands are made of parenchyma and stroma. The parenchyma is made of 15 to 20 lobules and each lobule is made of a larger number of lobules. The parenchymatous cells are lactocytes. The mammary gland stoma is made of septas dividing lobules and fatty tissue surrounding them.

Nail (*unguis*) is a flat, platelike, transparent structure on the dorsal surface of the terminal finger phalange. The epidermal portion of the nail is made of nail plate composed of numerous layers of horny kerotinocytes

su proste, izuvijane žlezde koje su raspoređene po celoj koži (ima ih nekoliko miliona) osim kože usana, glans penisa, clitorisa i labia minora. Sastoje se od sekretornog dela i izvodnog kanala koji se pruža kroz epidermis i otvara na površini kože (*sl. 1, 9*). Sekretorni deo žlezde nalazi se u dubokom dermisu i hipodermisu. U obliku je sklupčanog tubula čiji zid čine tri vrste ćelija, bazalne (matične), tamne i svetle ćelije. Ekkrine žlezde imaju ulogu u regulaciji telesne temperature. Stimulisane toplotom ili fizičkim naporom za jedan sat mogu izlučiti nekoliko litara znoja, hipotoničnog vodenog rastvora koji sadrži Na, Cl, K, laktat, ureu i vrlo malu količinu proteina. Na sekreciju znoja mogu da utiču i emocionalni faktori.

Mlečne žlezde (*gll. mammariae*), takođe derivati epidermisa, u suštini su modifikovane apokrine znojne žlezde. Njihova građa zavisi od pola, starosti i fiziološkog stanja organizma, odnosno faza mestruacionog ciklusa, perioda trudnoće i laktacije. Maksimum razvoja dostižu kod žena posle puberteta, dok kod muškarca ostaju nerazvijene. Mlečne žlezde se sastoje od parenhima i strome. Parenhim se sastoji od 15-25 lobusa, a svaki lobus iz većeg broja lobulusa. Parenhimske ćelije su laktociti. Stromu lečne žlečne čine septe koje odvajaju lobuse i masno tkivo koje ih okružuje.

Nokat (*unguis*) je pločasta, providna tvorevina na dorzalnoj površini terminalne falange prsta. Epidermisni deo nokta se sastoji od nokatne ploče koju čine brojni slojevi orožalih keratinocita i podloge, lektuklusa na ko-

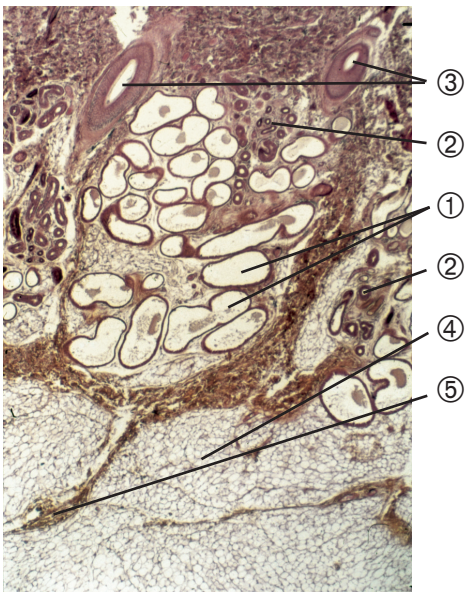

Fig. 9. **Dermis and hypodermis** (H/E; low magnification).
1. apocrine sweat glands, 2. eccrine sweat glands, 3. hair follicles, 4. fatty tissue, 5. connective tissue septa.

Slika 9. **Dermis i hipodermis** (H/E; malo uvećanje).
1. apokrine znojne žlezde, 2. ekkrine znojne žlezde, 3. dlake, 4. masno tkivo, 5. vezivne pregrade.

and the base, lectucluse on which they rest and to which the nail plate is connected. The lectulus is made of basal and spinosum layer of the epidermis and dermis connected to the periostium of the phalangx. The promixal part and lateral edges of the nail are covered by a thin epidermal coat called *eponychium*. The nail dermis is connected to the periostium of the phalangx.

me leži i za koji je vezana nokatna ploča. Lektulus se sastoji od bazalnog i spinoznog sloja epidermisa i dermisa vezanog za periost falange. Proksimalni deo i lateralne ivice nokta prekrivene su tankom epidermisnom navlakom koja se zove *eponychium*. Dermis nokta je vezan za periost falangi.

Regional differences in the skin structure

The largest portion of the skin is protected by clothing and is not specifically exposed to traumas. Due to this fact it does not show any specific organization. So, the skin on the back, abdomen, thighs and arms has a thin epidermis, a small number of hair follicles and a variable number of eccrine glands. The skin of the sole has a thick epidermis containing another layer, *stratum lucidum*, as well as 25 to 30 layers of cells in the *stratum corneum*. The skin in this region does not have hair follicles but it has a large number of eccrine glands and their ducts. The skin on the sculp is characterized by densely distributed hair with sebaceous glands. The skin of the finger has a more complex organization as it plays both a protective and tactile role. As with the sole skin, the epidermis of the finger skin has a *stratum lucidum* and a very thick *stratum corneum*, while the dermis has numerous Wagner - Meissner and Vater - Pacini corpuscles, arteriovenous anastomosis and a large numbre of eccrine sweat glands. The skin of the axil and groins has a thin epidermis, a plenty of active apocrine glands and a large number of hair follicles and eccrine sweat glands.

Regionalne razlike u strukturi kože

Najveći deo kože je zaštićen odećom i nije posebno izložen traumama, zbog čega ne pokazuje posebnu specifičnost organizacije. Tako koža leđa, abdomena, butina i ruku, poseduje tanak epidermis, mali broj folikula dlaka i varijabilni broj ekkrinih žlezda. Koža stopala poseduje debeo epidermis u kome je prisutan još jedan sloj, *stratum lucidum*, kao i 25-30 slojeva ćelija u *stratum corneumu*. Koža u ovom predelu ne poseduje folikule dlake i ima veliki broj ekkrinih žlezda i njihovih kanala. Koža poglavine se karakteriše gusto raspoređenim dlakama sa lojnim žlezdama. Koža prsta pokazuje složeniju organizaciju, jer ima i zaštitnu i taktilnu ulogu. Kao i u koži stopala u epidermisu kože prsta prisutan je *stratum lucidum* i veoma debeo orožali sloj, dok dermis poseduje brojne Vagner Majsnerove i Fater Pačinijeve korpuskule, arteriovenske anastomoze, kao i veliki broj ekkrinih znojnih žlezda. Koža aksila i prepona ima tanak epidermis, obilje vrlo aktivnih apokrinih žlezda, veliki broj folikula dlaka i ekkrinih znojnih žlezda.

ANATOMY OF THE SUBCUTANEOUS FATTY TISSUE

Introduction concerning the anatomy

Knowledge of the anatomy of the subcutaneous fatty tissue and the superficial fascial system (SFS), due to contribution of many authors, makes possible a more rational and effective procedure, thus increasing the indications for liposuction.

This knowledge makes it possible to explain subdermal superficial liposculpture from an anatomical point of view and to differentiate the procedures depending on the area of the body they are applied to.

The cellulitis is mattress-like appearance of the skin. The hypertrophy of the adipose cells inside the lobules of the areolar fat stretches the vertical fibrous septae of the SFS. Since these are not extensible, it causes dimples and irregularities on the skin surface. The ideal treatment for this condition should decompress the areolar adipose lobules.

Practical anatomy

In some areas of the body the fat layer may be very thick. This thick layer stretches the skin beacause of its volume and weight. If you want to obtain good skin retraction, the massive UAL and SAL treatment of all subcutaneous fat layers is necessary. Gasperoni named this procedure MALL (Masive All Layer Liposuction)*.

We call it MALT (Masive All Layer Treatment) since we use a combination of UAL, SAL and external ultrasound.

In the abdomen and internal surface of the upper third of the thighs MALT allowes an incredible retraction of the skin, drastically reducing the indications of abdominoplasty and inner-thigh dermolipectomy.

Anatomical basis and Surgical technique

Anatomy of Subcutaneous Fat and the Superficial Fascial System

Adipose tissue is incased in a fibrous framework called the superficial fascial system (SFS) that separates the fat into areolar (superficial) and lamelar (deep) adi-

* "*Rationale of Subdermal Superficial Liposuction Related to the Anatomy of Subcutaneous Fat and the Superficial Fascial System*", *C. Gasperoni, M.D. and Marzia Salgarello, M.D. Aesth. Plast. Surg. 19:13-20 (1995).*

ANATOMIJA POTKOŽNOG MASNOG TKIVA

Uvod sa stanovišta anatomije

Poznavanje anatomije potkožnog masnog tkiva i površinskog fascijalnog sistema (SFS), usled doprinosa mnogobrojnih autora, omogućava racionalniji i efikasniji postupak i povećava primenu liposukcije.

Pomoću ovog saznanja moguće je pojasniti potkožnu površinsku liposkulpturu sa stanovišta anatomije, i diferencirati procedure u zavisnosti od dela tela na koji se primenjuju.

Celulitis je "mrežasti" izgled kože. Hipertrofija adipoznih ćelija u lobularnom delu areolarnog masnog tkiva izdužuje vertikalne fibrozne membrane SFS-a. Pošto ove nisu elastične, pojavljuju se rupice i neravnine na površini kože. Idealni tretman ovog stanja bi trebalo da oslobodi pritisak areolarnih adipoznih lobula.

Primenjena anatomija

U nekim delovima tela masni sloj može biti veoma debeo. Ovaj debeo sloj rasteže kožu, zbog svoje zapremine i težine. Ako želite da dobijete dobro skupljanje kože, neophodan je masivan UAL i SAL tretman potkožnih masnih slojeva. Gasperoni je tu proceduru nazvao MALL (Masivna liposukcija svih slojeva)*.

Mi, s druge strane, to zovemo MALT (Masivni tretman svih slojeva), pošto koristimo kombinaciju UAL-a, SAL-a i spoljašnjeg ultrazvuka.

U abdomenu i unutrašnjoj površini gornje trećine butina, MALT omogućava neverovatno skupljanje kože, drastično smanjujući potrebu za abdominoplastijom i dermolipektomijom unutrašenjeg dela butine.

Anatomske osnove i hirurška tehnika

Anatomija potkožnog masnog sloja i površinskog fascijalnog sistema

Potkožno masno tkivo pregradjeno je fibroznim pregradnim sistemom tzv. površnim tj. superficijalnim fascijalnim sistemom (SFS) koji ga razdvaja u areolarni (povr-

* "*Suština potkožne površinske liposukcije u odnosu na anatomiju potkožnog masnog sloja i površinskoj fascijalnog sistema*", *C. Gasperoni, M.D. i Marzia Salgarello, M.D. Aesth. Plast. Surg. 19:13-20 (1995).*

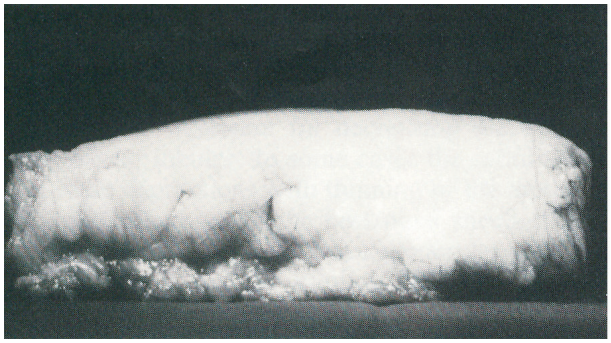

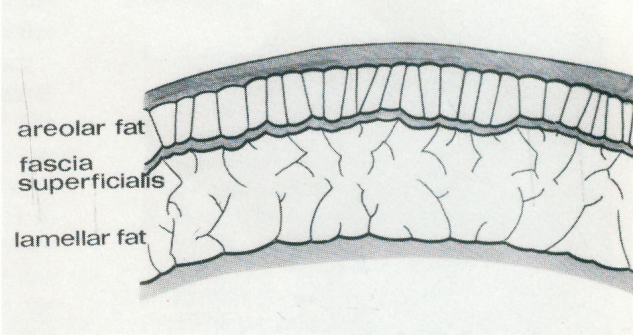
areolar fat
fascia superficialis
lamellar fat

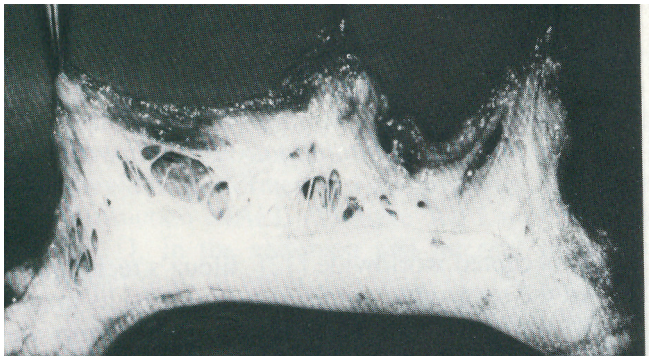

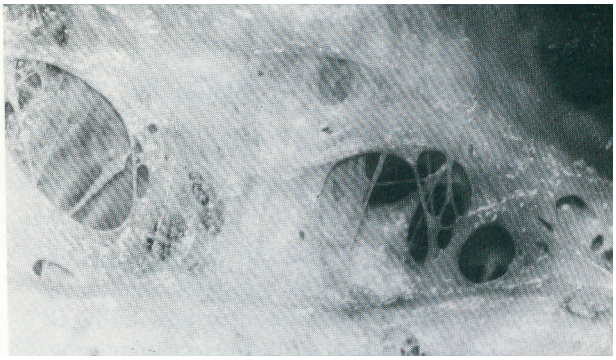

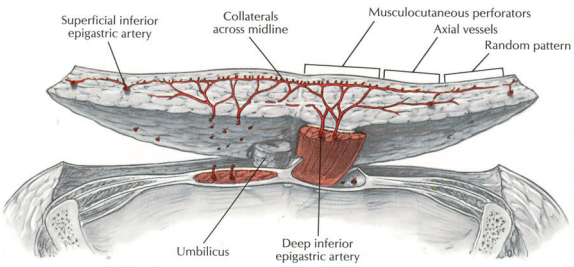
Superficial inferior epigastric artery
Collaterals across midline
Musculocutaneous perforators
Axial vessels
Random pattern
Umbilicus
Deep inferior epigastric artery

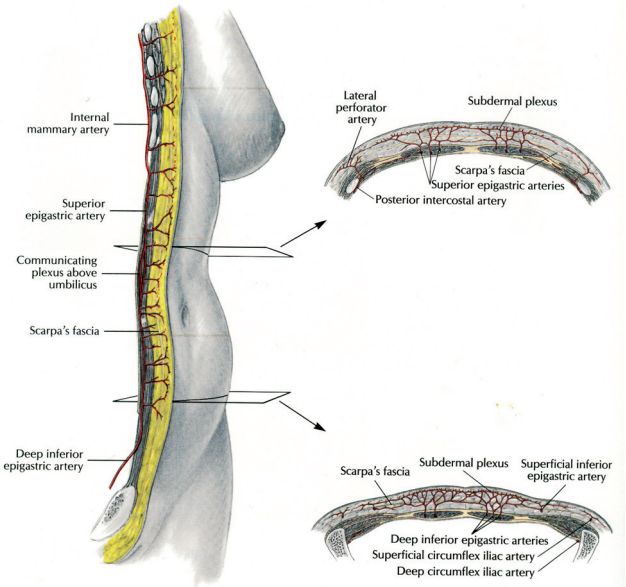
Internal mammary artery
Superior epigastric artery
Communicating plexus above umbilicus
Scarpa's fascia
Deep inferior epigastric artery
Lateral perforator artery
Subdermal plexus
Scarpa's fascia
Superior epigastric arteries
Posterior intercostal artery
Scarpa's fascia
Subdermal plexus
Superficial inferior epigastric artery
Deep inferior epigastric arteries
Superficial circumflex iliac artery
Deep circumflex iliac artery

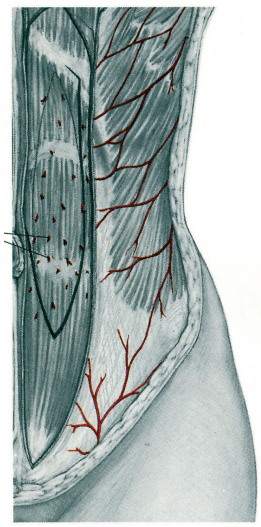

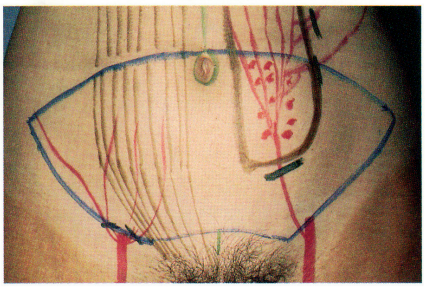

pose tissue.

The areolar tissue is superficial, situated between the dermis and the fascia superficialis, extends over almost entire body. It consists of small fat lobules tightly packed between fibrous septae of the SFS oriented perpendicular to the skin.

The areolar fat is presented in vertically oriented compartments. Accumulation of large quantity of fat in the lobule fatty cells leads to increase in thickness of this layer of subcutaneous fatty tissue. We call subdermal fat the superficial part of the areolar fat that is situated immediately under the dermis.

The lammelar tissue is deep and situated between the fascia superficialis and muscle fascia. It consists of large fat lobules loosely packed within widely spaced vertical and oblique fibrous septae.

Therefore, it is looser and softer than the areolar fat. It is present only in certain body areas: the upper and lower abdomen (especially in the median and inferior regions corresponding to te projection of the *rectus abdominis* muscle), flanks, trochanteric region, internal surface of the upper third of the thigh, knees, and posterior surface of he upper arm.

The lamellar layer increases in thicknes much more than the areolar layer. In obese patients it may be eight to ten times thicker than in normal weight people , while the areolar tisssue may just double in thickness. Therefore its "flattening" is responsible for localized adipose deformities. The disposition of the SFS varies among body areas and from person to person, and also depends on the degree of adiposity.

The superficial fascia in certain regions consists of several layers. In obese patients, occurance of pseudo-fascial substance is noted between the superficial and deep fascia, especially in the abdominal region. A much larger number of septae is also noted in the lamelar tissue.

In conclusion, the SFS anatomy distinguishes body areas with both areolar and lamellar adipose layers and other regions whose subcutaneous tissue exibits only the areollar layer (anterior surface of the thigh, internal external and posterior surfaces of the medial and lower third of the thigh, calves, ankles and anterior external surfaces of the arm).

Moreover, the SFS shows several variations between the sexes, implying some differences in male and female contours and adiposities. In some body areas the SFS adheres tightly to underlying muscle fascia or periosteum thus forming zones of adherence.

šni) i lamelarni (duboki) sloj.

Areolarni, tj. površni sloj, smešten je između dermisa i površne fascije (*fascia superficialis*) i proteže se skoro preko čitavog tela. Sastoji se od malih lobula sastavljenih od masnih ćelija tesno upakovanih između fibroznih septa SFS a postavljanih perpendikularno u odnosu na kožu.

Areolarni masni sloj predstavljen je vertikalno postavljenim kompartmentima. Akumulacija veće količine masti u vakuolama masnih ćelija lobula dovešće do porasta debljine ovog sloja potkožnog masnog tkiva. Subdermalni sloj masnog tkiva predstavlja superficijalni deo areolarnog masnog tkiva smešten neposredno ispod dermisa.

Duboki ili tzv. lamelarni sloj potkožnog masnog tkiva nalazi se između fascije superficijalis i mišićne fascije. Sastoji se od krupnih lobula masnog tkiva "labavo" upakovanih izmedju široko postavljenih vertikalnih i kosih pregrada (*septae*).

Lamelarno tkivo je rastresitije i mekše nego areolarno masno tkivo. Može se naći samo u određenim anatomskim regijama kao što su gornji i donji abdomen (najizraženiji u srednjoj i kaudalnoj projekciji m. *rectusa abdominisa*), slabine, trohanterična regija, unutrašnja strana gornje trećine butina, kolena i zadnja strana nadlaktice (*r. antebrachi posterior*).

Lamelarni sloj se može nadebljati mnogo više nego areolarni sloj. Kod jako adipoznih osoba lamelarni sloj može biti osam do deset puta deblji nego u osoba sa normalnom telesnom težinom. Areolarno masno tkivo može samo da udvostruči svoj volumen. Zato je splašnjavanje (gubljnje volumena) ovog sloja tkiva odgovorno za lokalizovane adipozne deformacije. Dispozicija SFS-a se razlikuje kod raznih anatomskih regija tela i od osobe do osobe, a zavisi i od stepena adipoziteta.

Površna fascija se u određenim anatomskim regijama tela sastoji od nekoliko slojeva. U jako adipoznih osoba, posebno u predelu abdomena, zapažena je i pojava pseudo-fascijalnih tvorevina između površne i duboke fascije. Takođe je zapažen i znatno izraženiji broj septi u lamelarnom tkivu.

Superficijalni fascijalni sistem (SFS) razdvaja anatomske regije tela koje sadrže i areolarno i lamelarno masno tkivo od onih gde se supkutano masno tkivo isključivo prezentuje sa areolarnim slojem. Regije koje poseduju samo areolarno masno tkivo su prednja strana natkolenice, unutrašnja, spoljašnja i zadnja strana srednje i donje trećine butina, listovi, članci, prednja i spoljašnja strana nadlaktica.

Štaviše, SFS ispoljava određene varijacije između polova, po pitanju izvesnih razlika u muškim i ženskim konturama i adipozitetu. U određenim delovima SFS je čvrsto spojen za donjom muskulatorum fascije ili periosteumom, formirajući na taj način spojne zone.

Superficial Contouring

Superficial contouring should only be performed after the surgeon has become experienced with UAL / SAL procedures. Irregularities within the superficial layer of the fatty tissue can cause permanent contour deformity. Superficial layer of the fatty tissue must not be treated without concrete indications such as cellulite, irregularities, scars and in the special areas, for example in the gluteal area.

Superficijalno konturiranje
(oblikovanje površinskog sloja potkožnog masnog tkiva)

Superficijalno konturiranje preoporučuje se samo iskusnim UAL / SAL plastičnim hirurzima. Nepravilnost u površnom sloju masnog tkiva mogu dovesti do permanentnog deformiteta oblika i površina tretirane regije. Superficijalni sloj masnog tkiva treba tretirati samo u indikovanim slučajevima kao sto su celulitis, nepravilnosti površine, ožiljci i posebne regije kao sto je na primer glutealna regija.

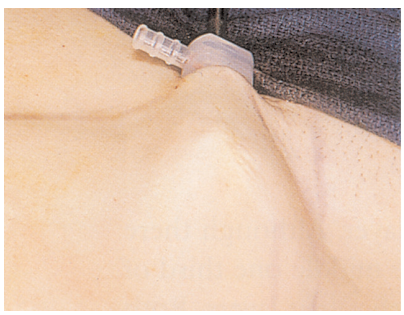

Erythema

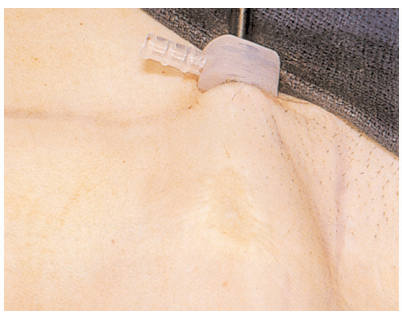

Blistering

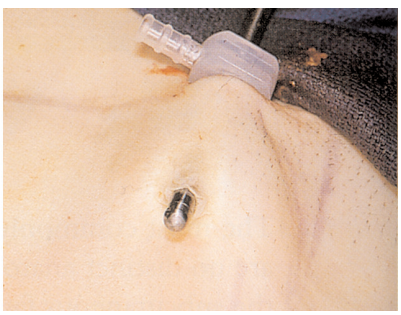

Penetration

Possible complication in prolonged and overly intensive superficial contouring

- *Erythema*
- *Blistering*
- *Penetration*

Inappropriate ultrasound treatment of the superficial fatty tissue can cause skin irregularities.

Five areas are considered inviolate except in rare instances:

1. Inferolateral iliotibial tract
2. Gluteal crease
3. Lateral gluteal depression
4. Middle medial thigh
5. Distal posterior thigh

The fat in these regions is densely adherent to the underlying structures and undermining often results in contour deformities and inadequate esthetic effects.

Moguće komplikacije u slučaju da je vreme aplikacije ultrazvuka produženo i/ili je neadekvatno visoko podešena snaga ultrazvučnog generatora su:

- *Erythema*
- *Blistering*
- *Penetration*

Neadeakvatni ultrazvučni tretman superficijalnog masnog sloja može dovesti do reljefnih nepravilnosti kože.

Pet zona treba izbegavati sem u retkim indikovanim slučajevima:

1. Inferolateralni iliotibial trakt
2. Glutealni pregib (*gluteal fold*)
3. Lateralno glutealno udubljenje (*lateral gluteal fold*)
4. Središnji unutrašnji deo butina (*middle medial thigh*)
5. Distalni zadnji deo butina (*distal posterior thigh*)

Masno tkivo ovih regija je veoma učvršćeno za dublje strukture i podminiranje ovih regija često izaziva nepravilnosti u konturi i loš estetski rezultat.

Most Frequent Genetically Defined Problem Zones:

- Upper and lower abdomen
- Lateral abdomen, flanks

Najčešće genetski definisane problem zone:

- Donji i gornji abdomen
- Lateralni Abdomen, Slabine

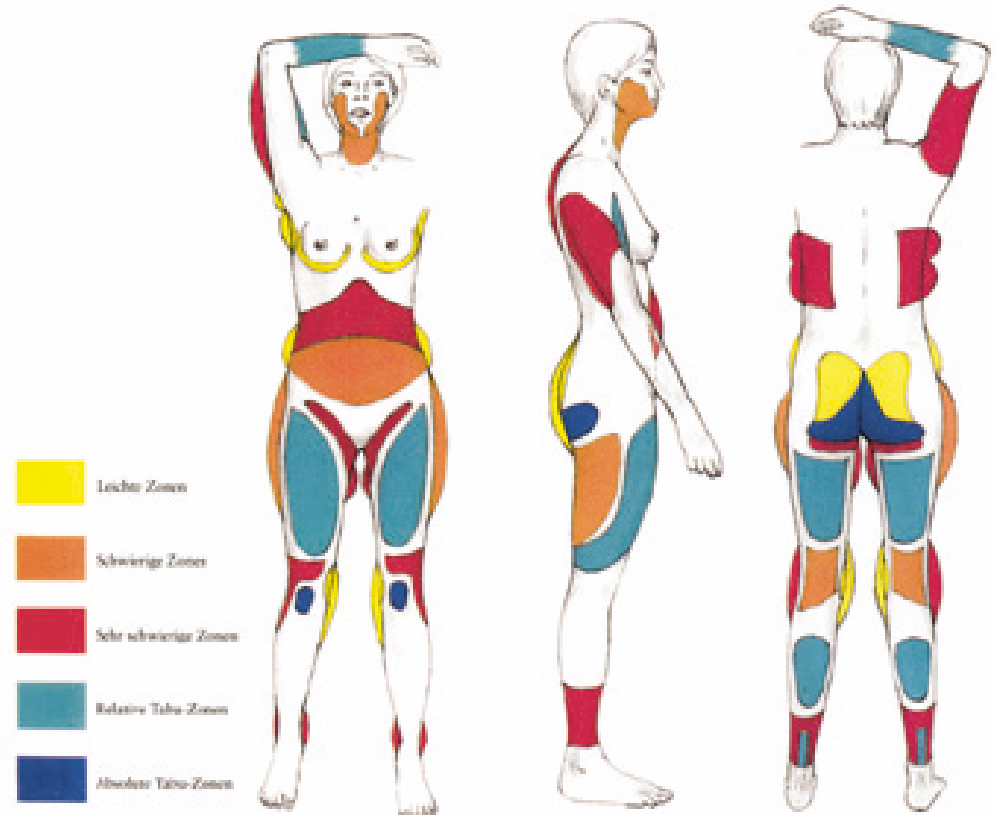

- Outer side of the thigh, "saddlebag" deformity

- Spoljašnja strana butina, fenomen jahaćih pantalonica (*saddle bag deformity*)

- Inner side of the thigh, frequent
- Front side of the thigh, less frequent (it's a taboo in SAL)

- Unutrašnja strana butina, često
- Prednja strana butina, ređe (predstavlja tabu temu u SAL-u)

- Inner side of the knee, frequent
- Front side of the knee, less frequent

- Unutrašnja strana kolena, češće
- Prednja strana kolena, ređe



• Extensor side of the brachium

• Ekstenzorna strana nadlaktica

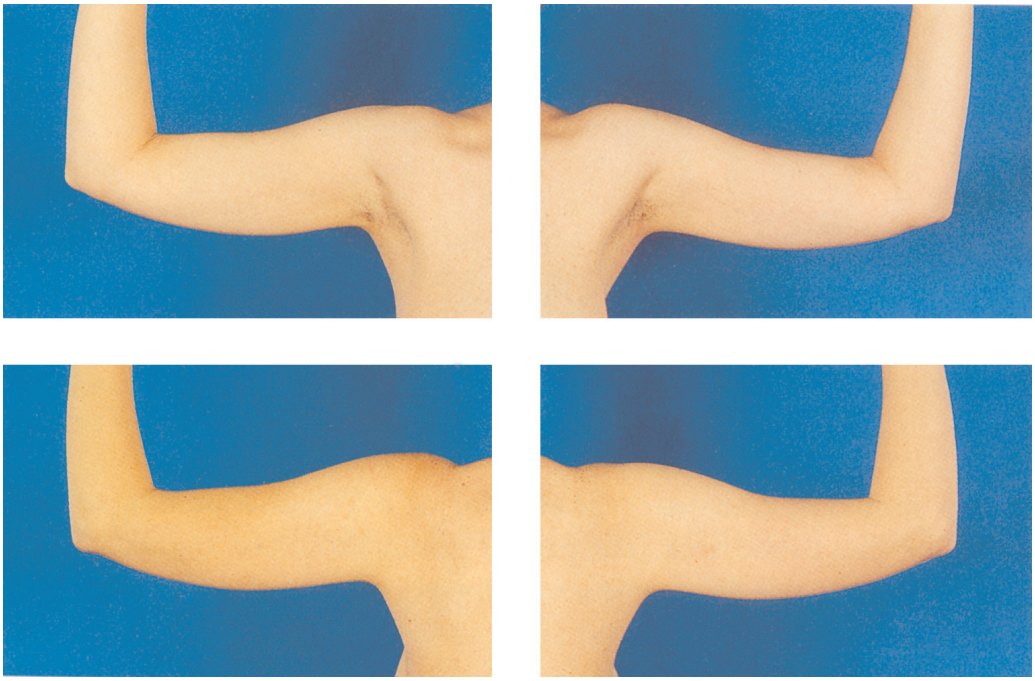

• Submental fatty pad

• Submentalni masni jastučić

Banana fold (roll) refers to layers of fatty tissue under the subgluteal fold (sulcusa). It is removed very superficially by following the Gasparotti principle.

G-point (The Gasparotti Point) is generally more than just a point. It is a 5 cm-wide area located at the meeting point of the posterior and lateral thigh and lat-

Banana fold (*roll*) predstavlja naslage masnog tkiva ispod subglutealne falte (sulcusa). Odstranjuje se vrlo superficijalno po Gasparotti principu.

G-Point (*Gasparotijeva tačka*) u principu je više nego tačka (spot) i predstavlja zonu od 5 cm, lokalizovanu na granici između spoljašnje i zadnje strane butina i spo-

eral gluteal area. G-point is important for modeling athletic-shaped buttocks with a concave subgluteal sulcus/fold. Horizontal subgluteal fold means voluminous, pear-shaped buttocks.

ljašnje strane glutealne regije.G point je bitan za kreiranje atletski oblikovane glutealne regije sa konkavnim subglutealnim sulcusom - fold (*athletic-shaped-buttocks*). Horizontalni *subgluteal fold* daje voluminozniji kruškasti izgled glutealne regije (*pear shaped buttocks*)

Selection of UAL probes and SAL cannulas:

Selection of ultrasound probes: depends on whether a fibrous or non-fibrous area is treated. A hollow ultrasound probe is used for treatment of the non-fibrous areas since it enables simultaneous emulsification and aspiration of the fatty tissue. A solid probe is used for treatment of other areas as well as for superficial contouring. Additional contouring is performed with the special SAL cannulas.

Selection of SAL cannulas: Standard aspiration cannulas used for aspiration of the emulsion produced in the solid ultrasound probe operation should not be larger than 4 mm for the deep layer and 2-3 mm for the superficial and intermediate layer. We achieved best results with cannulas that contain multiple offset side ports and resemble infiltration needles (Multiple-Hole Cannulas). Low vacuum control (0.4-0.5 Bar) is maintained via a small opening on the thumb niche located on a handpiece with mounted "multiple hole" liposuction cannula. This enables precise superficial contouring of larger areas.

In reductive liposuction, it is sometimes necessary to use classic cannulas with one, two, or max. three holes, 5-6 mm dia. in order to achieve faster aspiration of the emulsion from the deep lamelar layer of the fatty tissue.

Izbor UAL sondi i SAL kanila:

Izbor ultrazvučnih sondi: zavisi od toga da li se tretira fibrozni ili nefibrozni areal. Za tretman nefibroznih regija koristi se šuplja ultrazvučna sonda koja omogućava istovremenu emulzifikaciju i aspiraciju masnog tkiva. Za tretman ostalih areala kao i za superficijalno konturiranje preporučuje se puna titanijumska sonda "solid probe". Naknadno konturiranje se vrši specijalnim SAL kanilama.

Izbor aspiracionih (SAL) kanila: Standardne aspiracione kanile koje se koriste za apiraciju emulzije nastale radom pune ultrazvučne sonde ne treba da pređu 4 mm za duboki sloj odnosno 2 -3 mm za površni i intermedijalni sloj. Najbolje rezultate postigli smo upotrebom kanila sa više otvora sličnim tupim iglama za infiltraciju (*multiple hole cannula*). Kontrola niskog vakuuma (0,4 -0,5 Bar) postiže se preko malog otvora na udubljenju za palac lociranom na ručici (*handpiece*) na koju je montirana "multiple hole" liposukciona kanila. Ukoliko palac naleže na otvor ručice ima vakuuma, ukoliko nema, u tom slučaju nije moguća aspiracija već samo liposkulpturiranje. Ovo omogućava precizno superficijalno konturiranje većih površina.

Kod redukcionih liposukcija ponekad je potrebno imati i klasične kanile sa jednim, dva ili maksimalno tri otvora, promera od 5-6 mm kako bi se postigla brza aspiracija emulzije iz dubokog lamelarnog sloja masnog tkiva.

EVALUATION AND SELECTION OF THE PATIENTS

Suitable for Primary and Secondary Liposuction:

Through the consultation with a surgeon, a suitable candidate for primary UAL will get a clear picture of the

EVALUACIJA I IZBOR PRAVOG PACIJENTA

Za primarnu i sekundarnu liposukciju:

Pravi kandidat za primarnu UAL treba da ima jasan stav o tome kakvu korekciju konture želi i da nakon kon-

Class	Skin Excess	Diastasis	Treatment
Ia	No	No	UAL or SAL alone
Ib	No	Yes	UAL or SAL alone with or without endoscopic diastasis repair

Tip	Višak kože	Dijastaza	Tretman
Ia	Ne	Ne	UAL i/ili SAL
Ib	Ne	Da	UAL sa ili bez endoskopskog tretmana dijastaze

Class	Skin Excess	Diastasis	Treatment
IIa	Mild	No	UAL or SAL alone
IIb	Mild	Yes	UAL or SAL alone with or without endoscopic diastasis repair

Tip	Višak kože	Dijastaza	Tretman
IIa	Minimalan	Ne	UAL i/ili SAL
IIb	Minimalan	Da	UAL sa ili bez endoskopskog tretmana dijastaze

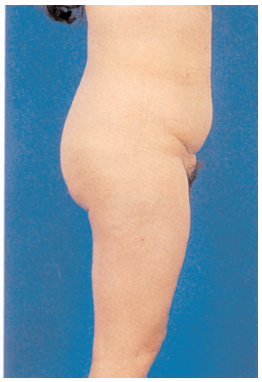

Class	Skin Excess	Diastasis	Treatment
IIIa	Moderate	No	UAL
IIIb	Moderate	Yes	Infraumbilical miniabdominoplasty with diastasis repair + UAL treatment of epigastrium

Tip	Višak kože	Dijastaza	Tretman
IIIa	Umeren	Ne	UAL
IIIb	Umeren	Da	Infraumbikalna RF i Laser miniabdominopstika sa reparaturom dijastaze i UAL tretmanom epigastrijuma

Class	Skin Excess	Diastasis	Treatment
IVa	Significant	No	Traditional abdominoplasty + UAL treatment of flank
IVb	Significant	Yes	Traditional abdominoplasty with diastasis repair + UAL treatment of flank

Tip	Višak kože	Dijastaza	Tretman
IVa	Izražen	Ne	Kombinovana UAL i SAL gornjeg i donjeg abdomena, slabina kao i laser- radiotalasna horizontalna abdominoplastika
IVb	Izražen	Da	laser- radiotalasna horizontalna abdominoplastika, reparacija dijastaze i UAL tretman slabina

desired contour correction and understand what result can be expected. Number of problem zones tackled in an intervention must be both aesthetically and medically justified. The expected result can be maximal, optimal or good. It is not solely dependent on the surgeon's skill, but also on the skin quality, body structure, density of fatty tissue, etc. Like all candidates for aesthetic liposuction, UAL patients must be personally motivated to undergo surgery, i.e. it is they themselves who must wish to become more attractive. In our opinion, a patient who seeks treatment because persuaded or urged by a partner, spouse, friend, parent, etc. is not a suitable candidate nor is she likely to be satisfied with the result, even if it is the best. The patient who does not inquire about the surgery but immediately asks for the price or insists that the "volume" is reduced and all problem zones removed by the speed of lightning or wants to be operated immediately, paying no heed to your schedule, should be advised to reconsider the issue and to make another consultation appointment.

Secondary liposuction patients are often upset with their initial surgeon. They should be encouraged to wait 6 to 9 months to see if skin and fatty tissue irregularities will resolve without intervention. If the patient is overly hostile, litigious and/or angry with the primary surgeon, it is unlikely that she will be satisfied with any correction you might make. In case of several larger deformities of body contour, the patient should be explained that an overall correction is impossible. She should be urged to indicate the area of her primary concern.

Generally, if you cannot reach a mutual understanding, affinity and consensus with a candidate, it is best to recommend her/him a surgeon of your choice.

Who is suitable for Liposuction, Lipectomy or their combination

The patient should be evaluated for skin tone, muscle laxity, abdominal wall scars, and hernias. In patients with abdominal lipodystrophy we use a modification of the Matarasso clasification to categorize treatment options. This clasification is based on an evaluation of the degree of redundance of the skin and fat of the abdominal wall, the skin thickness and tone, and underlying abdominal musculature. UAL will improve abdominal contour in patients with mild skin excess.

One principal advantage of UAL is that type of II and III patients (those with mild to moderate skin excess with moderate diastasis) can be treated successfully in conjunction with endoscopic or limited incision RF & Laser abdominoplasty.

sultacije bude saglasan sa očekivanim rezultatom. Broj problema zona koji se radi u jednoj intervenciji mora imati smisao kako sa estetskog tako i iz zdravstvenog aspekta. Očekivani rezultat može biti maksimalan, optimalan ili dobar, a zavisi ne samo od umeća hirurga već od kvaliteta kože, građe i gustine masnog tkiva itd. Kao svaki kandidat za estetsku liposukciju, pacijent za UAL treba da želi korekciju iz ličnih razloga u smislu da bi se dopao sebi i okolini. Potencijalni pacijent koji želi da se podvrgne UAL po nagovoru ili na insistiranje partnera, prijatelja, roditelja itd. po našem stavu nije pravi kandidat i treba očekivati da neće biti zadovoljan čak i najboljim rezultatom. Pacijenta koga ne zanima ni kako ni čime će se raditi operacija, pita odmah za cenu, ili insistira da se munjevito smanji "volumen" i uklone sve problem zone, želi operaciju odmah bez poštovanja vaših termina treba saslušati i posavetovati da razmisli i da zakaže još jedan termin za konsultaciju.

Kandidati za sekundarnu liposukciju su često nezadovoljni svojim prvim hirurgom. Njih treba ohrabriti da sačekaju 6 do 9 meseci da bi se videlo da li će se nepravilnosti na koži i masnom tkivu povući bez intervencije. Ukoliko je pacijent preterano neprijateljski raspoložen, zahtevan i/ili ljut na prethodnog hirurga nerealno je očekivati da će biti zadovoljan svakom daljom korekcijom. U slučaju više grubih deformiteta konture tela pacijentu treba objasniti da apsolutna korekcija nije moguća i da je najbolje da on sam navede najproblematičnije areale koje treba ublažiti ili ako je moguće korigovati.

Generalno gledano, ukoliko ne postoji razumevanje, obostrana simpatija i konsenzus između pacijanta i hirurga najbolje je pacijenta uputiti kod kolege u koga vi imate poverenja.

Ko je pogodan za liposukciju, dermolipektomiju ili njihovu kombinaciju

Kod kandidata je potrebno uraditi procenu tonusa kože, postojećih ožiljaka, slabosti mišića i trbušne prese kao i utvrditi postojanje eventualne dijastaze rektursa ili hernije. Kod pacijenata sa abdominalnom lipodistrofijom koristimo modifikovanu "Matarasso" klasifikaciju da bi izvršili kategorizaciju operativnih postupaka. Klasifikacija je bazirana na proceni slabosti elasticiteta kože kao i lipodistrofije masnog tkiva trbušnog zida, na debljini i tonusu kože trbušnog zida i trbušnih mišića. UAL će popraviti konturu abdomena kod pacijenata sa umerenim viškom kože.

Jedna od odlučujućih prednosti UAL je da se pacijenti tipa II i III (sa blagim do umerenim viškom kože sa umerenom dijastazom) mogu tretirati u kombinaciji sa endoskopskom ili RF&Laser horizontalnom abdominoplastikom.

OPERATIVE STAGES OF THE GENERAL UAL SURGERY TECHNIQUE

- Preopreative Preparation and Surgery Planning*
- Positioning of the Patient*
- Stage I: Infiltration*
- Stage II: Ultrasound (UAL Treatment)
- Stage III: Evacuation and Final Contouring ("Roller" and Manual Sculpting)
- Stage IV: Application of Dressing and "Compression Garments"

** A detailed description of the preoperative preparation, patient positioning and wetting solutions follows in the heading referring to anesthesia.*

STANDARDNA HIRURŠKA TEHNIKA RADA PO OPERATIVNIM FAZAMA

- Preopreativna priprema i planiranje operacije*
- Pozicioniranje pacijenta*
- Faza I: Faza Infiltracije*
- Faza II: Ultrazvučna faza (UAL Tretman)
- Faza III: Faza aspiracije i finalnog konturiranja ("roller" i manuelno skulpturtiranje)
- Faza IV: Brižno bandažiranje i aplikacija adekvatnog kompresionog postoperativnog veša "Compression Garments"

** Preoperativna priprema, pozicioniranje Pacijenta i Infiltracioni rastvori su detaljno opisani u delu vezanom za anesteziju.*

Surgery Planning

Liposuction Patient Selection

Achieving optimal esthetic goals, planning and final results are heavily dependent on proper UAL/SAL patient selection. Good quality of skin, good muscular tone and regular skeletal system are prerequisites for achieving excellent or optimal esthetic result. In case of the high skin laxity, i.e. when minimal retraction is expected, a classic plastic operation would be a better option. If skin and fatty tissues fail to retract optimally after the abdomen liposuction, the patient should be prepared for mini abdominoplasty. In such cases, abdominoplasty is of a much lesser range and is practically reduced to the excision of skin redundancy and minimal quantity of fatty tissue.

Preoperative markings of the problem zones and skin irregularities, and access incisions:

Problem zones are marked by half-circles and circles and their punctum maximum by "X". Because of their

Planiranje operacije

Odabiranje pacijenta za liposukciju

Estetski cilj, planiranje i konačni rezultat intervencije , umnogome zavisi od pravilnog odabira pacijenta za UAL/SAL. Kvalitet kože, dobar tonus mišića i pravilnost skeletnog sistema preduslov su za odličan ili optimalan estetski rezultat. U slučaju opuštene kože (high skin laxity) od koje se očekuje minimalna retrakcija treba se odlučiti za neku od klasičnih plastičnih operacija. U slučaju da nakon redukcione liposukcije abdomena ne dođe do optimalne retrakcije kože i masnog tkiva može se pacijent pripremiti na mini abdominoplastiku koja je ovde daleko manjeg obima i svodi se praktično na eksciziju viška kože i minimalne količine masnog tkiva.

Preoperativno markiranje problem zona i nepravilnosti na koži i ulaznih incizija:

Polukrugovima odnosno krugovima markiraju se problem zone a njihov punktum maksimum sa X. Loka-

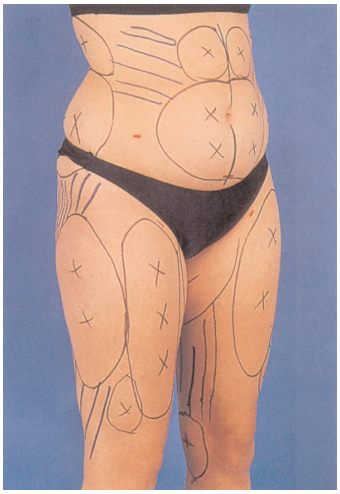

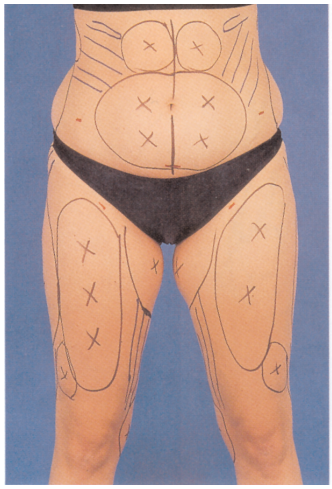

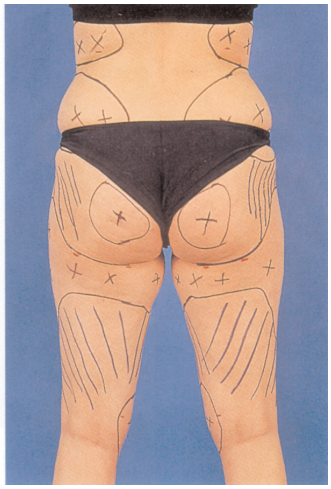

length (5-8 mm), localization of UAL access incisions must be much more carefully planned than SAL incisions.

Preoperative markings

The markings are often asymmetric, reflecting the patient's anatomic asymmetry

lizacija ulaznih incizija za UAL zbog njihove dužine (5-8 mm) zahteva mnogo pažljivije planiranje nego kod SAL incizija.

Preoperativno crtanje

Crteži su često asimetrični, reflektujući time pacijentovu anatomsku asimetriju

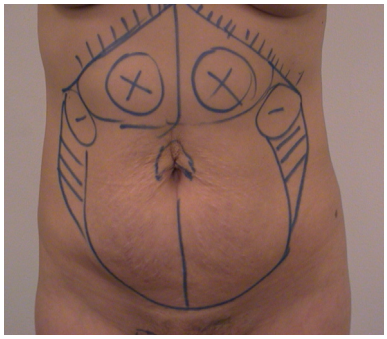

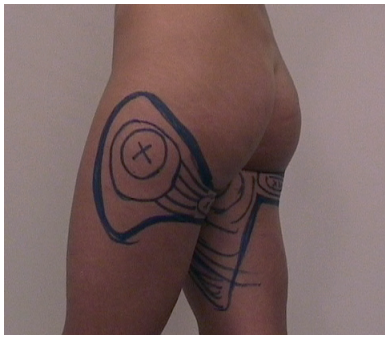

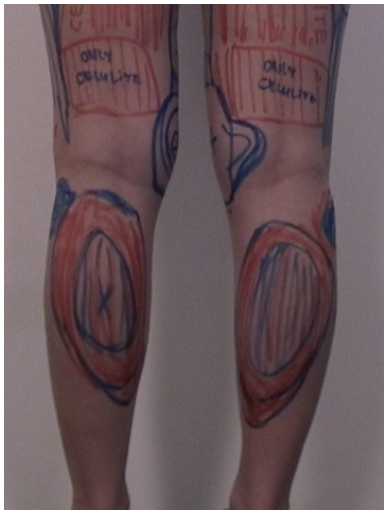

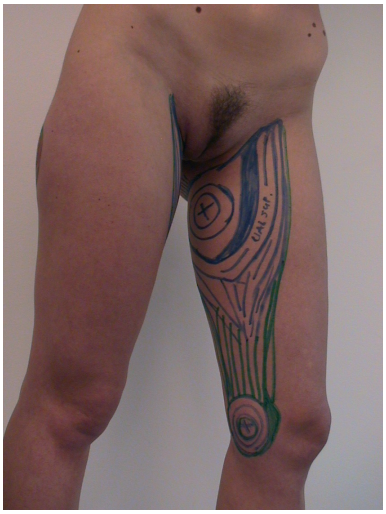

Acess Incisions

Access incisions for infiltration planning, UAL and SAL, as per the areas and zones:

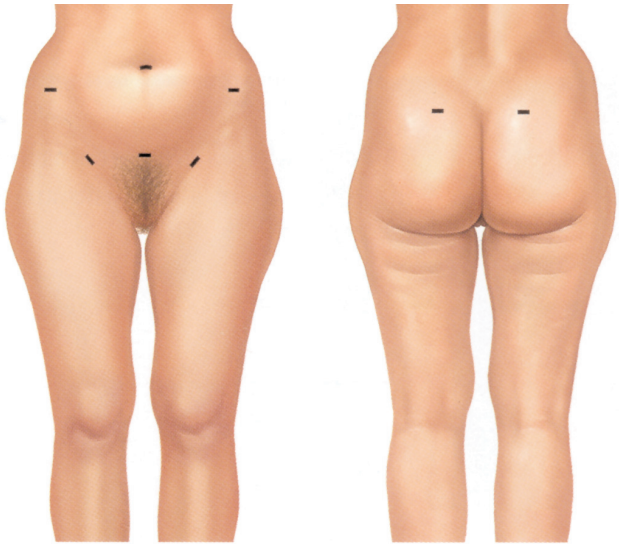

Ulazne Incizije

Planiranje ulaznih incizija za UAL i SAL po anatomskim regijama.

Stage I: Infiltration

A "superwet" technique offers the advantages of tumescence but allows better control of the volume of the infiltrated solution. The end point of infiltration is not signaled by tumescence but rather by a uniform blanching and skin turgor. The volume of the infiltrated solution

Faza I: Faza Infiltracije

Supervlažna tehnika nudi prednosti tumescentne tehnike ali i omogućava bolju kontrolu infiltrisanog volumena rastvora. Krajnji efekt infiltracije nije signaliziran efektom tumescencije nego uniformnim bledilom i turgorom kože. Infiltrirani volumen rastvora je skoro jed-

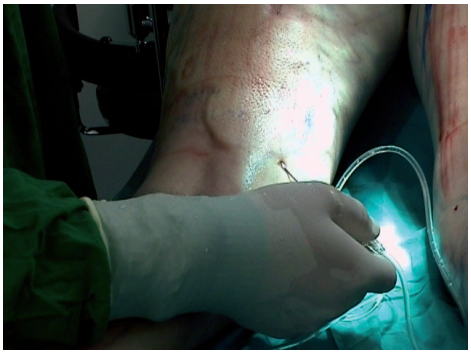

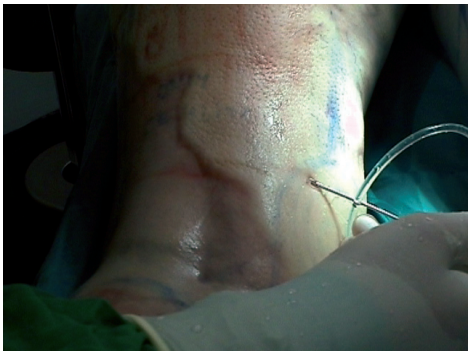

is approximately equal to the volume of fatty emulsion to be removed from the targeted problem area. The transition areas at the periphery of the treatment areas, the so-called feathering areas, are also infiltrated with wetting solutions since the blunt-tip UAL probe will be used here for final contouring. Once we attained uniform blanching and maximal skin turgor and before starting with the UAL stage, we made a 10-20 minute pause to allow the vasoconstrictive adrenaline effect to take place. For treatment of large and voluminous areas such as upper and lower abdomen and front flanks, we recommend usage of two infiltration pumps and obligatory assistance of other surgeon.

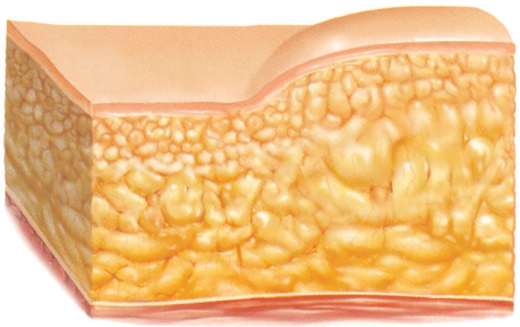

nak volumenu masne emulzije koji će biti evakuisan sa određene problem regije. Prelazne zone na periferiji tretiranih oblasti, tzv. *feathering zone*, takođe se infiltriraju vlažnim rastvorima, pošto će se puna UAL sonda koristiti za finalno konturiranje. Nakon što postignemo uniformno bledilo kože i maksimalni turgor kože, a pre nego što bi počeli sa UAL fazom, pravili smo pauzu od 10 do- 20 min. da bi smo omogućili vazokonstriktivno dejstvo adrenalina. U slučaju tretmana velikih i voluminoznih regija kao što je tretman gornjeg, donjeg abdomena i prednjeg dela slabina, preporučujemo upotrebu dve infiltracione pumpe uz obligatornu asistenciju drugog plastičnog hirurga.

Stage II: Ultrasound (*UAL Treatment*)

The access incision for UAL probe is 2 to 4 mm longer than that commonly used in SAL, and should be carefully planned, especially in the flank and back since the residual scars can be noticeable. The subcutaneous fatty tissue is dilated with a blunt trocar or pean. The skin protector is inserted at a 90-degree angle to the skin, and the UAL cannula is inserted into the protector and subcutaneous tissue, also perpendicular to the skin. Areas such as thighs and flanks that require circumferential treatment are treated posteriorly first. Approximately 70 to 90% of circumferential treatment can be performed posteriorly. The fundamental advantage of UAL is that fat is removed through cavitation not through mechanical avulsion as in SAL. Technique of the UAL

Faza II: Ultrazvučna faza (*UAL Tretman*)

Ulazna incizija za UAL sondu je 2-4 mm duža nego ona za SAL i mora biti brižljivije planirana posebno u predelu slabina i leđa posebno zbog rezidualnih ožiljaka. Supkutano masno tkivo dilatirano je adekvatnim *blant trokarom* ili peanom. Skin protektor je insertovan pod uglom od 90° u odnosu na kožu a UAL sonda uvučena kroz kavitet protektora u supkutano masno tkivo, takođe perpendikularno prema koži. Areali koji zahtevaju cirkumferentni tretman kao što su bokovi i slabine prvo se tretiraju sa posteriorne strane. Aproksimativno 70% do 90% cirkumferentnog tretmana može se izvesti sa zadnje strane. Fundamentalna prednost UAL je da je mast odstranjena kroz kavitacije, a ne kroz mehaničke avulzije masnog tkiva kao u SAL. Tehnika kretanja UAL

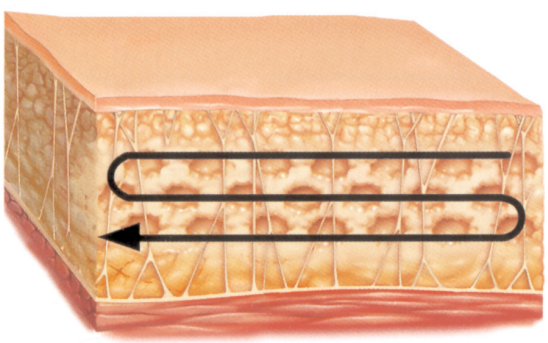

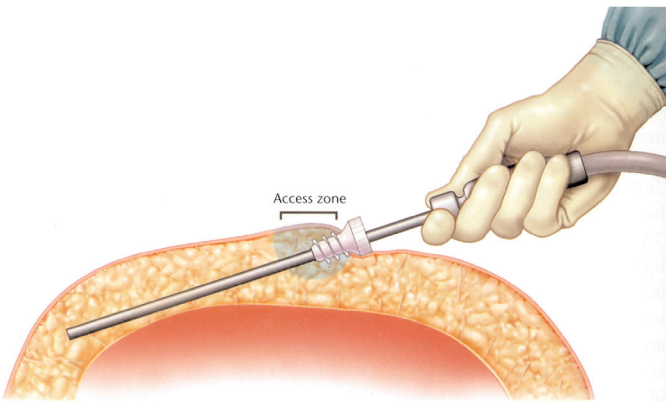

probe movement differ from that of the SAL cannula. UAL is a dynamic technique. Therefore the stroke rate in UAL must be considerably slower, about 50% the rate used for SAL. Speed and number of constant UAL probe movements are defined by the resistance of targeted fatty tissue. The greater the resistance of the fatty tissue, the lesser is the speed of the UAL probe movement. UAL probe excursions are longer than excursions of the SAL cannula since cavitation process takes place only on the probe tip.

sonde se razlikuje od one kod SAL kanile. UAL je dinamička metoda i zahteva u principu oko 50% sporije kretanje UAL sonde u odnosu na kretanje SAL kanile. Brzina i broj konstantnih pokreta UAL sonde procenjuje se po rezistenciji tretiranog masnog tkiva. Što je otpor masnog tkiva veći brzina kretanja UAL sonde je manja. Ekskurzije UAL sonde su duže nego SAL kanile jer se proces kavitacije dešava samo na vrhu sonde.

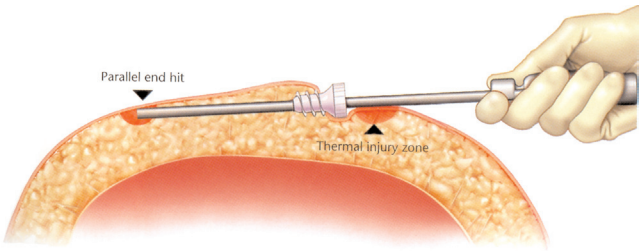

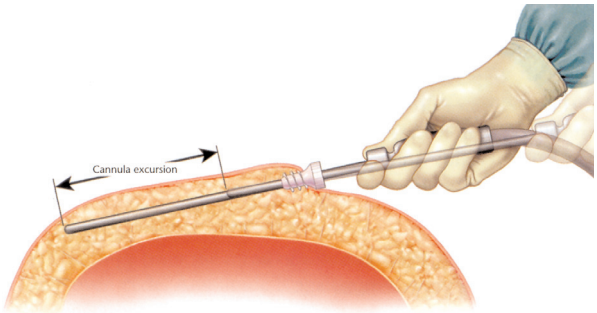

	SAL	UAL
Stroke Characeristics	Forceful	Slow, rhytmic stroke
Access incisions	3 mm	Longer
Criss Cross	Yes	Not obligatory
Skin protector	No	Yes
Method of Fatty Tissue Treatment per Layers	From depth to surface	From surface to depth
End point	Final contour (pinch test)	Loss in resistance, blood aspirate
UAL probe/Cannula motion	Continous	Intermittent
Nondominant hand position	Grasping and firm palpitations of tissue under "curettage"	Gentle parallel palpitations

	SAL	UAL
Karakteristike poteza	Snažni	Lagani, ritmički potezi
Pristupni rez	3 mm	Duži
Criss Cross	Da	Nije obavezno
Zaštita kože	Ne	Da
Metoda tretmana masnog tkiva po slojevima	Od dubine ka površini	Od površine ka dubini
End point	Krajnja kontura ("pinch proba")	Gubitak otpora, krvav aspirat
UAL proba/Pokreti kanile	Kontinualni	Isprekidani
Nedominirajuća pozicija ruke	Grasping i čvrste palpitacije tkiva pod "kiretažom"	Blage paralelne palpitacije


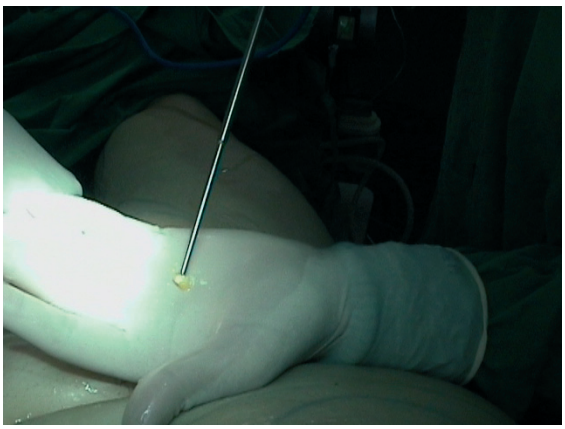
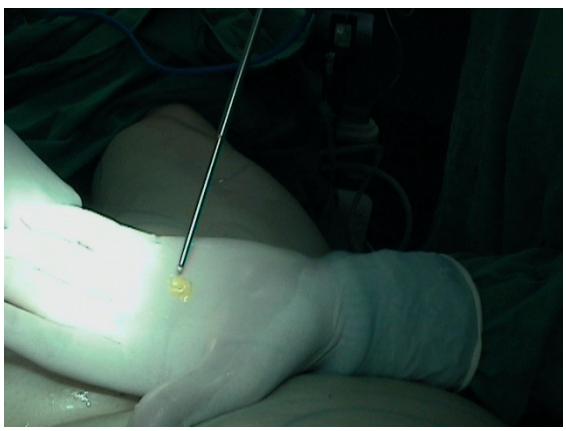
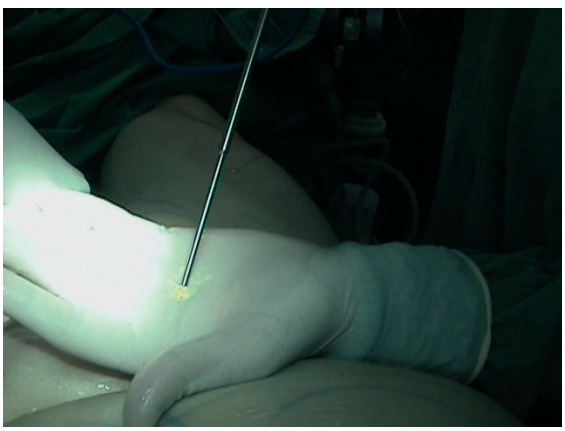

Stage III: Evacuation and Final Contouring *("Roller" and Manual Sculpting)*

In the evacuation stage, a standard surgical aspirator is used at 70% of the maximal intensity. Depending on the area and volume of fat, traditional liposuction cannulas with 1, 2 or 3 openings of 3-6 mm in diameter are used for deep liposuction, and "multiple hole" cannulas with holes of 2-4 mm in diameter are used for the treatment of the intermediate and superficial layer.

"Roller" and Manual Sculpting:

Aspiration of the emulsion is not desirable in the following cases:

- cellulite treatment as the isolated procedure
- liposculpting of previously defined non-voluminous or taboo areas

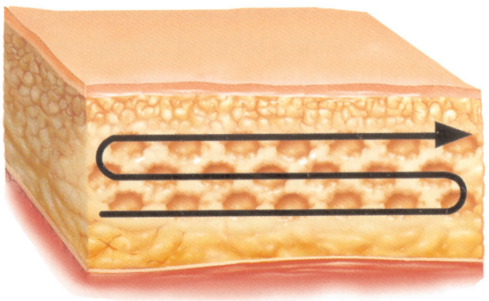

SAL treatment begins from the dependent deep layer and progresses through the intermediate to the superficial fatty tissue / SAL tretman započinje od dubokog progresivno preko intermedijalnog do superficijalnog masnog sloja

Faza III: Aspiracija i finalno konturiranje *("roller" i manuelno skulpturiranje)*

U fazi aspiracije standardni hirurški aspirator podešava se na 70 % snage od maksimalne. Zavisno od regije i količine masnog tkiva koriste se tradicionalne liposukcione kanile sa jednim, dva ili tri otvora dijametra 3-6 mm za duboku liposukciju a "multiple hole" kanile sa više otvora dijametra 2-4 mm za tretman intermedijalnog i superficijalnog sloja.

Roller i manuelno skulptruiranje:

U sledećim slučajevima aspiracija emulzije nije poželjna:

- tretman celulita kao izolovana procedura
- liposkulpturiranje određenih nevoluminoznih regija il tabu regija

Manual remodeling and sculpting, either with the palm of the hand or a "roller" device (similar to that used in massage), yields fantastic results. The ultrasound-produced emulsion is squeezed out through access incisions / Manuelno remodeliranje i skulpturiranje uključujući upotrebu prstiju i/ili rolera (valjak sličan onom za masažu) daje fantastičan rezultat. Emulzija nastala dejstvom ultrazvuka istisne se kroz ulazne incizije

Superficial Contouring

Superficial contouring may be indicated in patients with skin irregularities, such as cellulite and skin laxity. Superficial treatment with the ultrasound probe stimulates production of juvenile collagen. The UAL probe should be moved using a slightly faster stroke rate than when performing UAL in deeper layers and power setting is adjusted to approximately 30% of normal.

Superficijalno konturiranje

Superficijalno konturiranje indikovano je kod pacijenata sa nepravilnostima na površini kože tipa celulita, neravnina ili kod mlitave kože (skin laxity). Superficijalnom tretmanom Ultrazvučnom sondom stimulišemo produkciju juvenilnog kolagena. Kretanje UAL probe je nešto brže nego u dubljim slojevima a UAL snaga podešena na 30% od uobičajene.

SAL treatment using 2-3 mm SAL cannulas with 50% of maximal vacuum results in final contour and so-called feathering effect, i.e. fine unobtrusive passage from the treated to the untreated zone. The superficial UAL / SAL treatment can be completed by manual or "roller" contouring.

SAL tretman, sa SAL kanilama 2-3 mm, vakuum na 50% od maksimuma, daje finalnu konturu i tzv. *Feathering effect*, tj. fini nenametljivi prelaz iz tretirane u netretiranu zonu. Superficijalni UAL / SAL tretman može se finalizovati manuelnim i "roler" konturiranjem.

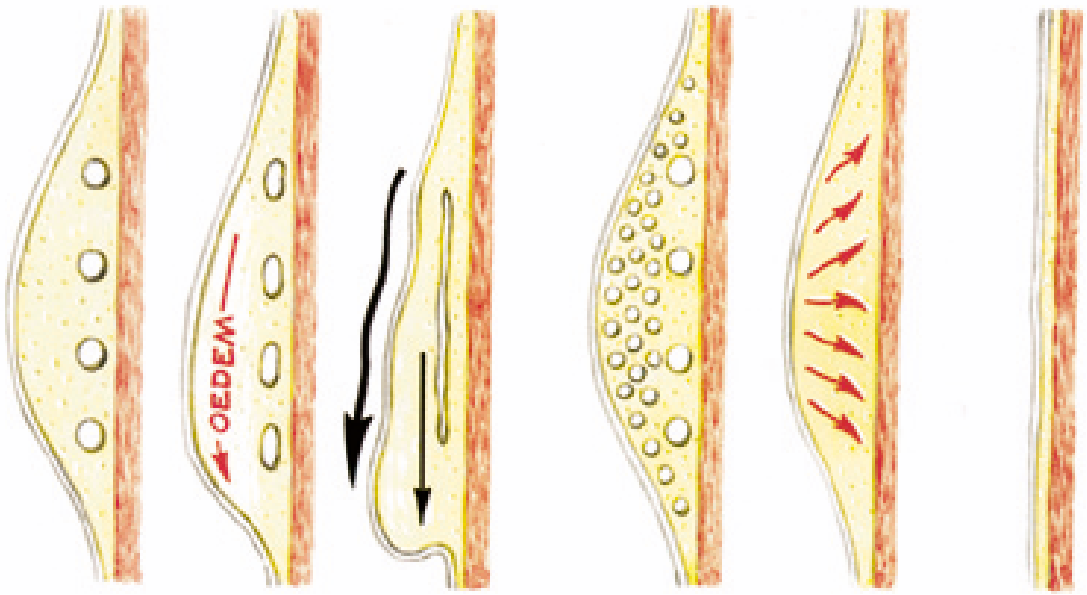

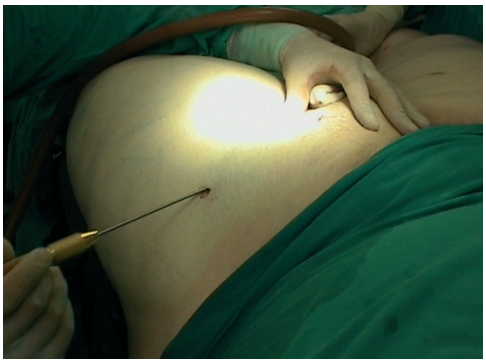

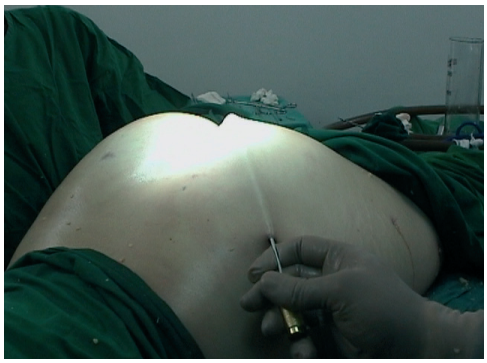

Drains:

Indications for the use of drains:

1. After removal of large emulsion volumes from upper and lower abdomen and flanks.
2. Patients with moderate skin laxity in whom the skin is aggressively treated.
3. Combined UAL, SAL of the abdomen and/or flanks and horizontal abdominoplasty.

Placement of drains minimizes incidence of seroma and accelerates attainment of the desired contour, particularly in lower abdomen and supra-pubic area. In men, it helps to avoid scrotum edema induced by gravitation and draining of the suprapubic area.

Upotreba drenova:

Upotreba drenova indikovana je samo u sledećim slučajevima:

1. Nakon evakuacije velike količine emulzije iz gornjeg i donjeg abdomena i slabina.
2. U pacijenata sa umereno opuštenom kožom u kojih je koža agresivnije tretirana.
3. Kombinovana UAL, SAL abdomena i/ili slabina i horizontalna abdominoplastika.

Plasiranje drena minimiraće pojavu seroma i brže dovesti do željene konture posebno donjeg abdomena i suprapubične regije. Kod muškaraca će se izbeći mogući otok skrotuma nastao gravitacijom, slivanjem iz suprapubične regije.

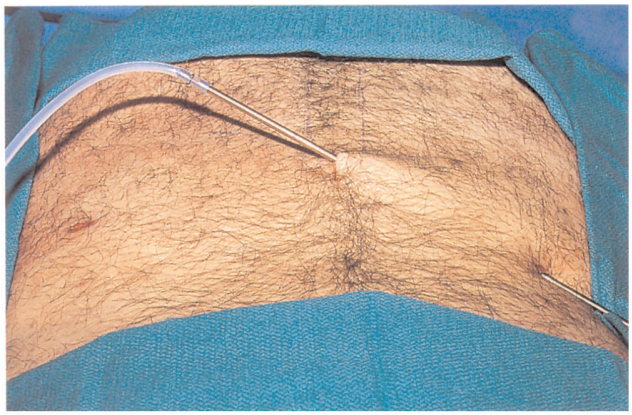

Closure of Incisions

Subcutaneous placing of the absorbable 4.0 thread with smoothing the knot into the depth. The skin is sewn with a 3.0 intradermal stitch. Some authors leave the incision open in order to intensify drainage and sew the incisions 6 to 14 hours after the operation.

Zatvaranje incizija

Potkožno plasiranje resorptivnog 4.0 konca sa poravnanjem čvora u dubinu. Koža se šije sa 3.0 intradermalnim šavom. Neki autori ostavljaju incizije otvorenim radi intenzivnije spontane drenaže a incizije ušivaju nakon 6 do 14 časova nakon operacije.

Stage IV: Application of Dressing and Appropriate "Compression Garments"

Careful application of dressing and appropriate "compression garments" will guarantee that your surgical-artistic oeuvre would be well protected. This is an extremely important part of the treatment and our endeavor to attain final results. ■

Faza IV: Bandažiranje i aplikacija adekvatnog kompresionog postoperativnog veša

Brižno bandažiranje i aplikacija adekvatnog kompresionog postoperativnog veša garantuju očuvanje vašeg hirurškog - umetničkog umeća, i neobično su bitan deo ukupnog tretmana u postizanju finalnog rezultata. ■

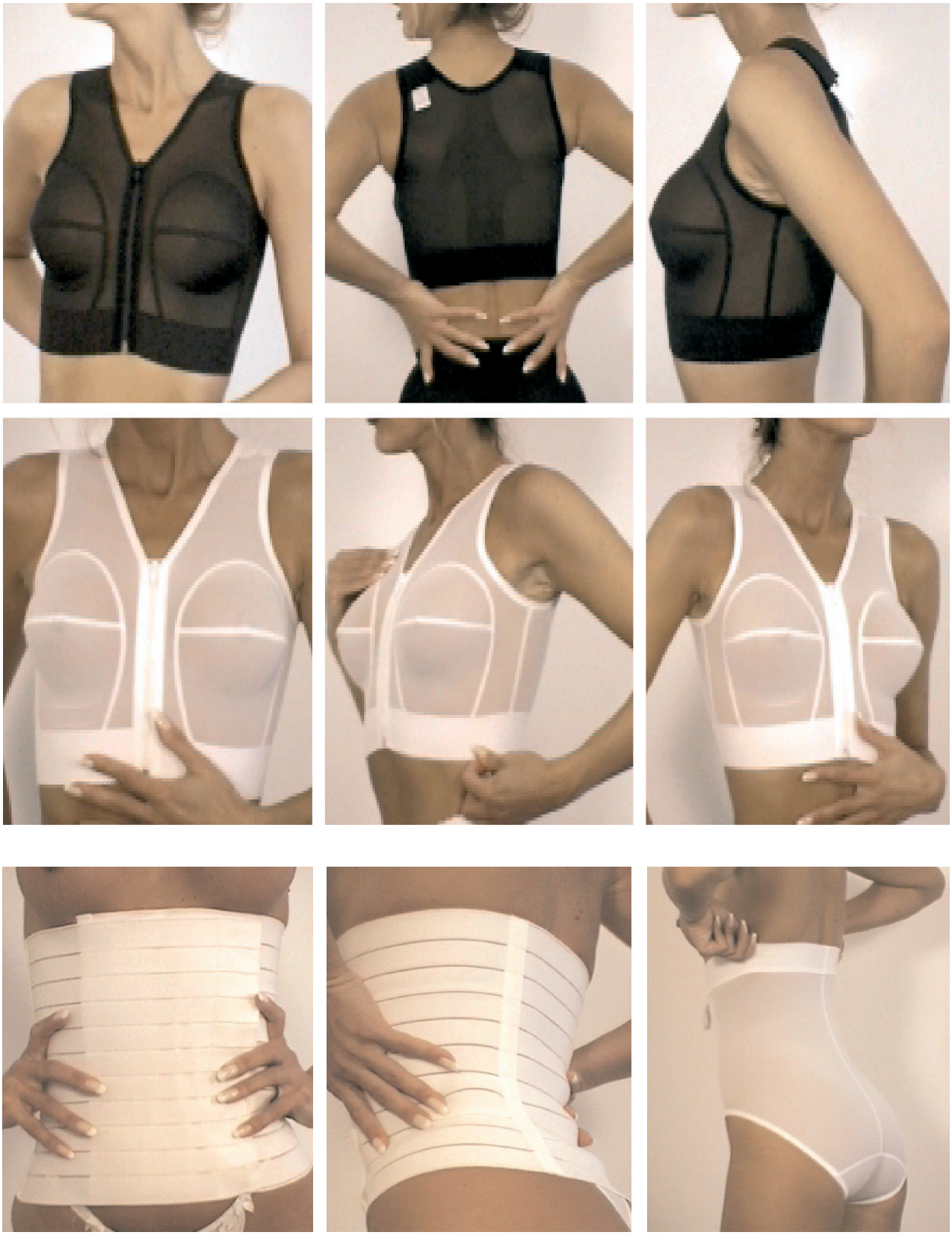









Art, Philosophy & Surgery

Liposuction is a philosophy and art of modeling face and body curves

Liposuction is more than just a combination of different techniques (maneuvers). Liposuction is a form of art, quite similar to sculpting although more complex. If esthetic surgery is figuring and liposuction is sculpting, one can easily make a supposition that an excellent esthetic surgeon would not simultaneously excel in liposuction. Reading the Pittman's book on liposuction a long time ago, I paid much thought to his introductory sentence saying that when he first encountered traditional liposuction in Europe, he was fascinated that this seemingly "non-surgical method" can, in the hands of a master, yield such good results (see *Liposuction & Aesthetic Surgery*, Gerald H. Pitman).

"Having a feeling for a definite form in liposuction ... knowing how, where, for how long to treat and when to stop, it is equally hazy and undefined as it is in the art. Making a beautiful woman who has several apparent problem zones more beautiful is much more difficult than making a fat woman slim". ***B.C.***

Umetnost, filozofija i hirurgija

Liposukcija je filozofija i umetnost modelovanja oblina tela i lica

Liposukcija nije samo kombinacija različitih tehnika, već umetnost najsličnija vajarstvu ali u mnogome kompleksnija od toga. Ako uzmemo da je estetska hirurgija slikarstvo a liposukcija vajarstvo, onda treba analogno gledano pretpostaviti da ne znači da odličan estetski hirurg mora biti odličan i u liposukciji. Davno čitajuci Pittman-ovu knjigu o liposukciji, dugo sam razmišljao o njegovoj uvodnoj rečenici da ga je tokom prvog susreta sa tradicionalnom liposukcijom u Evropi fasciniralo kako naizgled vrlo "nehirurška metoda" može u rukama "majstora" dati tako dobre rezultate. (ref: *Liposuction & Aesthetic Surgery*; Gerald H. Pitman).

"Osećaj za definitivnu formu u liposukciji ... kako, gde, koliko, koliko dugo tretirati, i kada stati sa radom podjednako je nejasno i nedefinisano kao i u umetnosti. Mnogo je teže od lepe žene sa nekoliko vidnih problematičnih zona napraviti lepšu nego od debele napraviti vitkiju ženu". ***B.Ć***

COMPLICATIONS FOLLOWING SAL & UAL
can be of esthetic or surgical nature

Aesthetic Complications

There is a relatively frequent occurrence of slight, for non-connoisseurs almost imperceptible irregularities on skin or in subcutaneous layer. However, some esthetic results can be so drastic that it is almost impossible to correct them.

- Asymmetry
- Contour Irregularities
- Hyperpigmentation and Dyschromia as a result of post-operative hemosiderin deposits in tissues
- Swellings and Cavities, more or less perceptible
- "Stairway" or "Accordion" Phenomenon

Serious Aesthetic Complications:

- cavities, individual or multiple, in the shape of a vafle or a bow
- elongated cavities in the shape of the individual, multiple and/or criss-crossed channels
- overcorrections with the occurrence of the corrugated or indented surface, "parchment" or "saw" appearance
- deep treatment with damage of fascia lata and/or subfacial hematoma occurrence

KOMPLIKACIJE NAKON SAL & UAL
mogu biti estetske i hirurške prirode

Estetske komplikacije

Relativno često mogu se javiti lakše ili pak za laika jedva upadljive neravnine i nepravilnosti na koži i potkoži. Ima i takvih katastrofalnih estetskih rezultata da ih je skoro nemoguće korigovati.

- asimetrija
- nepravilnosti u konturi
- hiperpigmentacija i dishromija može nastati kao posledica depoa hemosiderina u tkivu nakon tretmana.
- više ili manje upadljiva ispupčenja i udubljenja
- pojava "stepenica" ili fenomena harmonike

Teške estetske komplikacije:

- udubljenja: pojedinačna ili multipla u obliku vafela ili luka
- duguljasta udubljenja u obliku pojedinačnih, multiplih i / ili ukrštenih kanala
- prekomerne korekture sa pojavom zgužvane površine i izgledom pergamenta ili pak testerastog izgleda.
- duboki tretman sa oštećenjem fascije late i/ili pojavom subfascijalnih hematoma

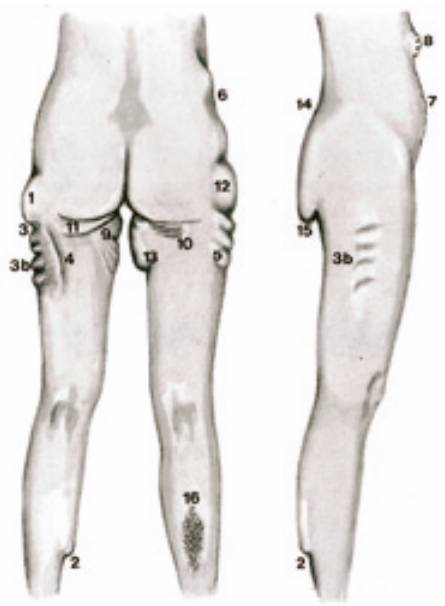

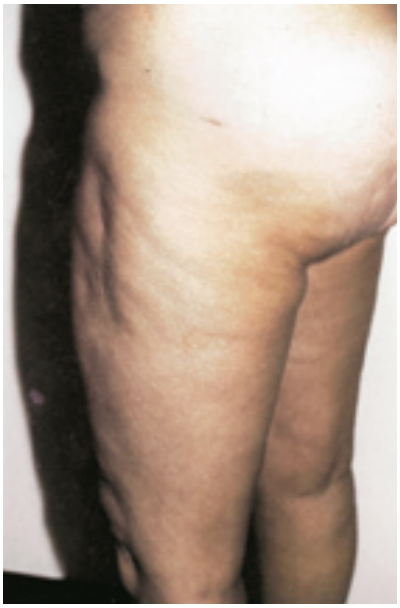

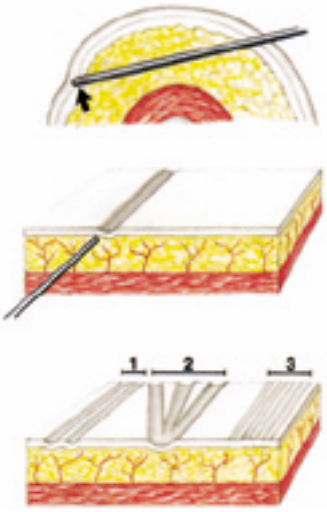

Combination of several esthetic complications results in the old-looking skin or a "moon surface" phenomenon, i.e. in the face full of holes and irregularities

Kombinacija više estetskih komplikacija daje ili staračku kožu ili fenomen mesečeve površine, odnosno lice prepuno rupa i neravnina.

This 54 years old woman, who was a heavy smoker, had a severe ishemic injury of the medial thighs subsequent to very aggresive UAL treatment / Ova 54-godišnja žena, strastveni pušač, imala je ozbiljne ishemijske ozlede središnjeg dela butine, nakon veoma agresivnog UAL tretmana

Six months after the primary procedure, the patient underwent debridement and skin grafting / Šest meseci nakon primarne procedure, pacijent je podvrgnut uklanjanju tkiva i presađivanju kože

Correction of the Aesthetic Complications

Smaller esthetic irregularities, such as smaller cavities, undercorrected parts of the treated area, and asymmetries, can be corrected by the combination of UAL and SAL method.

A suction process can diminish organized hematoma several months after the surgery. In case of hyperpigmentation, the patient should be advised to avoid sun exposure and solarium as well as usage of the depigmentation creams such as Hydrochinon.

Undulating irregularities at the lateral thigh are corrected by a superficial use of ultrasound for ironing subcutaneous irregularities and stimulation of the so-called shrinking phenomenon (faster retraction of the skin). We recommend the thinnest SAL cannulas as well as the strict control of the aspiration process.

There were two reasons lipofilling proved to be an unsuccessful correction method. Firstly, it is hard to under-spray the scarred tissue. Secondly, injected fatty transplatate resorbs faster because scarred tissue is

Korekcija Estetskih komplikacija

Korekcija lakših estetskih nepravilnosti kao što su manja udubljenja, delovi areala koji nisu dovoljno tretirani i asimetrije mogu se korigovati uz kombinovanu upotrebu UAL i SAL metode.

Organizovani hematomi mogu se nakon više meseci od operacije smanjiti sukcijom. Kod hiperpigmentacije treba preporučiti izostanak sunčanja i solarijuma i upotrebu depigmentirajućih krema kao što je npr. Hydrochinon.

Korekcija talasastih neravnina na spoljašnjoj strani butina (lateral thigh) zahteva superficijalnu upotrebu ultrazvuka u smislu glačanja potkožnih neravnina i stimulaciju tzv. "shrinking" fenomena (brže retrakcije kože). Od SAL kanila preporučuju se najtanje kanile uz izuzetno kontrolisanu aspiraciju.

Lipofiling kao metoda korekcije može dati određena poboljšanja ali se generalno nije proslavio, jer kao prvo vrlo je teško podšpricati ožiljno tkivo a kao drugo resorpcija injektiranog masnog transplatata je brza jer je ožilj-

unperceptive background.

Certain complications, such as skin redundancy, skin looking like "puff pastry", adhesions between skin and aponeurosis, and parchment-like skin, can be eliminated only by a surgical procedure. This is the reason why a patient may be left with big, more or less visible scars. Revisions should not be performed earlier than 6 months after the primary operation.

Surgical complications

Reported, but fortunately rare surgical complications are:

- Hematoma
- Infection (general or local), very rarely reported.
- Seroma may occur after a large-volume aspiration from the abdomen area. It can be prevented by placement of a drain and applying a short ultrasound treatment in the vicinity of fascia.
- Dysesthesia.

Postoperative discomfort is individual in character and varies from person to person.

- Skin necrosis can be completely avoided by preservation of a delicate subdermal plexus from injury by aggressive treatment or excessive application of ultrasound energy.
- Fat Pulmonary embolism (observed only in isolated SAL)

Is UAL a Safe Method?

If applied correctly, UAL is a very safe method. Its specific advantage is that it results in a more beautiful and safer contour and texture of targeted areas. It is also advantageous in treatment of large-volume and fibrous areas.

no tkivo loša podloga za primanje.

Određene komplikacije, kao što su višak kože, koža izgleda lisnatog testa, srasline između kože i aponeuroze i pergament koža, moguće je eliminisati jedino hirurškim putem. Zato pacijentu ostaju doživotno veliki, manje ili više upadljivi ožiljci. Revizije treba raditi najranije 6 meseci nakon primarne operacije.

Hirurške komplikacije

Opisane, ali na sreću retke hirurške komplikacije, mogu biti:

- hematomi
- infekcija (opšta ili lokalna), vrlo je retko opisan.
- seromi se mogu javiti nakon aspiracije veće količine emulzije iz abdomena. Postavljanje aspiracionog drena i kraće vreme aplikacije ultrazvuka blizu fascije preveniraju pojavu seroma.
- dysesthesia

Postoperativni nekomfor individualnog je karaktera i varira od osobe do osobe.

- nekroza kože je komplikacija koja se totalno može izbeći štedeći osetljivi subdermalni pleksus koji može biti oštećen ili agresivnim tretmanom ili preteranom aplikacijom UZ energije.
- masna embolija pluća (opisana samo kod izolovane SAL)

Da li je UAL sigurna metoda?

Generalno UAL je vrlo sigurna metoda ako se izvodi pravilno. Kao posebne prednosti treba naglasiti dobijanje lepše i sigurnije konture i teksture tretiranih areala kao i prednosti u tretmanu voluminoznih regija i fibroznih areala.

Combined and Ancillary Procedures

Abdomen and Flanks Ultrasound Liposuction Combined with Laser - RF Horizontal Abdominoplasty

UAL of upper and lower abdomen and flanks combined with horizontal laser and RF abdominoplasty

- Importance of the tumescent technique, CO_2/ Nd:YAG laser and RF bipolar scissors in abdominoplasty.

If the subcutaneous fatty tissue and abdominal wall skin redundancy is manifested as "hanging belly" or venter pendulum, and in incidences of excessive subcutaneous fatty tissue with loose skin and striae, a combination of methods was used: UAL of the upper floor of the abdominal wall and horizontal abdominoplasty.

Since 1988, UAL is applied in reduction and remodeling of the subcutanous fatty tissue of the abdominal wall (Zocchi, 6 and Rorhich et all., 1998, 1). However, in cases of the "hanging belly" when the lowest point of the loose skin is below the abdominal fold plane, this technique did not yield satisfactory results in retraction of the skin. Therefore, if only UAL technique was used the result was loose, wrinkly skin of the lower abdominal wall.

Nor did the horizontal abdominoplasty yield good esthetic results in these indications. There was the disproportion in the ratio between subcutaneous fatty tis-

Kombinovane i dodatne procedure

Ultrazvučna liposukcija abdomena i slabina kombinovana sa laser - RF horizontalnom abdominoplastikom

UAL gornjeg i donjeg abdomena i slabina u kombinaciji sa horizontalnim laserom i RF abdominoplastikom

- Značaj tumescentne tehnike, CO_2/ Nd:YAG lasera i RF bipolarnih makaza u abdominoplastici.

Kod slučajeva viška potkožnog masnog tkiva i kože trbušnog zida sa ispoljavanjem "visećeg stomaka" zvanog *venter pendulum,* i kod pojave viška potkožnog masnog tkiva sa labavom kožom i strijama koristi se kombinacija metoda: UAL gornjeg sprata trbušnog zida i horizontalna abdominoplastika.

UAL počev od 1988. g. nalazi svoju primenu i kod smanjenja i reoblikovanja potkožnog masnog tkiva trbušnog zida (Zocchi, 6 i Rorhich et all., 1998, 1). Međutim u slučajima visećeg trbuha gde se najniža tačka viseće kože nalazi ispod ravni abdominalnog sulkusa ili pregiba, ova tehnika nije davala zadovoljavajuće rezultate po pitanju retrakcije kože pa se u tim slučajevima (kada se koristila samo UAL tehnika) dobijao rezultat opuštene, smežurane i viseće kože donjeg trbušnog zida.

Ni horizontalna abdominoplastika nije dala dobre estetske rezultate kod ovih indikacija. Primećena je disproporcija u odnosu potkožnog masnog tkiva gornjeg i do-

sue of the upper and lower abdominal wall. Combination of the horizontal and vertical abdominoplasty can achieve a good esthetic result. However, in addition to the horizontal, xyphoid also leaves a vertical scar stretching to the pubic region. This is the very reason why only the combination of these procedures (UAL technique and horizontal abdominoplasty) yields the optimal, uniform esthetic result with good contouring of the upper and lower abdominal floor with a good turgor and well-stretched skin of the whole abdominal wall.

Compared with the combination of the classic liposuction and horizontal abdominoplasty, UAL technique and horizontal abdominoplasty have at least three advantages: intraoperative bleeding and time are significantly diminished and subcutaneous fatty tissue is more uniform.

In 1987, Klein introduced tumescent technique which significantly improved liposuction results, and consequently UAL results. This technique is the integral part of the combined technique we use.

In addition, we used horizontal abdominoplasty technique together with the laser and radio-frequent surgery with the intention to maximally diminish bleeding, postoperative complications and scar reactions.

njeg trbušnog zida. Kombinacija horizontalne i vertikalne abdominoplastike može da donese dobre estetske rezultate. Međutim, uz horizontalni, ksifoid ostavlja i vertikalni ožiljak koji se prostire sve do regije pubisa. Zato samo ovakva kombinacija postupaka (UAL tehnike i horizontalne abdominoplastike) daje optimalne i ujednačene estetske rezultate kod dobrog konturiranja gornjeg i donjeg trbušnog zida sa dobrim turgorom i dobro zategnutom kožom čitavog trbušnog zida.

U poređenju sa kombinacijom klasične liposukcije i horizontalne abdominoplastike, UAL tehnika i horizontalna abdominoplastika imaju najmanje tri prednosti: krvarenje za vreme operacije i trajanje operacije su značajno smanjeni a potkožno masno tkivo je ujednačenije.

1987. godine Klein je uveo tumescentnu tehniku, što je značajno poboljšalo rezultate liposukcije, a time i rezultate UAL tehnike. Ova tehnika je sastavni deo kombinovane tehnike koju mi korstimo..

Osim toga, koristi se tehnika horizontalne abdominoplastike zajedno sa laserom i radiofrekventnom hirurgijom, sa ciljem maksimalnog smanjenja krvarenja, postoperativnih komplikacija i ožiljne reakcije.

UAL in the reconstructive surgery of breasts

Ultrasound Assisted Liposuction of breasts was described by Zocchi, Maxwell and White as particularly noted for the added benefit of skin retraction. Because the breast is prone to oncologic changes, we decided to wait for further studies delineating short- and long-term effects of the ultrasound on breast tissue.

We routinely combined UAL technique and reduction mamoplasty with the exclusive purpose of reducing lateral fullness of the thoracic cage.

UAL dojki

Ultrazvukom Assistirana Liposukcija dojki opisana je od strane Cokija (Zocchi), Meksvela (Maxwell) i Vajta (White) kao posebno atraktivna zbog bolje retrakcije kože. Iz razloga što je dojka podložna onkološkim promenama odlučili smo da sačekamo dalje rezultate i studije posebno u vezi kratkoročnih i dugoročnih efekata UZ na tkivo dojke.

Mi rutinski koristimo UAL u kombinaciji sa redukcionom mamoplastikom isključivo da bi redukovali lateralnu punoću grudnog koša.

Flap Debulking

Flaps can be efficiently narrowed with preservation of the blood supply.

Last 30 years recorded a spectacular development of reconstructive surgery with all kinds of flaps (random, stemlike, microvascular), both in view of the results and a number of institutions that adopted these techniques. One of the significant problems following placement of the flap on the recepient area is occurrence of the "bulky" flap, i.e. the flap that is fuller than its surround-

Tanjenje režnjeva

Režnjevi se mogu uspešno tanjiti uz očuvanje krvnih elemenata.

U poslednjih 30 godina zabeležen je spektakularan razvoj rekonstruktivne hirurgije svih vrsta režnjeva (nasumični, peteljkasti, mikrovaskularni), kako u pogledu rezultata, i tako i broja institucija koje su prihvatile ovu tehniku. Jedan od značajnih problema koje prate plasiranje režnja na receptivnu regiju je pojava "zadebljanog" režnja, tj. režnja koji je deblji nego okolno tkivo. Klasično






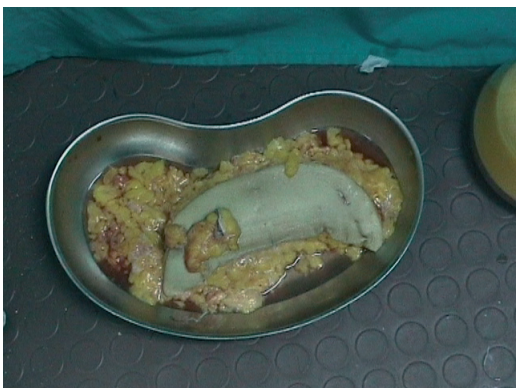

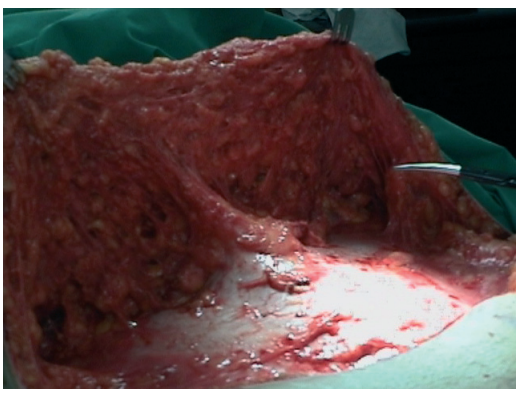

ings. Classic solution for this primarily esthetic problem was "trimming" or narrowing of the flap. It was performed in the secondary procedure, not earlier than 3 weeks after the first, primary reconstructive procedure. If appropriately indicated, UAL technique offers a suitable and simple solution for this problem while incurring minimal scarring and trauma. Namely, a surgeon well acquainted with flap vascularisation on one and UAL technique on the other hand can reduce a part of a "bulky" flap in the primary reconstructive procedure already. The remaining part can be significantly reduced in the terciary reconstruction circumstances (at least 3 weeks after the primary). "Bulky" random flaps are reduced in the primary reconstructive act by application of UAL technique and protection of the subdermal plexus, which means that the probes do not come in contact with the skin. In addition, all the flaps with direct vascularization, both stemlike and microvascualr, may be reduced in the primary reconstruction since this procedure enables a direct view at the vascular stem of the flap. In all other cases we recommend that trimming of the "bulky" flap is postponed at least 3 weeks after the primary reconstruction. The application of UAL technique in trimming the "bulky" flaps should always be performed in the postponed time interval. Only after it acquires considerable experience with this technique, should a team undertake to use it in the primary reconstruction.

rešenje za ovaj prvenstveno estetski problem je "tanjenje" režnja. Izvodi se u sekundarnom postupku, ne ranije od 3 nedelje posle prve, primarne rekonstruktivne procedure. Ukoliko je adekvatno indikovana, ultrazvučna tehnika nudi odgovarajuće i jednostavno rešenje za ovaj problem uzrokujući samo minimalne ožiljke i traume. Naime, hirurg koji dobro poznaje vaskularizaciju režnja sa jedne strane, ultrazvučnu tehniku sa druge strane, može već u prvom rekonstruktivnom postupku da značajno smanji "zadebljao" režanj. Ostatak se može smanjiti u tercijarnim okolnostima (3 nedelje posle primarnog postupka). "Zadebljali" nasumični režnjevi se tanje u primarnom rekonstruktivnom postupku primenom ultrazvučne tehnike i zaštitom subdermalnog pleksusa, što znači da sonda ne dolazi u kontakt sa kožom. Uz to, svi režnjevi sa direktnom vaskularizacijom, i peteljkasti i mikrovaskularni, mogu se tanjiti u primarnom rekonstruktivnom postupku jer ovaj postupak omogućava direktan pogled na vaskularnu peteljku režnja. U svim ostalim slučajevima preporučujemo da se tanjenje "zadebljalog" režnja odloži najmanje 3 nedelje posle primarnog postupka. Primena ultrazvučne tehnike u tanjenju "zadebljalih" režnjeva uvek treba da bude u odloženom vremenskom intervalu. Tek kada stekne znatno iskustvo u primeni ove tehnike, tim hirurga može da je koristi u primarnoj rekonstrukciji.

Before / Pre

After / Posle

Before / Pre

After / Posle

Before / Pre

After / Posle

Before / Pre

After / Posle

Before / Pre

After / Posle

Before / Pre

After / Posle

EXPERIMENTAL AND INNOVATIVE UAL

Is the use of a skin protector mandatory or not?

Effect of the ultrasound titanium solid probe used without skin protector on the soft-tissue structures during the combined UAL and horizontal abdominoplasty

The aim of this study is to establish what are the effects of the ultrasound solid probe used at 70 W, without the protector, after the aggressive UAL treatment, in the duration of 10 minutes at the soft-tissue skin and subcutaneous structures.

Material and method

We used SMEI Ultrasound "Liposculpture" apparatus, its power set at 70 W, with titanium ultrasound probe, with and without the protector. Both the abdominoplasty targeted central part of the lipocutaneous flap incision and the UAL probe targeted zone excision were made with a scalpel # 11. The surgery was performed under a high epidural anesthesia. Locally, ALC solution was infiltrated (NaCl 0.9% plus 1 adrenaline ampoule per 500 milliliters of solution) at the probe entry sites (three).

During the ultrasound liposuction stage, ultrasound probe without the protector was inserted in the central part of the abdominoplasty targeted extirpates where a 15-mm incision was previously made with a scalpel. After fan-shaped UAL of lower and upper abdomen from the direction of the lower part of the abdomen (*regia iliaca*, i.e. *pubica*) in the duration of 10 minutes, ultrasound probe without the protector was removed. Two more incisions were made in the upper part of the abdomen at the utmost lateral parts (*hypohondrica* region), through which the ultrasound probe was inserted with the use of protectors. Then the excision of the area planned for extirpation or horizontal abdominoplasty was performed.

That was followed by the skin and subcutaneous fatty tissue excision of 35x20x15 mm around the already made incision which retained its central position.

Central excised part was subjected to the histopathologic analysis. Macroscopically, after a 24-hour fixation in formalin, a circular expansion of 3.5 mm in diameter was noted on one end of 15-mm long incision at the probe entry site. A longitudinal cut of the incision revealed a gray-white change on the site of the circular extension that stretched to the height of the superficial part of the reticular dermis. At 4 mm diagonally in the

EKSPERIMENTALNA I INOVATIVNA UAL

Dali je upotreba skin protektora ultimativna ili ne?

Efekti UZ titanijumske sonde bez protektora na meko tkivne strukture u toku kombinovane UZ liposukcije (UAL) i horizontalne abdominoplastike (Horizontal Abdominoplasty)

Cilj ovog našeg rada je utvrditi efekte UZ titanijumske sonde snage 70 W, bez zaštitnika, nakon agresivnog UAL tretmana, u trajanju od 10 minuta, na mekotkivne strukture kože i potkože.

Materijal i metod

U toku rada korišćen je UZ (ultrazvučni) "Liposculpture" aparat marke "SMEI" snage podešene na 70W, sa UZ titanijumskom sondom, bez protektora i sa protektorom. Incizija centralnog dela lipokutanog režnja predviđenog za abdominoplastiku kao i ekscizija zone tretirane UAL sondom urađena je skalpelom #11. Operacija je rađena u visokoj epiduralnoj anesteziji. Lokalno na mestima (tri mesta) plasiranja sonde vršena je infiltracija sa ALC rastvorom (NaCl 0,9 % plus 1 ampula adrenalina na 500 mililitara rastvora).

U toku faze UZ liposukcije plasirana je UZ sonda, bez zaštitnika, u centralnom delu ekstirpata predviđenog za abdominoplastiku, nakon prethodno učinjene incizije skalpelom, u dužini od 15 mm. Nakon lepezasto urađene UAL gornjeg i donjeg dela abdomena, a iz pravca donjeg dela abdomena (regia *iliaca*, odnosno *pubica*), u trajanju od 10 minuta, UZ sonda, bez zaštitnika je izvađena. Potom su u gornjem delu abdomena, a sa krajnje bočnih strana (regia *hypohondrica*) načinjene još dve incizije preko kojih je uvedena ultrazvucna sonda u potkožno masno tkivo, a uz korišćenje protektora. Zatim je izvršena ekscizija predviđene regije za ekstirpaciju, odnosno horizontalnu abdominoplastiku.

Nakon toga urađena je ekscizija kože, sa potkožnim masnim tkivom dimenzija 35x20x15 mm, oko urađene incizije, tako da se incizija nalazila u centralnom delu.

Urađena je histopatološka analiza centralnog ekscidiranog dela. Makroskopski, nakon 24 časovne fiksacije u formalinu, pri jednom kraju incizije duge 15 mm uočeno je kružno proširenje, prečnika 3,5 mm, na mestu plasiranja UZ sonde. Po uzdužnom presecanju, duž učinjene incizije, na mestu kružnog proširenja promena je sivobeličaste boje sve do visine površnog dela retikularnog derma. Ukoso na odstojanju od 4 mm u supkutanom masnom tkivu uočava se promena nepravilno kružnog

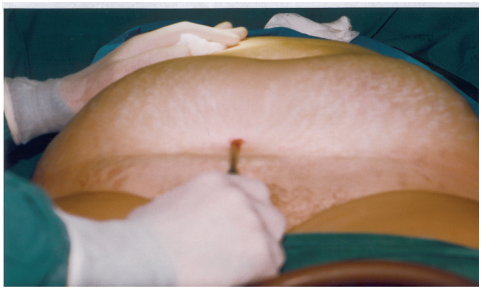

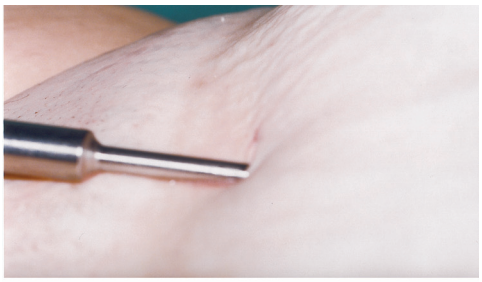

subcutaneous fatty tissue, an irregular circular brown-coloured change of 2 mm in diameter was noted. Microscopically, epidermis and papillary part of the dermis were missing at the probe entry site. The superficial part of the reticular dermis indicates coagulative type of necrosis. Deeper part of dermis and adnexal structures were preserved. Lateral parts of epidermis were preserved. On the site of macroscopically observed brown change in subcutaneous fatty tissue, fresh bleeding with the acute inflammatory response, i.e. edema was noted.

Changes in the superficial part of the skin correspond to the deep second-degree burn. They are provoked by the raised temperature. The changes in the subcutaneous fatty tissue correspond to the traumatic lesion provoked by the mechanical effect, most probably as a consequence of the needle infiltration in the infiltration stage of the Ultrasound Assisted Liposuction (UAL).

Conclusion

Use of a solid probe of the SMEI ultrasound apparatus set at the submaximal 70 W without the skin protector produces "deep second degree skin burn". Regenerative characteristics of adnexal structures in deep dermis are preserved.

Because the basal epidermal membrane is damaged, healing of the wound caused by the deep second-degree burns is possible only *per secundam*.

Discussion

The scar made by *per secundam* healing of the wound can be removed in the subsequent operative procedure

oblika, prečnika oko 2 mm, smeđe boje. Mikroskopski u predelu plasiranja sonde epiderm i papilarni deo derma nedostaju. Površni deo retikularnog derma pokazuje koagulativni tip nekroze. Duboki deo derma kao i adneksalne strukture su očuvani. Bočni delovi epiderma su očuvani. Na mestu makroskopski uočene smeđe promene u supkutanom masnom tkivu uočava se sveže krvarenje sa akutnim inflamatornim odgovorom, odnosno edemom.

Promene u površinskom delu kože odgovaraju II stepenu opekotina (*deep second-degree burn*), i izazvane su povišenom temperaturom. Promene u supkutanom masnom tkivu odgovaraju traumatskoj leziji, izazvane su mehaničkim dejstvom, a najverovatnije kao posledica dejstva infiltracione igle u infiltracionoj fazi *Ultrasound Assisted Liposuction* (UAL).

Zaključak

Korišćenje Titanijumske sonde (*solid probe*) ultrazvučnog aparata marke "SMEI" podešenog na submaksimalnih 70 W bez upotrebe protektora (*skin protektor*) izaziva "*deep second degree skin burn*" duboki drugi stepen opekotina pri čemu su regeneratorne osobine adneksalnih struktura smeštenih u dubokom dermu očuvane.

Obzirom na oštećenje bazalne membrane epiderma zarastanje rane nastale usled dubokog drugog stepena opekotina moguće je jedino *per secundam*.

Diskusije

Ožiljak nastao zarastanjem rane *per secundam* moguće je u sledećem operativnom ambulantnom zahvatu odstraniti prostom vretenastom ekscizijom i prepokriti

by a simple spindle-shaped excision and overlaid with the skin that was sutured by an intradermal stitch.

This means that the excision, targeted area does not require obligatory use of the protector since there is no deep injury of the tissue. In the areas not planned for evacuation, use of the protector in the place of entering incision of UAL probe is recommended.

Postoperative treatment

Post-operative medicational therapy is described in the heading relating to the anesthesia.

1. Post-OP Compression Garments

Post-op compression garments improve skin retraction. By micromassage, it stimulates reduction of the postoperative edema and further enhances desired effect. Superpanty long with exterior and interior reinforcements of the region above the knee, the knee, gluteal and abdominal area, is the optimal solution after treatment of problem zones such as lower abdomen, lateral, medial, and anterior side of the region above the knee and the gluteal region (fabrics manufactured by Mad-Tec Ulm and excerption from the book titled Ästhetische Chirurgie by Prof. Dr. G. Lemperle, 1999).

Based on Gasparotti's and mine idea and our patients' experience and suggestions, we have intensely worked with a team of colleagues on improvement of the Superpanty compression post-op garments in view of better compression, lifting and micromassage of the specific regions.

2. Recommended Physical Therapy after UAL

- Lymph drainage and "silhouette massage"
- Hydrotherapy
- Exterior application of ultrasound
- Regular, short exercises aimed at improvement of the problem zones muscular tone

Lymph drainage, "silhouette massage", hydrotherapy and exterior application of the ultrasound improve reduction of edema, resorption of the hematoma, if there are any, and contributes to the optimal body contour.

3. Application of medical solutions, gels and creams to improve wound healing and scar removal:

- Carrington Alloe Vera Products (wound care management):
  - Caraklenz Wound Cleanser
  - Carrasyn Wound Gel
  - Cara Smart Foam
- American Dermatological Corporation:
  - Dermatique cell renewal formula

kožom koja bi bila suturirana intradermalnim šavom.

Regija predviđena za eksciziju, ekstirpaciju ne zahteva obaveznu primenu protektora obzirom da ne dolazi do dubokih oštećenja tkiva. U regijama koje nisu predviđene za odstranjenje primena protektora na mestu ulazne incizije za UAL je preporučljiva.

Postoperativni režim

Medikamentoza post-op terapija opisana je u delu vezanom za anesteziju.

1. Postoperativna kompresivna odeća "Post-OP Compression Garmets"

Postoperativna kompresivna odeća pospešuje retrakciju kože, mikromasažom stimuliše redukciju postoperativnog edema i poboljšava željeni efekat. *Superpanty long* sa spoljašnjim i unutrašnjim pojačanjima za natkolenice, koleno glutealni i abdominalni predeo (regiju) predstavlja optimalno rešenje nakon tretmana više problem zona kao što su donji abdomen, lateralna, medijalna i anteriorna strana natkolenica i glutealna regija (materijal firme proizvođača Mad-Tec Ulm i izvod iz knjige *Ästhetische Chirurgie* Prof. Dr. G. Lemperle 1999).

Bazirano na Gasparotti-jevoj i mojoj ideji i iskustvima i predlozima pacijenata radili smo intenzivno sa timom kolega na poboljšanju *Superpanty* kompresivnog post op veša u smislu bolje kompresije, liftinga i mikromasaže specifičnih regija.

2. Preporučena fizikalna terapija nakon (UAL) ultrazvukom sistirane liposukcije

- Limfna drenaža i "siluetna masaža"
- Hidroterapija
- Eksterna aplikacija ultrazvuka
- Redovne, vremenski kratke vežbe u smislu poboljšanja tonusa mišića problem zona

Limfna drenaža, "siluetna masaža", hidroterapija i eksterna aplikcija ultrazvuka pospešuju redukciju edema, resorpciju eventualnih hematoma i doprinose optimalnoj konturi tela.

3. Aplikacija medicinskih rastvora, gela i krema u smislu boljeg i estetskijeg zarastanja rane i uklanjanja ožiljka:

- Carrington Alloe Vera Products (wound care management):
  - Caraklenz Wound Cleanser
  - Carrasyn Wound Gel
  - Cara Smart Foam
- American Dermatological Corporation:
  - Dermatique cell renewal formula

Abdominoplasty, brachioplasty and thigh reconstruction

The body sculpturing is a method of the aesthetic removal of the excessive subcutaneous fat tissue and/or skin with the aim to achieve the aesthetically acceptable results.

The body sculpture can be divided into the following categories: breast surgery, abdominal plastic surgery, sculpting of the gluteal area, hips, thighs and upper arms.

These operations can be performed in several stages, depending on the general health condition, age and body weight of the patient, or more precisely, on the mass of tissue that needs to be removed.

Standard dermo-lipectomy comprises removing of the skin and the subcutaneous fatty tissue thus achieving better results in terms of skin tightness and reduction of the fat tissue.

The majority of the patients now undergo liposuction which could be combined with the standard procedure during the same anesthetic effect or during another procedure.

Introducion of the liposuction made it possible to treat several body regions under the same anesthesia.

Abdominoplastika, brahioplastika i korekcija butina

Konturiranje tela je postupak estetske korekcije viška potkožnog masnog tkiva i/ili kože u cilju postizanja estetski prihvatljivog rezultata.

Konturiranje tela može se podeliti na: hirurgiju dojke, abdominoplastiku, korekcije glutealnog predela, bokova, butina i nadlaktica.

Ove operacije se mogu raditi u više faza zavisno od zdravstvenog stanja, uzrasta i telesne težine pacijenta, tačnije mase tkiva koju treba ukloniti.

Standardna dermolipektomija podrazumeva uklanjanje kože i potkožnog masnog tkiva i time se postiže zategnutost kože, ali i redukcija masnog tkiva.

Većina pacijentata se sada podvrgava liposukciji koja može biti kombinovana sa standardnom operacijom u istoj anesteziji ili u sledećoj operaciji.

Uvođenjem liposukcije omogućeno je da se u jednoj anesteziji uradi korekcija više regiona tela.

PROCEDURE PLANNING

Age

Long procedures should be avoided in patients older than 50 years of age. These patients should have only one procedure. The operation should not take longer than 5-6 hours. Depending on the training and experience of the staff involved, where there would be provisions available for the minimal blood loss, it is possible to operate on breasts, abdomen and hips, and the upper third of the thighs during a single procedure.

Technical characteristics

Surgery involving abdominal and breast plastics should not last longer than 3-3.5 hours.

Preoperative protocol

This is not different from the other protocols where general anesthesia is involved.

If a greater area is involved in the procedure, the patient will prioritise the aesthetic imperfections to be corrected.

If the procedure is contraindicated due to the general health condition it is required to complete the initiated procedure and then postpone the rest for another operation.

The patient should not take salicylates nor smoke for two weeks before the surgery. The patients on estrogen containing medication should stop taking them two weeks prior to the procedure due to the possibility of postoperative thrombosis/thromboembolism.

Preoperative estimation

Clinical examination of the patient is performed in standing position in order to assess the flabbiness of the skin, excess of the fatty tissue and presence of striae, scars and so called "abdominal skirt", and also in supine position with head and shoulders raised from the bed in order to assess the presence of the diastasis of *m. recti* and possible abdominal hernia.

ANESTHESIA

Abdominoplasty could be performed with general, epidural and local anesthesia, whilst brachioplasty could be performed with local anesthesia and intravenous sedation. Cephalosporin (dose 1 g) of the third generation is given intraoperatively.

Monitoring of the patient is a routine intaroperative requirement.

PLANIRANJE OPERACIJE

Starost

Treba izbegavati dugotrajne operacije kod pacijenata starijih od 50 godina. Kod ovih pacijenata treba uraditi jednu operaciju . Operacija ne teba da traje duže od 5-6 sati. Pod uslovom da je operativni tim sa iskustvom koje će obezbediti minimalni gubitak krvi, može se u jednoj operaciji uraditi operacija dojki, abdomena i bokova i gornje trećine butina.

Tehničke karakteristike

Operaciju abdominoplastike i mamoplastike treba završiti za 3-3,5 sata.

Preoperativna priprema

Ne razlikuje se od ostalih priprema za opštu anesteziju.

Ako se planira operacija više regija tela, pacijent određuje prioritet rešavanja estetskih nedostataka.

Ako opšte stanje ne dozvoljava nastavak operacije, završava se početa korekcija, a nezavršene se odlažu za sledeću operaciju.

Pacijent ne sme koristiti acetilsalicilnu kiselinu kao ni pušiti 2 nedelje pre operacije. Pacijenti koji koriste tablete koje sadrže estrogen trebaju prekinuti njihovo uzimanje 2 nedelje pre operacije zbog moguće postoperativne tromboze.

Preoperativna procena

Klinički pregled pacijenta se radi u stojećem stavu u cilju procene mlitavosti kože, viška masnog tkiva i postojanja strija, ožiljaka i prisustva "abdominalne kecelje", a u poluležećem položaju sa glavom i ramenima podignutim sa kreveta u cilju sagledavanja postojanja dijastaze rektalnih mišića ili eventualnog prisustva abdominalne hernije.

ANESTEZIJA

Abdominoplastika se može raditi u opštoj, epiduralnoj i lokalnoj anesteziji, dok se brahioplastika može uraditi u lokalnoj anesteziji sa intravenskom sedacijom. Intraoperativo teba dati 1 g cefalosporina treće generacije.

Monitoring pacijenta je rutinska intraoperativna procedura.

ABDOMINOPLASTY

Patients are most often interested for abdominoplasty if they are not satisfied with the shape and size of the abdomen, usually due to the amount of the fatty tissue, skin quality (elasticity, striae and flabbiness), surgical scars, diastasis of *m. recti* and finally there could be an abdominal hernia present, in which case the abdonimoplasty is done following the functional surgery.

Each patient is assessed individually.

Those patients who are candidates for the body sculpture could be divided in four categories, based on the skin quality.

Laser Abdominoplasty

Type I:

Irregular deposits of fat on the trunk. Skin is tight, there is no flabbiness and excess of the skin. Usually these are women under the age of 20 and they would normally undergo liposuction only.

Type II:

There are no large deposits of fatty tissue, however skin is not completely tight. Liposuction is also recommended here. Two liposuction procedures should be performed with the 6-month period between them. The quantity of the reduced fatty tissue should be carefully estimated, in order to avoid bad results.

Type III:

There are fat deposits and the skin is flabby.

These patients should have the conventional operation in order to achieve the skin tightness and the liposuction should be performed at the same time..

Type IV:

There is skin excess with minimal or no fatty deposits. Only conventional operation is performed, without liposuction.

ABDOMINOPLASTIKA

Pacijent je najčešće motivisan za abdominoplastiku ako nije zadovoljan: volumenom i oblikom trbuha, najčešće zbog količine masnog tkiva, kvalitetom kože (elastičnost, strije, opuštenost), ožiljci od operacija, postojanjem dijastaze rektus mišića i na kraju pacijent može može imati herniju abdominalnog zida, pa se u tom slučaju u sklopu funkcionalne operacije kao nastavak radi i abdominoplastika.

Svaki pacjent se procenjuje individualno.

Pacijenti koji su kandidati za konturiranje tela mogu se podeliti u 4 grupe zavisno od kvaliteta kože.

Laser Abdominoplastika

Tip I:

Nepravilni depoziti masti na trupu. Koža je zategnuta, nema mlitavosti i viška kože. To su obično žene mlađe od 20 godina i njima se radi isključivo liposukcija.

Tip II:

Nema velikih depozita masnog tkiva, ali koža nije potpuno zategnuta. I ovde se preporučuje liposukcija. Rade se dve liposukcije u razmaku 6 meseci. Mora se veoma pažljivo proceniti količina redukovanog masnog tkiva da se izbegnu loši rezultati.

Tip III:

Ima masnih depozita i koža je opuštena.

Kod ovih pacijenata je potebno uraditi konvencionalnu operaciju da bi se postigla zategnutost kože i uraditi liposukciju u istom operativnom aktu.

Tip IV:

Postoji višak kože sa minimalnim ili bez masnih depozita. Radi se samo konvencionalna operacija, bez liposukcije.

Surgical technique

Three categories of the surgical techniques are described as follows:

- vertical resections over the midline
- transversal resections
- combined vertical and transversal resections.

The techniques of the horizontal abdominoplasty are most commonly done where the suture line is suprapubic and it is hidden.

The phases of the surgery:

- making the incision suprapubically reaching over to the *anterior superior iliac spine*. This incision can be concealed by the bathing suit.
- lifting the skin flap usually by using cautery by diathermy or radiosurgical apparatus, i.e. CO_2 laser.
- excision of skin and subcutaneous tissue excess
- estimation of the abdominal recti margins with non-absorbable suture
- placing of the sutures
- forming the umbilicus in a new position
- closing the wound in two layers - absorbable sutures (such as Vicriyl/ Monocryl/ Slow Absorbable sutures) are used for subcutaneous tissue, and non-absorbable separate or intracutaneous sutures are used for skin.
- liposuction of the upper abdomen (if indicated) placing of drains, dressings and compressive postoperative stockings.

It is possible to combine abdominoplasty and hip plastics. The possibility of creating too extensively emphasized hips could be avoided by the correction of abdomen and the hips in one phase. This is recommended in patients who are Type III or Type IV.

The correction of the hips could be done with ultrasound liposuction at the end of the abdominoplasty or conventional abdominoplasty could be expanded to dermolipectomy of the hips.

The line of the incision is determined when the patient is standing up. The operation begins with patient lying on his/her front and oval excision is done from the sacral area towards cranium or about 3-6 cm from intergluteal groove. The position of the excision depends on the quantity of the sacral area skin. Suture is done in three layers. Absorbable suture 2-0 is used for the deep subcutaneous suture; Absorbable suture 3-0 is used for subdermal and intracuticular extended suture for the final closure. If additional liposuction is indicated this is done before the final closure.

Hirurška tehnika

Opisane su tri grupe hirurških tehnika za abdominoplastiku i to:

- vertikalne resekcije po srednjoj liniji
- transverzalne resekcije
- kombinovane vertikalne i transverzalne resekcije

Najčešće se primenjuju tehnike horizontalne abdominoplastike pri kojima je suturna linija suprapubično i sakrivena je.

Faze operacije:

- pravljenje incizije suprapubično koja doseže skoro do *spina iliaca ant. superior*. Ovaj rez se može sakriti kupaćim kostimom.
- podizanje kožnog režnja najčešće upotrebom termokautera ili radiohiruškog uređaja, odnosno CO_2 lasera.
- ekscizija viška kože i potkožnog tkiva
- aproksimacija ivica rektus amdominis mišića neresorptivnim koncem.
- plasiranje situacionih šavova
- formiranje pupka na novoj poziciji
- zatvaranje rane u dva sloja: potkožno tkivo se suturira resorptivnim koncima (npr. Vicryl, Monocryl, Sporo resorptivni konac), a koža sa neresorptivnim pojedinačnim ili intrakutanim šavovima (Neresorptivni konac ili Ethilon)
- liposukcija gornjeg abdomena (ako je indikovana), postavljanje drenova, zavoja i kompresivnog postoperativnog veša.

Može se kombinovati abdominoplastika i plastika bokova. Jednofaznom korekcijom abdomena i bokova se izbegava mogućnost da bokovi budu jako istaknuti nakon abdominoplastike. Ovo se preporučuje kod pacijenata tipa III i IV.

Korekcija bokova može se raditi UZ liposukcijom na kraju abdominoplastike ili konvencionalnu abdominoplastiku proširiti na dermolipektomiju bokova.

Linija incizije se određuje kada pacijent stoji. Operacija počinje sa pacijentom potrbuške i vrši se eliptična ekscizija koja počinje u sakralnom predelu kranijalno ili na 3 do 6 cm od interglutealne brazde. Položaj ekszizije zavisi od količine kože sakralnog predela. Uradi se sutura u tri sloja. Koristi se sporo resorptivni konac 2-0 za duboki potkožni šav, subdermalno pojedinačni sporo resorptivni konac 3-0 i intrakutikularni produžni šav Sporo resorptivni konac 3-0 za definitivno zatvaranje. Ako je potebna dodatna liposukcija ona se radi pre definitivnog zatvaranja.

It is the most desirable that the suture line follows the iliac crista, about 1-3 cm above or below it.

The wound is dressed and the patient is turned to his/her back. The surgery on the hips and abdominoplasty can then be completed.

The "dog's ear" must be corrected at the interface of incisions of abdominoplasty and hip plastic surgery. Undermining of the abdomen skin must not be performed too laterally.

Suturna linija je idealno da prati kristu ilijaku, oko 1-3 cm iznad ili ispod nje.

Rane se previju i pacijent okrene na leđa. Sada se dovrši plastika bokova i uradi abdominoplastika.

Mora se korigovati "pseće uvo" na spoju rezova abdominoplastike i plastike bokova. Podminiranje kože abdomena ne sme se vršiti mnogo lateralno.

"Mini" abdominoplasty

This procedure is used where there is a deformity below the umbilicus. Suprapubic excision of the skin and subcutaneous tissue is done combined with liposuction.

Mini abdominoplastika

Ova operacija se primenjuje kada je deformitet ispod pupka Radi se suprapubična ekscizija kože i potkožnog tkiva koja se kombinuje sa liposukcijom.

Reverse abdominoplasty

This could be applied for the deformity of the upper abdomen and combined with breast reduction, but this is not suitable with breast enlargement. The incisions are done just inferiorly to the breasts.

Reverzna abdominoplastika

Može se primeniti za deformitet gornjeg abdomena i kombinovati sa redukcionom mamoplastikom, ali nije pogodno da se kombinuje sa augmentacijom dojki. Rezovi se rade inframamarno.

Hips and Thigh Plastics

Dermolipectomy of the hips and thighs is done with a large oval excision along the iliac crista. The marking of the area to be reduced or to undergo liposuction should be done whilst the patient is in a standing position.

For the hip plastics the incision starts on the gluteal sulcus near the pudendal region, then it goes parallel with the labia majora about 2 cm above the medial femoral sulcus, then parallel with the inguinal ligament (2 cm below) and then it joins the incision for the hip plastic. This inguinal incision goes over the anterior superior iliac spine or few cm below it.

The zone of undermining and excision must be carefully determined and dead space should be avoided. The wound is closed in three layers - deep subcutaneous absorbable sutures with Absorbable sutures 2-0, dermal absorbable sutures with Absorbable sutures 3-0 and skin with separate non-absorbable sutures nylon 4-0. If there is skin excess from the medial side of the thigh, triangular excision should be done. This will leave a vertical scar about 5-7 cm long on the medial aspect of the thigh, which is usually well concealed.

Plastika bokova i butina

Dermolipektomija bokova i butina se radi velikom eliptičnom ekscizijom duž kriste ilijake. Obeležavanje područja koja će biti redukovana ili podvrgnuta liposukciji mora se izvršiti dok pacijent stoji.

Za plastiku butina rez počinje na glutealnom sulkusu blizu spoja sa pudendalnom regijom, zatim ide paralelno sa velikom usnom na 2 cm iznad medijalnog femoralnog sulkusa, a zatim paralelno sa ingvinalnim ligamentom 2 cm ispod njega i spaja se sa incizijom za plastiku boka. Ova ingvinalna incizija ide preko spine ilijake ant sup. ili nekoliko centimetara ispod nje.

Zona podminiranja i ekscizije mora se pažljivo odrediti i izbeći mrtvi prostor. Rana se šije se u tri sloja: duboki potkožni resorptivni šavovi, sporo resorptivnim koncem 2-0, dermalni resorptivni šavovi sporo resorptivnim koncem 3-0 i koža pojedinačnim neresorptivnim šavovima najlon 4-0. Ako postoji višak kože sa medijalne strane butine treba uraditi trouglastu eksciziju koja ostavlja vertikalni ožiljak dužine oko 5-7 cm na medijalnoj strani butine, koji je obično dobro sakriven.

POSTOPERATIVE PERIOD

Suitable hospital conditions for postoperative care are necessary in order to achieve the best results. A course of Cephalosporins of the third generation 1g

POSTOPERATIVNI TOK

Potebni su odgovarajući bolnički uslovi postoperativne nege da bi se obezbedili dobri rezultati.

U postoperativnom periodu teba nastaviti sa terapi-

should be given intravenously every 6 hours within 4-5 days of postoperative period.

Special postoperative care is not indicated as the procedure should be interrupted if the patient's intraoperative condition requires and if the "control is lost". There should be no risks for a patient who is undergoing the esthetic surgery.

Vacuum drainage is compulsory after abdominoplasty and it should be in place for at least 2-3 days or until the quantity of the drained fluid is below 40 ml.

Compression could be performed with polyethylene sponge of minimal thickness of 5 cm which is applied 48-72 hours. This is stabilized with a surgical tape and the patient wears the elastic compression belt (truss).

Lycra truss is used for the abdominoplasty and hip plastics in duration of 4 weeks.

Minimum hospital stay is three days. In cases where combined procedure is done hospital stay is longer. After two weeks they can return to their every day duties.

Moderate physical effort is allowed 8 weeks after abdominoplasty.

Patient should not expose infraumbilical area of the abdomen to the sun for 4 months as there is a risk of 2nd degree burns.

BRACHIOPLASTY

This operation reduces skin and subcutaneous tissue from medial aspect of the upper arm.

Brachioplasty is indicated in the patients who are obese and have flabby skin, in those who lost excessive amount of weight and have excess skin in that area and in underweight patients with skin excess at the medial aspect of the upper arm. This procedure should not be done in those with sever obesity and in those obese people who have very tight skin.

Triangular or oval excision might be used and this starts few centimeters above the medial epicondyle and it ends in axilla.

Suture line should be in medial brachial sulcus, as the scar is mostly concealed in that place. The patient should be warned about the length of the scar.

During the operation basilic vein and cutaneous nerves should be preserved. If the nerves are damaged they should be covered by fascia to avoid forming of the painful neurinoma. Therefore it is better to leave a small fat tissue layer on fascia in order to avoid the nerve damage. Excision should finish about 3-4 cm above the medial epicondyle.

jom cefalosporinima treće generacije u dozi od 1 g na 6 h intravenski 4-5 dana na 6 sati.

Posebna postoperativna nega uglavnom nije indikovana jer operaciju teba prekinuti ako intraoperativno stanje pacijenta to nalaže i ako se "gubi kontrola". Nikakav rizik ne bi smeo postojati za pacijenta koji se podvrgava estetskoj operaciji.

Obavezna je vakuum drenaža nakon abdominoplastike i treba da bude plasirana najmanje 2 do 3 dana ili dok količina seruma ne padne ispod 40 ml.

Kompresija se može izvesti polietilenskim sunđerom najmanje 5 cm debljine koji se primenjuje 48-72 sata. On se fiksira flasterom, a pacijent nosi elastični kompresioni pojas.

Za abdominoplastiku i bokove se primenjuje pojas od likre 4 nedelje.

Minimum hospitalizacije je tri dana, a ako je rađena kombinovana operacija ostanak u bolnici je duži. Posle dve nedelje pacijent se može vratiti svakodnevnim obavezama.

Umeren fizički napor je dozvoljen posle 8 nedelja od abdominoplastike,

Pacijent ne sme da sunča infraumbilikalni deo abdomena 4 meseca jer mogu nastati opekotine II stepena.

BRAHIOPLASTIKA

Operacijom se redukuje koža i potkožno tkivo sa medijalne strane nadlaktice.

Brahioplastika je indikovana kod pacijenata koji su gojazni i imaju mlitavu kožu, kod pacijenata koji su jako smršali, a u tom predelu je ostao višak kože i kod mršavih pacijenata koji imaju višak kože sa medijalne strane nadlaktice. Ovu operaciju ne treba raditi kod jako gojaznih osoba i kod gojaznih osoba kod kojih je koža jako zategnuta.

Može se primeniti triangularna ili elipsasta ekscizija koja počinje na nekoliko centimetara iznad medijalnog epikondila, a završava se u aksili.

Šavna linija mora biti u medijalnom brahijalnom sulkusu jer je na tom mestu ožiljak najskriveniji. Pacijent mora biti upozoren na dužinu ožiljka.

U toku operacije treba sačuvati venu baziliku i kožne nerve. Ako se nervi preseku treba ih pokriti fascijom da bi se izbeglo formiranje bolnog neurinoma. Zato je bolje u toku operacije ostaviti manji sloj masnog tkiva na fasciji da se izbegne povreda nerva. Ekscizija se treba završiti na 3-4 cm iznad medijalnog epikondila.

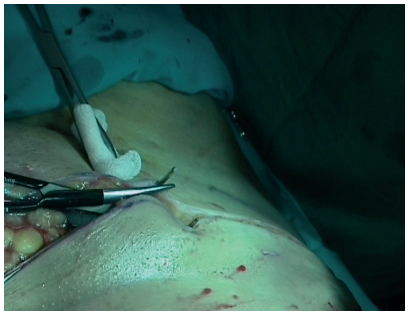

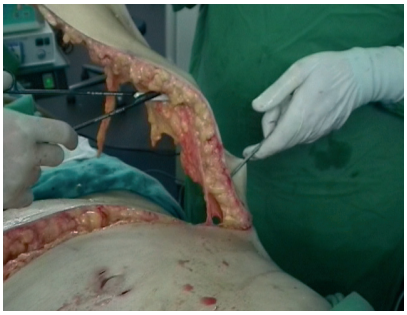
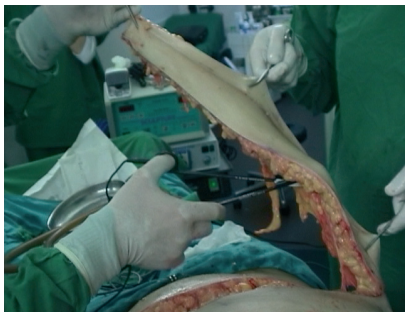
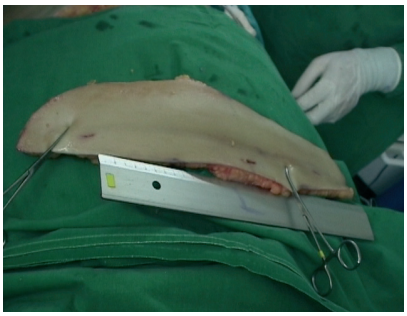
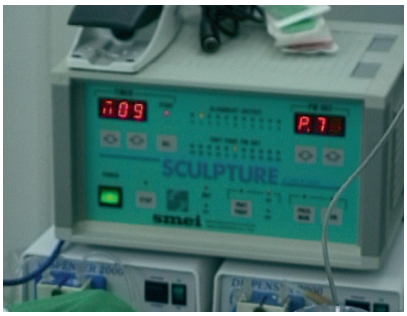

The lymph vessels are very superficial immediately above the elbow and with this excision planning the damage of these is avoided. If lymph nodes are cut, there is lymphorhea from the wound.

During surgical procedure the skin flaps should not be undermined as the amount of the loose tissue is sufficient to provide direct suture.

Postoperative period

Patient should elevate the arm on two pillows within 48 hours after the surgery.

They should avoid strong movements of the upper arm for the next 8 weeks. The scar could be pulled and hypertrophic scar could be formed (kelloid). The revision of such a scar should not be performed for about 6 months up to one year.

COMPLICATIONS

Complications in body sculpture arise with various incidence rate and they could be serious (even might cause death) or acceptable, such as partial dehiscence, necrosis of a part of the flap, haematoma seroma,

However, even these complications are very disturbing for the patient causing discomfort, lengthening of the treatment and leading to the patient's dissatisfaction.

Neposredno iznad lakta limfni sudovi su jako površni i ovakvim planiranjem ekscizije izbegava se njihovo oštećenje. Ako se preseku limfni sudovi nastaje limforeja iz rane.

U toku operativnog zahvata ne treba podminirati kožne režnjeve jer je količina rastresitog tkiva dovoljna da obezbedi direktnu suturu.

Postoperativni tok

Pacijent treba da drži posle operacije ruke podignute na dva jastuka u toku 48 sati.

Treba izbegavati snažne pokrete nadlaktica 8 nedelja posle operacije. Moguće je da se ožiljak razvuče ili da se formira hipertrofični ožiljak. Revizija takvog ožiljka ne sme se raditi 6 meseci do godinu dana.

KOMPLIKACIJE

Komplikacije u konturiranju tela nastaju sa različitom učestalošću i mogu biti teške (čak smrtni ishod) i lake: parcijalna dehiscencija, nekroza dela režnja, hematom, serom.

Ali i ove komplikacije bitno narušavaju konfor pacijenta, produžavaju lečenje i pacijenta čine nezadovoljnim.

Pulmonary embolism (PE)

It is very rare. 17 episodes of PE were described during 10,490 abdominoplasties. Manipulating of the fatty tissue during the procedure enables leakage of the lipid droplets into the circulation where enzyme lipase breaks it down into free fatty acids. Free fatty acids can initiate the coagulation pathway and lead to pulmonary thromboembolism and fat embolism.

Risk factors are smoking, age, obesity and chronic pulmonary diseases. In order to prevent PE, intravenous infusion of 300 ml 5% glucose with 5% ethyl alcohol is recommended during the operation.

Fat tissue and skin necrosis

Another difficult complication is necrosis of the skin and subcutaneous tissue or necrosis of the entire flap.

The mechanism of this complication is not clear, but it is linked with a crude operative technique, infection and presence of previous abdominal wall incisions.

If during the operation it is established that the distal part of the flap is of suspicious vitality, the operation should be converted to the wound closure in the shape of inverted T with resection of the distal part of the flap. Additional measures are IV infusion of Dextran 40 as well as oxygen therapy.

Some authors recommend to preserve a transplant of the partial thickness from the excised skin in order to be used as a biological dressing or for definitive reconstruction of the skin defect.

If the plastic surgeon is in doubt how much skin to excise, it is always better to excise less then risk necrosis formation and/or dehiscence. The patient should spend 4 days in slightly flexed position, and if he/she gets up this should be done with further flexion forward to reduce the tension of the wound.

Wound infection

Besides the usual modern surgical methods, wound infection is prevented by the use of prophylactic antibiotic therapy.

Wound dehiscence

This complication most frequently occurs due to the greater tension at the sutures and due to infection. This could be avoided with a correct estimation of the skin tension and with the use of antibiotics.

Haematoma

During the procedure the operative surface is large

Pulmonalni embolizam

Nastaje jako retko Opisano je 17 embolija na 10.490 abdominoplastika. Manipulacija masnim tkivom za vreme operacije omogućava prodor masnih kapi u cirkulaciju gde ih lipaze razlažu u slobodne masne kiseline. Slobodne masne kiseline mogu pokrenuti koagulacionu kaskadu i dovesti do pulmonalne tromboembolije i masne embolije.

Rizik faktori su pušenje, starost, preterana gojaznost i hronična plućna oboljenja. Za prevenciju pulmonalnog embolizma preporučuje se intravenska infuzija 5% glukoze sa 5% etilalkoholom u količini ukupno 300 ml za vreme operacije.

Nekroza masti i kože

Sledeća teška komplikacija je nekroza kože i potkožnog tkiva dela ili celog režnja.

Mehanizam nastanka ove komplikacije nije definisan, ali se povezuje sa grubim operativnim radom, infekcijom i postojanjem prethodnih incizija na trbušnom zidu.

Ako se intraoperativno utvrdi da je distalni deo režnja sumnjivog vitaliteta operaciju treba konvertovati na zatvaranje rane po liniji obrnutog T uz resekciju distalnog dela režnja. Pomoćne mere su infizije Dextrana 40 kao i kiseonična terapija.

Neki autori preporučuju da se sa ekscidirane kože uzme i konzervira transplantat parcijalne debljine koji se može koristiti kao biološki zavoj ili za definitivnu rekonstrukciju defekta kože.

Ako je plastični hirurg u dilemi koliko kože da ekscidira, uvek je bolje ekscidirati manje nego rizikovati da nastane nekroza i dehiscencija. Postoperativno pacijent treba 4 dana da leži u blago flektiranom položaju, a ako ustaje, da bude blago pognut napred da se redukuje tenzija na šavu.

Infekcija rane

Pored primene uobičajenih metoda savremenog hirurškog rada, infekcija rane se prevenira profilaktičkom upotrebom antibiotika.

Dehiscencija rane

Ova komplikacija najčešće nastaje zbog prevelike tenzije na šavovima, i zbog infekcije. Pravilnom procenom tenzije na operativnoj rani kao i primenom antibiotika, ova komplikacija može biti izbegnuta.

Hematom

U toku operacije operativna površina je velika i

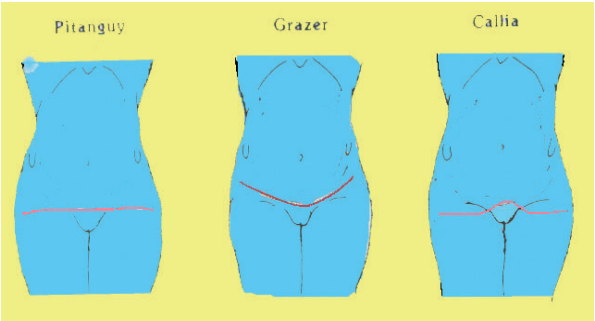
Pitanguy
Grazer
Callia

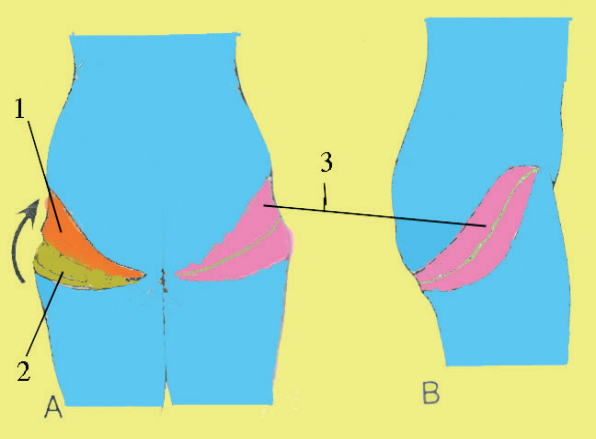
1
2
3
A
B

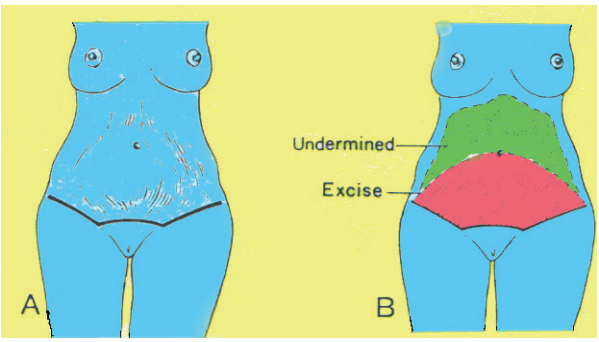
Undermined
Excise
A
B

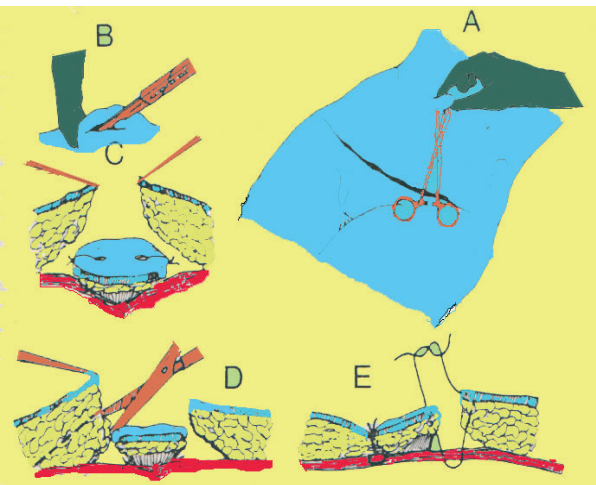
B
A
C
D
E

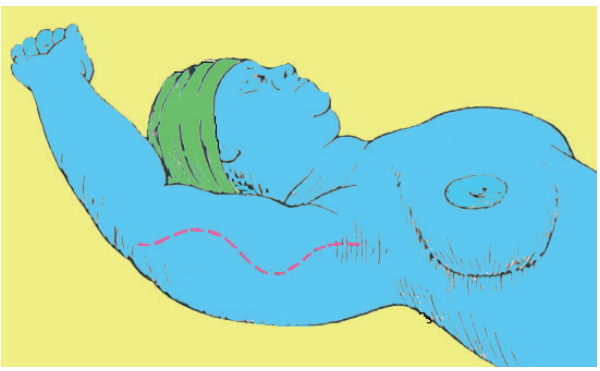

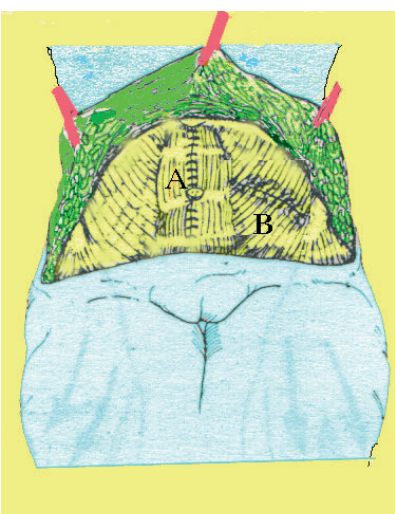
A
B



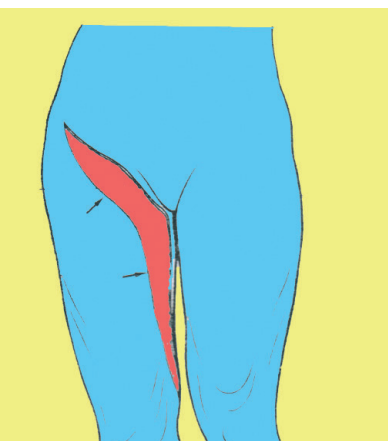

and it is possible for a haematoma to form most often during the first 48 hours. The haematoma formation is more likely if acetylsalicylic acid or other medication is used which influences thrombocytes activity and coagulation mechanism.

The formation of haematoma can also be favoured by coughing and vomiting in postoperative period. The compressive underwear and adequate vacuum drainage are important for prevention of haematoma formation.

Large haematomas must be evacuated as they can compromise the blood supply to the skin flap.

moguć je nastanak hematoma najčešće za prvih 48 sati. Formiranju hematoma pogoduje upotreba acetilsalicilne kiseline i drugih lekova koji utiču na aktivnst trombocita i koagulacioni mehanizam.

Formiranje hematoma može biti olakšano i za vreme kašlja i povraćanja u postoperativnom periodu. Za prevenciju hematoma važna je dobra kompresivna odeća i adekvatna vakum drenaža.

Veliki hematomi moraju biti evakuisani jer mogu da kompromituju vaskularizaciju kožnog režnja.

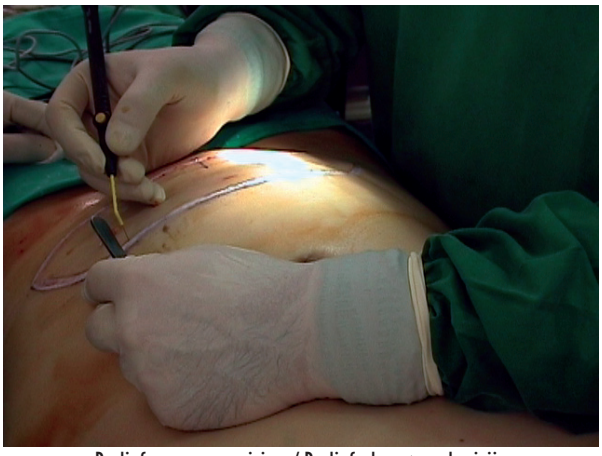

Radiofrequency excision / Radiofrekventna ekscizija

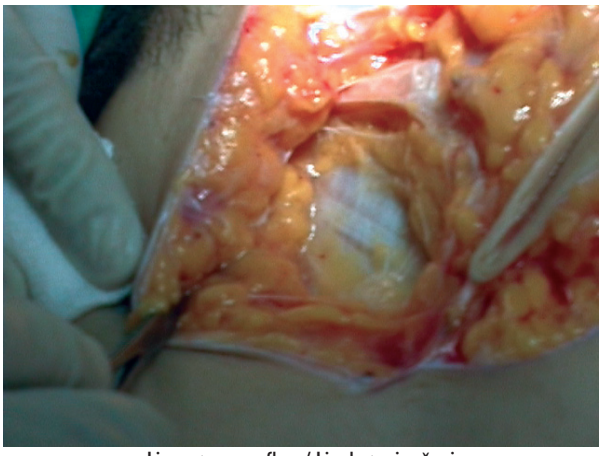

Lipocutaneous flap / Lipokutani režanj

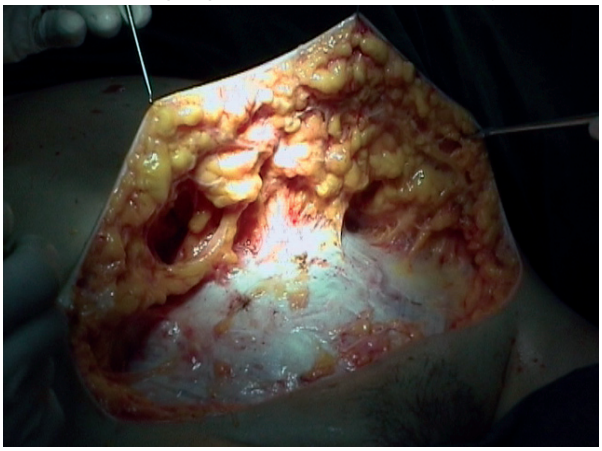

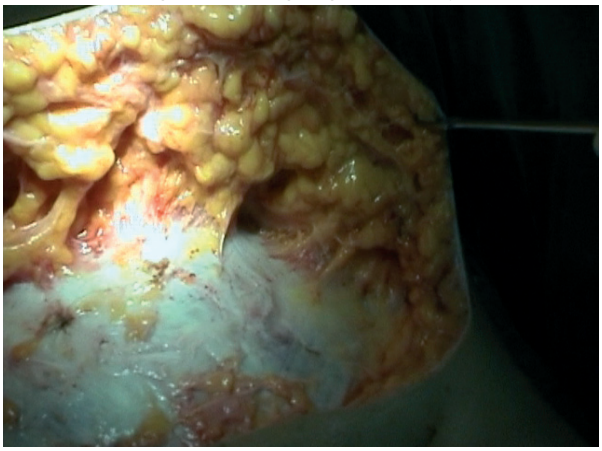

Seroma

The literature data coresponds with our experience that the seroma formation is more frequent than haemathoma. Seroma treatment comprises liquid aspiration, wearing of adequate compressive clothes and physical therapy with applying the external ultrasound. If the quantity of seroma is low, we could "wait" for seroma resorption.

Serom

Na osnovu našeg iskustva a i literature serom nastaje češće nego hematom. Tretman seroma sastoji se u aspiraciji tečnosti, nošenju adekvatne kompresivne odeće kao i u upotrebi fizikalne terapije u smislu aplikacije eksternog ultrazvuka. Ako je količina seroma mala, može se “sacekati”, ostaviti da se serom “sam” spontano resorbuje.

Scars

Postoperative scars can be crude and contracted especially in patients who had extensive striae. The contracted scar can also form around the umbilicus.

Although the secondary correction is very rarely needed, this can be done after 6 months since the first operation. The scar can be treated with triamcinolon-acetate.

With upper arm surgery the incidence of hypertrophic scar formation is higher if the tension at suture is too great.

The transverse scars made by threads could also be quite visible due to increased tension.

If the depression of the scar is detected, this should be corrected. Inadequately placed scar cannot be corrected. Therefore, the inversion of the wound edges should be avoided when closing the wound, as this gives aesthetically unacceptable outcome.

Ileus

Very rarely occurs after abdominoplasty. A nasogastric tube is inserted and patient is kept nil by mouth until peristalsis is established again.

The "Dog's ear" correction

This problem is often present with brachioplasty.

The "Dog's ear" occurs if there is disturbance in excised part width and length ratio or if the margins are uneven. This can resolve spontaneously or it can be corrected as a secondary procedure.

Ožiljci

Postoperativni ožiljci mogu biti grubi i kontrahovani pogotovo kod pacijenata koji su imali mnogo strija. Moguće je i formiranje kontrahovanog ožiljka oko umbilikusa.

Retko je potebno sekundarno korigovati ožiljak, ali to se može uraditi najranije za 6 meseci od prve operacije. Ožiljak je moguće tretirati i triamcinolon-acetatom.

Kod brahioplastike hipertrofičan ožiljak nastaje češće ako je tenzija na šavu prevelika.

Takođe mogu biti jako vidljivi poprečni ožiljci od konaca zbog velike tenzije.

Ako se nađe depresija ožiljka mora se sekundarno korigovati. Loše postavljen ožiljak se ne može korigovati. Treba pri šivenju izbeći uvlačenje ivica rane jer to daje estetski neprihvatljiv rezultat.

Ileus

Vrlo retko nastaje nakon abdominoplastike. Plasira se nazogastrična sonda i obustavlja oralni unos do uspostavljanja peristaltike.

Korekcija psećeg uva (dogy ear correction)

Problem je češće prisutan kod brahioplastike.

Pseće uvo nastaje ako je poremećen odnos širine i dužine ekscidirane elipse ili su ivice nejednake. Pseće uvo može nestati sa vremenom ili se mora sekundarno korigovati.

Anesthetic issues related to UAL & SAL

Dr. med. Gordan Malivukovic
Anesthesiologist / Anesteziolog

Anesthetic issues related to UAL & SAL

Liposuction is an optional procedure generally performed on healthy patients. Although liposuction is basically void of hazards, as a surgical procedure it is associated with certain operative and anesthetic risks. In order to minimize the risk, it is important that surgeons and anesthesiologists make a correct preoperative assessment and determine operative schedule to provide for the safe and fast recovery.

PREOPERATIVE EVALUATION

A thorough history and physical examinations is the cornerstone of the preoperative evaluation. Laboratory tests are routine and include:

- complete blood count,
- urea, and
- glychemia.

If indicated by the history and physical examination, the additional tests are made:

- electrolyte
- kreatinin
- urine examination
- milaze
- transaminaze
- bleeding duration
- coagulation
- HIV Test

Razmatranja o anesteziji vezanoj za UAL i SAL

Liposukcija je zahvat po izboru i izvodi se obično na zdravim pacijentima. Iako je zahvat u osnovi bezopasan, liposukcija je, kao i svi hirurški zahvati, povezana sa određenim operativnim i anestetičkim rizicima. Da bi se rizik smanjio na minimum važno je da hirurg i anesteziolog izvrše pravilnu preoperativnu procenu i odrede tok izvođenja zahvata kako bi se obezbedio bezbedan i brz oporavak pacijenta.

PREOPERATIVNA PROCENA

Uzimanje anamneze i fizički pregled su osnova za preoperativnu procenu. Laboratorijske analize se vrše rutinski, što podrazumeva:

- kompletnu krvnu sliku,
- ureu i
- glikemiju.

Ako se kroz anamnezu i fizički pregled ustanovi da su potrebne, uzimaju se dodatne analize:

- elektroliti,
- kreatinin,
- pregled urina,
- amilaza,
- transaminaza,
- vreme krvarenja,
- koagulacija
- HIV test

This preoperative evaluation should delineate those patients who are good candidates for liposuction and those who may need further medical evaluation.

As a rule liposuction patients have tried other means of weight reduction and a history of recent diet regimens, fads, or medications should be noted. For example, phenfluramine and phentermine, prescribed until recently ,have been associated with sudden cardiac death. Patients who have been taking these medications should see their cardiologist before the surgical procedure. Other diet medications or diuretics may also predispose liposuction patients to risk. It is recommendable to suggest to these patients to restrain from smoking, alcohol and stimulatives at least for a short time before the surgery.

Chronic medical conditions such as ischemic heart disease, diabetes and chronic obstructive pulmonary disease are thought to increase morbidity and mortality and thus are relative contraindications for liposuction. The physical examination should include measurement of vital signs, ECG, X-rays (Roentgen) of lungs, and examination of airway if necessary (if indicated by the medical history and physical examination).

Healthy patients are at low-risk. However, a complete blood count should be obtained, especially if large-volume aspiration is anticipated (removal of at least 5 liters).

Premedications

Several medications given in the preoperative period deserve comment. Sixty minutes before surgery 1 g of cefazolin (cephalosporine) is administered intravenously for protection against infection. In addition, 8 mg of dexamethasone is given intravenously 1 hour before surgery to reduce postoperative swelling.

Prophylaxis for acid aspiration syndrome is not routine except in patients with a positive information in the history. However, patients with a history of gastroesophageal reflux or similar complaints may be given 30 ml of an oral nonparticulate antacid and 10 mg of metoclopramide intravenously.

Following completion of the markings by the surgeon, the patient is given 2-7.5 mg of midazolam (dormicum) intravenously for sedation. This provides amnesia and raises the seizure threshold for local anesthetics. Parasympathicolitics (atropine) were not routinely used in premedication, regardless of the anesthesia technique.

Procena pre operacije treba da odredi koji pacijenti su dobri kandidati za liposukciju, a koji to nisu, i da li je za njih potrebna dalja medicinska procena.

Pacijenti koji žele liposukciju, obično su pokušavali pre toga da oslabe na druge načine, tako da treba saznati i za istoriju prethodne dijete, sredstva ili lekova za mršavljenje. Na primer, ako su sve do skora uzimali fenfluramine i fentermine, to bi u anesteziji moglo dovesti do iznenadnog srčanog zastoja. Pacijenti koji su uzimali ove lekove, trebali bi da pre operacije prođu odgovarajuće preglede kod svog kardiologa. I neki drugi lekovi za dijetu ili diuretici, takođe mogu dovesti u rizik pacijente za vreme liposukcije. Poželjno je sugerisati pacijentu da se makar u kratkom periodu pre intervencije odrekne navika kao što su pušenje, alkohol, stimulativna sredstva.

Mišljenja smo da hronična oboljenja, kao što je ishemija srca, dijabetes, i hronične opstruktivne pulmonalne bolesti, mogu da povećaju neuspeh i smrtnost i ista su relativna kontraindikacija za liposukciju. Fizički pregled treba da uključi merenje vitalnih funkcija, EKG, Rtg pluća, a po potrebi (ukoliko na to upućuje anamneza i fizikalni pregled) i funkcionalno ispitivanje disajnih puteva.

Zdravi pacijenti kojima se izvodi liposukcija su grupa sa niskim rizikom. Ipak, trebalo bi uraditi kompletnu krvnu sliku i navedena ispitivanja, naročito ukoliko se pretpostavlja da će se vršiti usisavanje većeg volumena (otklanjanje preko 5 litara).

Premedikacija

Nekoliko lekova koji se daju u preoperativnom toku, zaslužuju komentar. 60 minuta pre operacije daje se 1gr cefazolina intravenozno za zaštitu od infekcije. Takođe, 8mg dexamethasona daje se intravenozno na 1 sat pre operacije radi smanjenja postoperativnog edema.

Nije uobičajena profilaksa peptičkog ulkusa, sem kod pacijenata sa pozitivnim podatkom u anamnezi. Pacijenti sa istorijom gastroesofagealnog refluksa ili sličnih tegoba mogu dobiti oralno 30 ml nekog antacidnog sredstva i 10mg metoclopramida intravenozno.

Kada operater završi sa iscrtavanjem, pacijentu se daje 2-7,5 mg midazolama intravenozno za sedaciju, da se omogući amnezija i mirniji uvod u anesteziju. Parasimpatikolitike (atropin) nismo rutinski koristili u premedikaciji, bez obzira na tehniku anestezije.

RIGHT CHOICE OF ANESTHESIA

The vast majority of our patients are given a peridural or general anesthetic, although many authors report successful use of local anesthetics. Our experience shows that local anesthetics may be sufficient for limited spot reductions, but peridural and general anesthesia, or their combination ensures patient comfort during more intensive body contouring procedures.

Anesthesia technique should provide stable hemodynamics and fast recovery and minimize postoperative nausea and vomiting.

We mostly used two anesthetic techniques, peridural and general.

Peridural anesthesia was used in significantly larger number of patients. Sedation degree was individually adjusted. Depending on the range of the planned liposuction, we decided on the height of peridural catheter insertion and volume and type of the local anesthetic.

UAL under High Epidural Anesthesia

If surgery plan demanded liposuction in upper abdomen or thorax area, peridural catheter was inserted at the thoracic level, generally at Th 8-9 or Th 9-10. At this level, characteristic shape of thoracic vertebra procesus spinozus requires paraspinal (paramedial, lateral) approach and the peridural space identification technique used was hanging drop method. Since the procedure does not require motor neuron blockade, we used 1% xylocain or 0.25% bupivicaine solution, depending on duration of the surgery.

UAL under Epidural Anesthesia

If liposuction range is restricted to hips, lower pelvis and lower extremities (infraumbilically), peridural catheter was inserted at the lumbal level L 2-3, L 3-4. At this level, all peridural space identification techniques can be used in accordance with the anesthesiologist's affinity. Respecting the range of the planned liposuction, local anesthetic volume was defined for each patient individually. Absence of the skin sensibility to the mammilla level corresponds to the spinal cord block at Th 4.

Puncture level between the thoracic vertebra 9 and 10 corresponds to the spinal cord segment Th 12. When injecting the anesthetic, epidural space dilates almost evenly in the cranial and caudal direction. This practically means that it is necessary to block 16 segments of the spinal cord (8 below and 8 above the

PRAVI IZBOR ANESTEZIJE

Većina naših pacijenata primila je periduralnu ili opštu anesteziju, iako su mnogi autori dali izveštaje o uspešnom zahvatu pod lokalnom anestezijom. Naša iskustva pokazuju da lokalna anestezija može biti dovoljna kod ograničenih mesta redukcije masnog tkiva, ali periduralna i opšta anestezija, ili njihova kombinacija osiguravaju komfor u toku intenzivnijeg procesa modelovanja tela.

Tehnika anestezije treba da osigura stabilnu hemodinamiku, omogući brz oporavak i smanji na najmanju meru postoperativnu mučninu i povraćanje.

Koristili smo uglavnom dve tehnike anestezije, periduralnu i opštu.

Periduralnu anesteziju smo koristili u značajno većem broju slučajeva, sa prilagođenim stepenom sedacije svakom pacijentu. U zavisnosti od obima nameravane liposukcije, odlučivali smo se za visinu uvođenja periduralnog katetera i za volumen i vrstu lokalnog anestetika.

UAL pod gornjom epiduralnom anestezijom

U koliko je plan operacije zahtevao da se liposukcija izvodi u predelu gornjeg abdomena ili toraksa, periduralni kateter smo uvodili na torakalnom nivou, obično u visini Th 8-9 ili Th9-10. Karakterističan oblik procesus spinozusa torakalnih pršljenova na ovom nivou zahteva paraspinozni (paramedijalni, lateralni) pristup, a kao tehniku identifikacije periduralnog prostora na ovom nivou smo koristili metod viseće kapi. S obzirom da intervencija ne zahteva blok motornog neurona, koristili smo 1% rastvor xylocaina ili 0,25% bupivakaina, u zavisnosti od dužine intervencije.

UAL pod epiduralnom anestezijom

U koliko je obim liposukcije bio ograničen na kukove, malu karlicu i donje ekstremitete (infraumbilikalno), koristili smo uvođenje periduralnog katetera na lumbalnom nivou L2-3, L3-4. Na ovom nivou se mogu koristiti sve tehnike identifikacije periduralnog prostora po ličnom afinitetu anesteziologa. Pored obima nameravane liposukcije, volumen lokalnog anestetika smo prilagođavali individualno. Odsustvo kožnog senzibiliteta do nivoa mamila odgovara bloku kičmene moždine na nivou Th 4.

Nivo punkcije između grudnog pršljena 9 i 10 odgovara segmentu kičmene moždine Th 12. Prilikom ubrizgavanja anestetika u epiduralni prostor, on se širi skoro ravnomerno kranijalno i kaudalno. To praktično znači da je neophodno blokirati 16 segmenata kičmene moždine (8 ispod i 8 iznad mesta punkcije).

Apparatus "Julian" for general anesthesia / Uređaj "Julian" za opštu anesteziju

Peridural anesthesia / Periduralna anestezija

puncture site).

Different segments of the spinal cord require different amounts of anesthetic.

In lumbal part, dose for peridural anesthesia per segment is bigger because very thick lumbal spinal roots are less responsive to the anesthetic. For 1%, lidocaine dose is 1.8 to 2 ml, for 0,25% bupivicaine 1.5 to 1.7 ml per segment. In thoracic part, dose is lowered by 0.1 to 0.2 ml per segment. These doses are approximate for a young, healthy, about 175 cm tall patient. Segmental dose should be adjusted in very tall or short patients. The dose is increased or lowered by 0.1 ml per segment for each 10-cm deviation from 175 cm.

For the patients older than 40, the dose is lowered by 0.1 ml per a segment for every 10 years of age. A smaller number of our patients demanded to be conscious during the surgical procedure and others were sedated by midazolam titrated by 2 mg until the optimal individual dose was reached. Doses were in the range of 2 mg per hour to 12 mg per hour in a patient who was regularly taking benzodiazepines before the operationbecause of occasional insomnia.

Različita je količina anestetika potrebna za blokiranje različitih segmenata kičmene moždine.

U lumbalnom delu doza za periduralnu anesteziju po segmentu je veća, jer su jako debeli lumbalni spinalni korenovi manje osetljivi na anestetik. Za 1% lidokain doza se kreće 1,8 do 2 ml, za 0,25% bupivakain 1,5 do 1,7 ml po segmentu. U torakalnom delu doza se smanjuje za 0,1 do 0,2 ml po segmentu. Navedene doze su orijentacione za mlade, zdrave pacijente visine od oko 175 cm. Prilagođavanje segmentalne doze se preporučuje kod veoma visokih i niskih pacijenata. Doza se povećava ili smanjuje za 0,1 ml po segmentu za svako odstupanje od 10 cm u odnosu na 175 cm.

Za pacijente preko 40 god. doza se smanjuje za po 0,1 ml po segmentu za svakih 10 godina. Jedan manji broj naših pacijenata je zahtevao da bude svestan za sve vreme hirurške intervencije, a ostali pacijenti su dobijali sedaciju midazolamom titriranim po 2 mg do postizanja optimalne individualne doze. Ona se kretala od 2 mg na sat kod jedne pacijentkinje, do 12 mg na sat kod pacijentkinje koja je redovno preoperativno koristila benzodiazepine zbog povremenih nesanica.

General Anesthesia

Introduction into general anesthesia included intravenous induction with propophol and the appropriate level of relaxation providing good conditions for intubating and later for mechanical ventilation was ensured by Esmeron. For maintaining anesthesia, we used neurolept (DHBP and phentanil or alfetanil) with nitroxidul mixed with the oxygen in ratio 4:2. The patients who were not administered nitroxidul were given low doses of propophol in I.V. infusion. Inhalation anesthetics were not used (except izophluran in a couple of cases). In order to obtain greater comfort for performing the procedure and more safety in providing a respiratory channel, all patients were endotracheally intubed on the mechanical ventilation and muscular blockade level was followed by nerve stimulator TOF-GARD. Additional monitoring included intraoperative routine EKG, arterial pressure and pulse oximetry.

Nausea and vomiting after the operation are the most common complications following general anesthesia and a significant cause of prolonged hospital recovery and exhaustion. Liposuction patients are at low risk for postoperative nausea and vomiting.

Rod J. Rohrich records a 32% incidence of postoperative nausea and vomiting in patients undergoing liposuction alone or in combination with other procedures, which is consistent with the current reported incidence of 25 to 43% in surgical patients overall. Compared to this statistics, the patents that for liposuction purposes received peridural anesthesia, with or without sedation, had nausea in only 11% of cases. There is no significant difference regarding nausea and vomiting in the sedated and non-sedated patients under peridural anesthesia.

Intravenous administration of 0.625 mg droperidol as a prophylaxis against nausea added to the introduction to the anesthesia by propophol had shown to be effective and produce few side effects. In patients who have a history of postoperative nausea and vomiting or motion sickness, 4 mg of intravenous ondansetron may be administered at the end of the procedure to provide additional antiemetic effects.

Risk Factors for Postoperative Nausea and Vomiting

Inherent:

- age
- female gender
- history of postoperative nausea, and
- vomiting

Opsta anestezija

Uvod u opštu anesteziju smo intravenozno vršili propofolom, a postizanje relaksacije za intubaciju i kasniju mehaničku ventilaciju smo obezbeđivali esmeronom. Za održavanje anestezije smo koristili neurolept (DHBP i fentanil ili alfentanil) uz azotoksidul u mešavini sa kiseonikom u odnosu 4:2. Pacijentima koji nisu dobijali azotoksidul davali smo niske doze propofola u i.v. infuziji. Inhalacione anestetike (sem u par slučajeva izofluran) nismo koristili. Radi većeg komfora za izvođenje procedure i postizanja veće sigurnosti u obezbeđivanju disajnog puta, svi pacijenti su bili intubirani endotrahealno, na mehaničkoj ventilaciji, a stepen mišmičnog bloka smo pratili neurostimulatorom TOF-GARD. Od ostalog monitoringa praćen je intraoperativno rutinski EKG, arterijski pritisak i pulsna oksimetrija.

Mučnina i povraćanje posle operacije su najčešće komplikacije koje prate opštu anesteziju i značajan su uzrok produženog hospitalnog oporavka i iscrpljenosti pacijenta. Pacijenti za liposukciju imaju smanjen rizik od postopertivne mučnine i povraćanja.

Rod J. Rohrich navodi postotak od 32% slučajeva postoperativne mučnine i povraćanja kod pacijenata nakon liposukcije, same, ili u kombinaciji sa nekim drugih zahvatom, u poređenju sa 25 do 43% kod operisanih pacijenata uopšte. U odnosu na ovu statistiku pacijenti koji su za potrebe liposukcije primili periduralnu anesteziju, sa i bez sedacije, imali su mučninu u samo 11% slučajeva. Ne postoji signifikantna razlika između mučnine i povraćanja pacijenata u periduralnoj anesteziji koji su sedirani i koji to nisu.

Kada se protiv mučnine kao profilaksa uvodu u anesteziju propofolom doda 0.625 mg droperidola intravenozno, pokazalo se efikasnije i proizvelo je malo sporednih efekata. Kod pacijenata koji imaju istoriju postoperativne mučnine i povraćanja ili kinetoza, može se dati na kraju operacije i 4mg ondansetrona intravenozno, kako bi se potencirao antiemetički efekat droperidola.

Faktori rizika za postoperativnu mučninu i povraćanje

Endogeni:

- starost
- ženski pol
- postoperativna mučnina i
- povraćanje u anamnezi

Exogenous:

- pain
- movement
- degree of operative trauma
- inhalation anesthetics
- opioids

Postoperative nausea and vomiting incidence was greater in the patients operated on the day of arrival to our clinic than in those operated the day after arrival.

Hypothermia

Mild hypothermia (33 to 36°C) is common in liposuction patients, especially during aspiration of large volumes, and is the result of a combination of anesthesia-induced impairment of thermoregulation, exposure to a cold environment, and infiltration of cold solutions. Vasodilatation caused by simpaticus block intensifies this effect in peridural and use of inhalation anesthetics in general anesthesia. The vasodilatory effects of general anesthesia cause an increase in cutaneous heat loss and a decrease in heat production as well as a redistribution of body heat from core to periphery. Furthermore, hypothermia from heat loss to the surrounding environment is accentuated in the liposuction patient because of extensive exposure of the body surface area and the additional decrease in body temperature is caused by the wetting solution evaporation from the skin. Adverse effects of mild hypothermia during the operation include prolonged bleeding time, increased incidence of surgical wound infections, and prolonged recovery time. Keeping the patient in a warm environment preoperatively has proved to help minimize the initial 1 to 1.5°C drop in temperature during induction of anesthesia. Forced air is the most effective non-invasive warming technique. In addition, intravenous fluids and wetting solutions are warmed to body temperature.

Deep Vein Thrombosis and Pulmonary Embolism

Although liposuction patients are generally healthy, there is still an inherent risk of deep vein thrombosis and pulmonary embolism. Common risk factors in liposuction patients are age over 40 years, duration of surgery over 30 minutes, use of oral contraceptives, and obesity. The overall incidence of deep vein thrombosis in general surgery patients who have not undergone prophylaxis is 25% and of clinically significant pulmonary emboli 19%. The incidence of fatal pulmonary emboli

Endogeni:

- bol
- pokretanje
- veličina operativne traume
- inhalacioni anestetici
- opijati

Incidenca postoperativne mučnine i povraćanja je bila veća kod naših pacijenata koji su operisani istog dana po dolasku na kliniku, u odnosu na pacijente koji su operisani sutradan po dolasku.

Hipotermija

Blaga hipotermija (33-36°C) je uobičajena kod pacijenata na liposukciji, posebno kada se radi o aspiriranju velikih površina. Ona je rezultat poremećaja u termoregulaciji izazvanih induciranom anestezijom, izlaganja tela hladnoj sredini i infiltracijom hladnih rastvora. Kod periduralne anestezije dodatni efekat proizvodi vazodilatacija zbog blokade simpatikusa, a kod opšte korišćenje inhalacionih anestetika. Efekat širenja krvnih sudova kod opšte anestezije uzrokuje povećan gubitak temperature kože i pad proizvodnje toplote kao i protok telesne toplote od unutrašnjosti ka periferiji. Dalje, hipotermija izazvana gubljenjem toplote u okruženje je naglašena kod pacijenata na liposukciji jer je telo potpuno otkriveno i dolazi do dodatnog smanjenja temperature tela isparavanjem sa kože tečnosti za infiltraciju. Nepovoljni uticaji blage hipotermije u toku operacije uključuju produženo vreme krvarenja, porast broja slučajeva infekcije rana i produženo vreme oporavka. Pokazalo se da ukoliko se pacijent preoperativno drži u toplom okruženju, smanjuje se inicijalni pad temperature za 1-1,5°C u toku uvođenja u anesteziju. Topao vazduh je najefikasniji nenapadan način zagrevanja. Dodatno tome, intravenozne tečnosti i tečnosti za infiltraciju se zagrevaju do temperature tela.

Tromboza dubokih vena i plućna embolija

Iako su pacijenti za liposukciju generalno zdravi, i dalje postoji moguć rizik od tromboze dubokih vena i plućne embolije. Uobičajeni faktori rizika kod pacijenata na liposukciji su starost preko 40 godina, trajanje operacije duže od 30 minuta, upotreba oralne kontracepcije i preterana gojaznost. Prosečan broj slučajeva tromboze dubokih vena koji nisu bili podvrgnuti profilaksi, kod opšte hirurgije iznosi 25%, a klinički značajne plućne embolije 19%. Postotak smrtnosti od plućne

associated with major surgery is 1%. Reports of deep vein thrombosis in liposuction patients differ. In Teimourian and Rogers' 1989 survey of 75,691 major liposuction procedures, the incidence of deep vein thrombosis and pulmonary embolism was 33.1/100,000 and 11.9/100,000, respectively, although others have reported an incidence of zero.

Apart form prophylactic measures, different incidence of these complications should be sought in the liposuction technique. Although there are no precise data in the literature, our opinion is that the risk involved in ultrasound-assisted liposuction is far smaller than in classic liposuction.

Most authors consider the risk of deep vein thrombosis and pulmonary embolism to warrant prophylactic treatment. Low-dose perioperative heparin has been associated with an increase in postoperative bleeding and wound hematoma. We prefer to use a combination of compression stockings and intermittent pneumatic compression boots, which have proved to reduce the incidence of deep vein thrombosis as effectively as subcutaneous heparin (approximate incidence of 5%). The stockings and boots should be placed preoperatively and may be temporarily removed intraoperatively for suctioning calves and knees. With this method of prophylaxis and early postoperative ambulation, no cases of deep vein thrombosis or pulmonary embolism have been clinically evident in liposuction patients.

Risk Factors for Deep Vein Thrombosis

STASIS
- right ventricular failure
- arrhythmia absoluta
- age over 40 years
- duration of surgery longer than 30 minutes
- prolonged immobility

ALTERED COAGULABILITY:
- deficiency of antithrombin II, protein C, or protein S
- malignant disease

VASCULAR INJURY
- prior venous vein thrombosis
- deep venous valvular incompetence

PATIENT POSITIONING

Patients are positioned to provide optimal surgical exposure.

Supine position provides optimal exposure for vast majority of surgical procedures and at the same time has minimal effects on the physiology of the patient.

embolije kod složenih operacija je 1%. Izveštaji o venskoj trombozi kod liposukcije se razlikuju. Izveštaj Teimourian-a i Rogers-a iz 1989. govori o izvedenih 75.691 velikih zahvata liposukcije, gde su slučajevi venske tromboze 33.1/100.000, i plućne embolije 11.9/100.000, dok su drugi Izveštaji o takvim slučajevima nula.

Pored profilaktičkih mera, različitu incidencu ovih komplikacija treba tražiti i u tehnici liposukcije. Iako nisu u literaturi dati precizni podaci, naše je mišljenje da je rizik daleko manji kod liposukcija izvođenih ultrazvučnom metodom, u odnosu na klasičnu liposukciju.

Većina autora smatra rizik od tromboze dubokih vena i plućne embolije imperativom za profilaktički tretman. Niske doze heparina preoperativno povezuju se sa porastom postoperativnog krvarenja i hematomima rana. Radije koristimo kombinaciju elastičnih čarapa i midera (garments) i povremeno čizme sa pneumatskim pritiskom, što se pokazalo da smanjuje broj slučajeva tromboze dubokih vena jednako efikasno kao i heparin dat potkožno (otprilike 5% slučajeva). Čarape i čizme treba navući preoperativno i mogu se privremeno skidati u toku operacije za aspiraciju oko kolena i članaka. Uz korišćenje navedene profilaktičke metode i ranog postoperativnog ustajanja, nije klinički zabeležen ni jedan slučaj tromboze dubokih vena ili plućne embolije kod pacijenata na kojima je izvedena liposukcija.

Faktori rizika za trombozu dubokih vena

ZASTOJ U KRVOTOKU:
- mane desne komore
- arrythmia absoluta
- starost preko 40 godina
- trajanje operacije preko 30 minuta
- produžena imobilnost

PROMENE KOAGULACIJE:
- manjak antitrombina II, proteina C ili proteina S
- maligna oboljenja

VASKULARNE LEZIJE:
- ranija venska tromboza
- nepravilnost zalistaka dubokih vena

POLOŽAJ PACIJENTA

Pacijenta treba tako postaviti kako bi se omogućilo najpovoljnije izvođenje zahvata.

Položaj na leđima omogućava uslove za najveći broj operativnih procedura, a ujedno i najmanje remeti fiziologiju pacijenta. Početak opšte endotrahealne anestezije

Beginning of general endotracheal anesthesia involves this position for endotracheal intubing. After controlling the airway and ET tubus position, the patient is kept in the same or moved to a different position if so desired.

Special care must be taken to prevent injury to the brachial plexus and ulnar nerve. Proper patient positioning with upper extremities padded and abducted less than 90 degrees is important. The arms should be flexed at elbows, their ulnar side extended on well-padded arm boards. In daily practice, this is often the obligation of insufficiently trained personnel (technicians, paramedics) and, since immediately before the surgery the anesthesiologist is preoccupied with controlling the anesthetic device, correct positioning of the monitoring, control of the patient's vital values and induction of anesthesia, do not get due attention.

The patient's hips and knees (if the procedure does not strictly require otherwise) should be flexed 15 degrees by placing a soft padded pillows under the knees. This position improves venous return to lower hollow veins and reduces abdominal wall tensions. The patient's legs must remain uncrossed with the heels padded.

Turning the patient into and from the prone position requires careful planning and sufficient operating room personnel. While the patient is being turned, the anesthesiologist must stabilize the patient's head, minimize movement of the cervical spine and ensure proper placement of the endotracheal tube. Positioning should proceed slowly to allow adequate time to minimize cardiovascular variations. Immediately after the turning, endotracheal tube position should be rechecked and fixed to prevent any further movements.

Gynecologic position is characterized by increased

podrazumeva ovaj položaj za izvođenje endotrahealne intubacije, a zatim se po kontroli disajnog puta i položaja ET tubusa pacijent ili zadržava u istom, ili premešta u drugi, željeni položaj.

Posebnu pažnju treba posvetiti prevenciji povrede brahijalnog pleksusa i ulnarnog nerva. To podrazumeva položaj nadlaktica na obloženom specijalnom držaču, sa abdukcijom manjom od 90 stepeni. Podlaktice treba da su sasvim blago savijene u laktu, oslonjene ulnarnom stranom na meko tapaciranu oblogu držača. Kako je za ovaj detalj u svakodnevnoj praksi obično zaduženo nedovoljno stručno osoblje (tehničari, bolničari) i kako je pred samu intervenciju anesteziolog usmeren na kontrolu aparata za anesteziju, pravilno postavljanje monitoringa, kontrolu vitalnih vrednosti pacijenta i uvod u anesteziju, ovome se ne poklanja dužna pažnja.

Kukovi i kolena pacijenta (ukoliko operacija striktno ne zahteva drugačije) treba da budu savijeni pod uglom od 15 stepeni, tako što se pod kolena postave meko tapacirani jastuci. Ovakav postupak olakšava vensko vraćanje u donje šuplje vene i smanjuje pritisak u trbušnom zidu. Potkolenice ne smeju biti prekrštene, a pete moraju biti poduprte.

Preokretanje pacijenta u bočni položaj, ili položaj potrbuške zahteva pažljivo planiranje i dovoljno osoblja u operativnoj sali. U toku manevra anesteziolog mora pažljivo da drži glavu pacijenta, da obezbedi minimalno pomeranje u vratnom delu kičme i obezbedi dovoljno prostora za endotrahealni tubus. Promenu položaja treba izvesti lagano, da bi se omogućilo minimalizovanje varijacija kardiovaskularnog sistema. Neophodno je neposredno posle ovog manevra ponovo proveriti položaj tubusa i fiksirajući ga prevenirati njegovo naknadno pomeranje.

blood flow from lower extremities, increase in average arterial pressure and shock and minute volume. Due to the increased amount of blood in the lungs and the cranial position of the diaphragm (abdominal organs pressure), lung capacity is lower than in the prone position.

Trendelemburg's position was introduced to the clinical practice already in 1860 for urology surgery purposes. Today this position allows a certain number of esthetic surgical procedures. This position is characterized by favoring venous return. Therefore, it can be of use in certain cases of hypovolemia. Negative aspect relates to the respiratory system where additional movement of diaphragm in the cranial direction induced by the gravitation effect on the abdominal organs is observed. This effect is particularly evident in patient subjected to general anesthesia with muscular relaxation and artificial ventilation. In a customary prone position in general anesthesia cranial movement of diaphragm and consequential functional residual capacity (FRC) is caused by the abdominal organs pressure and loss in diaphragm tone. In the postoperative period, this reflects on ventilation function of lungs and significant reduction of respiratory volumes, capacities and functional tests (FVC, FEV1, VCIN, PEF, MEF, PIF, MIF) are observed. This change is especially significant in older population with closing volume disproportion (volume of small airways closing) and FRC with consequential microatelectases (absorption atelectases). In certain patients, one must consider that this position induces increase in intracranial and intraocular pressure.

Anti-Trendelemburg's position in physiological sense represents quite the opposite set of effects. Respiratory system functions in somewhat more favorable conditions (lowered pressure of abdominal organs on diaphragm, lowered breathing activity, decreased effect on lung compliance and breathing resistance, etc.). Lowered preload reduces ejection fraction and total minute cardiac volume. Decreased cardiac output (CO) is manifested as lowered middle arterial pressure and minute volume in healthy patients is mostly compensated by increasing cardiac frequency and reflexive vasoconstriction (may be omitted under anesthesia and other intraoperatively used medications). Venous stasis in the legs may be significant in patients with trombophlebitis in the history. Therefore, premedications should prevent possible complications (elastic dressing, anticoagulants).

Lateral Decubitis Position causes characteristic changes in ventilation-perfusion ratio in lungs. In the part of lung hemithorax on which the patient is lying, the perfusion is better. Ventilation degree depends on the type

Ginekološki položaj karakteriše povećan dotok krvi iz donjih ekstremiteta sa povećanjem srednjeg arterijskog pritiska i udarnog i minutnog volumena. Plućni kapaciteti su smanjeni zbog povećane količine krvi u plućima, kao i zbog kranijalnijeg položaja dijafragme (pritisak abdominalnih organa) u odnosu na ležeći položaj na stomaku.

Trendelemburgov položaj je u kliničku praksu uveden još 1860. godine za potrebe urloških operacija. Danas ovaj položaj omogućava i jedan broj operacije u plastičnoj hirurgiji. Karakteristično je da ovaj položaj favorizuje venski povraćaj, pa može biti korisan u nekim slučajevima hipovolemije. Negativni aspekt se odnosi na respiratorni sistem gde se uočava dodatno pomeranje dijafragme u kranijalnom smeru pod dejstvom gravitacije na abdominalne organe. Efekat je posebno izražen kod pacijenata koji su podvrgnuti opštoj anesteziji sa mišićnom relaksacijom i arteficijalnom ventilacijom. I u uobičajenom ležećem položaju u opštoj anesteziji dolazi pod dejstvom abdominalnih organa i gubitka tonusa dijafragme do navedenog kranijalnog pomeranja dijafragme, sa posledičnim smanjenjem funkcionalnog rezidualnog kapaciteta (FRC). Ovo se u postoperativnom periodu odražava na ventilacionu funkciju pluća gde je uočeno signifikantno smanjenje respiratornih volumena, kapaciteta i funkcionalnih testova (FVC, FEV1, VCIN, PEF, MEF, PIF, MIF). Promena je posebno značajna kod starije populacije gde već postoji disproporcija klouzing volumena (volumen zatvaranja malih disajnih puteva) i FRC i gde posledično nastaju mikroatelektaze (apsorpcione atelektaze). Kod određenih pacijenata treba imati u vidu i da ovaj položaj dovodi do povećanja intrakranijalnog i intraokularnog pritiska.

Anti-Trendelemburgov položaj predstavlja u fiziološkom smislu upravo suprotan skup uticaja. Respiratorni sistem funkcioniše u nešto povoljnijim uslovima (smanjen pritisak abdominalnih organa na dijafragmu, smanjen disajni rad, manji uticaj na komplijansu pluća i disajni otpor i td...). Smanjen priliv krvi u desno srce (preload) smanjuje ejekcionu frakciju i ukupni minutni volumen srca. Smanjeni kardijak output (CO) se manifestuje smanjenim srednjim arterijskim pritiskom, a minutni volumen se kod zdravih pacijenata uglavnom kompenzuje povećanjem srčane frekvencije i refleksnom vazokonstrikcijom (može i izostati pod dejstvom anestezije i drugih lekova koji se intraoperativno koriste). Venska staza u nogama može biti od značaja kod pacijenata sa tromboflebitom u anamnezi, pa treba u premedikaciji prevenirati moguće komplikacije (elastični zavoj, antikoagulansi).

Bočni položaj dovodi do karakteristične promene ventilaciono-perfuzionog odnosa u plućima. U delu pluća hemitoraksa na kojim pacijent leži postoji bolja per-

of anesthesia. In general anesthesia with muscular relaxation, upper lung wing is better ventilated and this causes impairment in ventilation-perfusion ratio. In spontaneous breathing (spinal, peridural anesthesia), this impairment is far less distinct since the diaphragm maintains its tone. In addition, greater "twist" of the diaphragm dome from the lower side and consequently, its greater excursions are responsible for better ventilation of lower lung wing, which disturbs the V/Q ratio. In view of the circulation, this position is specific because it enables occlusion of lower hollow vein. This occurrence lowers blood inflow into the heart and minute volume, causing middle arterial pressure fall. This change can be dramatic in right lateral decubitis position since the exteriour pressure kava inferior vein may be pressured exteriourly and if the complication is not timely noted, cardiac arrest.

Prone position Patient lies on chest with slightly raised torso and extended legs slightly flexed in knees and hips. Arms are flexed in elbows, extended beside the body with palms turned downwards on the operation table handles, parallel to the patient's head. Torso and extremities should be padded with smooth fabrics or plastic foam. Ribbed material will leave depressions on the patient's skin. The ventral torso is usually supported with two lateral longitudinal rolls (bolsters) from the axilla to the iliac crest. The shoulder must be supported to prevent subluxation of the glenohumeral joint. These supports should not cross the clavicle or acromioclavicular joint to avoid compressing the subclavian neurovascular bundle. Wrist pulses should be checked after positioning the patient's arms. A soft hip roll is also placed under the iliac crests. This protects the iliac crest pressure points and raises the hips off the table to alleviate surgical intervention in proctology, provide access for suctioning the flanks and thighs. The legs are flexed 30 degrees at the knees and protected with pillows at the knees and ankles. The arms are extended on well-padded arm boards parallel to the long axis of the table and placed ventral to the transverse axis of the shoulders. Hyperabduction will place stress on the anterior capsule of the shoulder joint and will subject the patient to injury of the brachial plexus. The elbows are covered with soft pads for protection of bony prominences and the ulnar nerve. If the head is rotated to one side, the downside ear should be checked to make sure it is not resting in a bent position to avoid cartilaginous damage that could cause (sometimes permanent) disfigurement. Otherwise, the head and cervical spine should be placed in a neutral position without undue cervical flexion or extension.

fuzija. Stepen ventilacije zavisi od tipa anestezije. U opštoj anesteziji uz mišićnu relaksaciju se bolje ventilira gornje plućno krilo, pa dolazi do poremećaja ventilacionoperfuzionog odnosa. Pri spontanom disanju (spinalna, periduralna anestezija) ovaj poremećaj je daleko manje izražen jer dijafragma zadržava svoj tonus, a zahvaljujući većoj "zakrivljenosti" kupole dijafragme sa donje strane i posledično većim ekskurzijama koje ona zahvaljujući tome izvodi, bolje se ventilira donje plućno krilo, pa se manje remeti V/Q odnos. U odnosu na cirkulaciju specifičnost ovog položaja se odnosi na mogućnost onkluzije donje šuplje vene. Ova pojava smanjuje priliv krvi u srce i minutni volumen dovodeći do pada srednjeg arterijskog pritiska. Ova promena može biti dramatična u desnom bočnom položaju gde može doći do spoljnog pritiska na venu kave inferior, a ako se komplikacija ne uoči na vreme i do cardiac arest-a.

Kod položaja potrbuške pacijent leži na trbuhu sa blago izdignutim trupom i sa ispruženim nogama koje su u kolenima i kukovima blago savijene. Ruke treba da su savijene u laktovima, ispružene pored tela i sa dlanovima položenim na dole na držačima operacionog stola paralelno sa glavom pacijenta. Trup i ekstremiteti treba da budu poduprti mekim platnom, plastičnom penom ili sunđerom. Rebrasti materijali će ostaviti udubljena na koži pacijenta. Trbušni deo trupa se obično podupire sa dva bočna uzdužna valjka (podupirača) od pazuha do bedrenog grebena. Ramena se moraju podupreti kako bi se sprečila subluksacija glenohumeralnog zgloba.Ovi podupirači ne smeju da se ukrste preko klavikula ili zgloba lopatice i klavikule da ne bi došlo do kompresije subneurovaskularnog snopa pod klavikulom. *A. radialis* i *A. ulnaris* treba proveravati nakon pozicioniranja ruku pacijenta. Mek valjak za kuk postavlja se ispod bedrenog grebena. Ovo štiti tačke pritiska na grebenu i odiže kukove od stola čime se olakšavaju hirurške intervencije u proktologiji, kao i omogućio pristup slabinama i bedrima. Noge su savijena u kolenima pod uglom od 30 stepeni i zaštićene jastucima na kolenima i člancima. Ruke su ispružene na dobro postavljenim ("tapaciranim") držačima za ruke, paralelno sa dužnom osom stola i postavljene obrnuto na transverzalnu osu ramena. Preterano odmicanje uzrokovalo bi stres u kapsulii ramenog zgloba i moglo bi uzrokovati da pacijenat povredi brahijalni pleksus. Laktovi su pokriveni mekim oblogama kako bi se sprečila dispozicija kostiju i oštećenje ulnarnog nerva. Ako bi se glava okrenula na stranu, donje uvo treba proveriti kako bi bili sigurni da ne leži u položaju koji bi doveo do oštećenja hrskavice (ponekad trajnog). Inače, glava i vrat larinksa trebaju biti tako postavljeni da njihov položaj ne dovodi do preteranog savijanja ili istezanja. Cervikalni

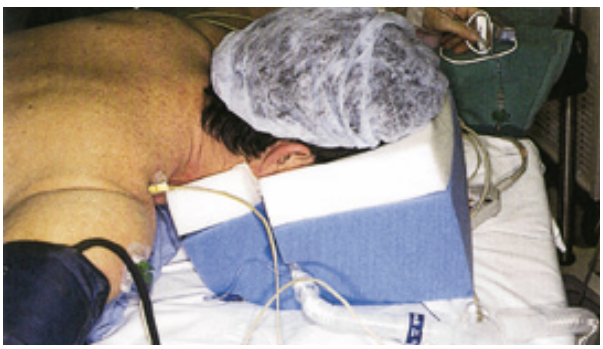

Ocular trauma resulting from prone positioning has been reported, including corneal abrasions, periorbital edema, and even blindness. Using an ocular lubricant and taping the eyes closed prior to positional changes will provide sufficient protection. Periorbital and conjunctival edema may appear formidable, but this gravity-related localized accumulation of fluid is self-resolving and has not proved to cause significant harm to soft tissues. Postoperative ischemic optic neuropathy related to prone positioning has been reported. It has been attributed to increased intraocular pressure caused by external pressure on the globe and decreased perfusion of the retinal vascular bed. Access to the patient's eyes should be unencumbered so frequent monitoring can be easily performed.

Adequate placement of ventral supports is crucial for prevention of postoperative pain and soft tissue injury in patients with large breasts. Clinical studies have shown that patients whose breasts are positioned medially with the nipples protected rarely have postoperative breast discomfort. Patients who have had breast augmentation and those with smaller breasts require special protection. These patients have the least breast tenderness postoperatively when a stack of one to two pillows is placed across the chest for ventral support rather than using longitudinal rolls.

Prevention of pressure necrosis of skin overlying bony prominences requires special attention, especially

deo kičme treba da zauzima neutralni položaj.

Postoje izveštaji o povredama oka kao posledica položaja potrbuške, a oni uključuju abraziju rožnjače, periorbitalni edem, pa čak i slepilo. Ako se koristi sredstvo za zaštitu vlažnosti oka i oči se drže zatvorene (zalepljene trakom) pre promene položaja, može se postići dovoljna zaštita. Periobitalni i konjuktivalni edemi mogu se pojaviti u različitim oblicima, ali ova očna tečnost koja se akumulirala pod uticajem gravitacije je samorastvorljiva i nije se pokazala uzročnikom ozbiljnijeg ozleđivanja mekog tkiva. U izveštajima se navodi i postoperativna ishemična neuropatija uzrokovana položajem nauzak. Ona se pripisuje povećanom očnom pritisku izazvanom spoljnim pritiskom na jabučicu oka i smanjenim ispiranjem retinalnog vaskularnog ležišta. Pristup očima pacijenta ne sme biti ometen tako da se mogu stalno kontrolisati.

Adekvatno polaganje ventralnih podupirača je od krucijalnog značaja kod prevencije postoperativnog bola i ozleda mekog tkiva kod pacijenata koji imaju velike grudi. Kliničke studije su pokazale da pacijenti čije su grudi bile postavljene ka sredini, sa zaštićenim bradavicama, retko imaju postoperativne tegobe sa grudima. Pacijenti koji su radili povećanje grudi i oni sa malim zahtevaju posebnu zaštitu. Kod ovakvih pacijenata postoperativne tegobe su smanjene ako se postavi jedno ili dva jastučeta preko grudi kao ventralnih podupirača umesto uzdužnih valjaka.

Prevencija od nekroze kože kada ispupčenja kostiju

when a patient is immobile for extended periods. The patient in the prone position is subjected to pressure changes of the forehead, malar areas, iliac crests, and bony prominences of the arms and legs. In addition, the female breasts and male genitals are areas that require protection to prevent soft tissue injury and postoperative discomfort. Full-body gel pad mattress may be of use. Other acceptable options are egg crate, water, and inflatable mattresses.

Changes in central nervous system may occur with the change of cerebral blood flow during rotation of the head. The anesthesiologist should keep in mind that rotation of the head might impair flow through vertebralis and drainage from jugular veins. When the patient is in prone position, dilation of thorax cage to provide normal breathing requires special care. This should be kept in mind when adjusting parameters on the apparatus for artificial ventilation in anesthesia and in following spontaneous ventilation when spinal and peridural blockade was performed under sedation. Restricted movement of the thorocal cage and cranial dislocation of diaphragm reflect on the restricted upward and downward movement of diaphragm. If the patient is not correctly positioned, air pressure in upper airways and changes in ventilation/perfusion may affect breathing and oxygenation. Correctly positioned rolls from the clavicle to iliac crest alleviate pressure of abdominal organs on diaphragm as well as exchange in lungs. In the prone position, ventilation by positive pressure may also have adverse effects.

Changes in the cardiovascular system in this position may reflect on pressure in the abdomen and on lower hollow vein with the effects similar to those in the lateral decubitis position. Positive ventilation pressure effects may worsen these pathologic changes. Correct positioning of the patient with the supports releasing the abdomen alleviate venous return in the heart and ventilation exchange in the lungs.

Under anesthesia, the patient affected by the muscular relaxants does not have protective muscular tone and cannot react on discomfort caused by the position he would not bear if he were awake. Accidental stretching or squeezing of the nerve may occur. Most frequently injured are peroneal nerve and brachial plexus, particularly its ulnar and radial branches. Peroneal nerve is commonly protected by carefully supporting the knees. Brachial nerve injuries can be avoided by positioning upper extremities at less than 90 degrees to eschew direct pressure or bruising of the clavicle on the first rib.

Paying attention to these details may seem effortful

pritiskaju kožu, zahteva posebnu pažnju, a naročito kada je pacijent nepokretan duže vreme na operacionom stolu. Pacijent u položaju potrbuške je podložan promenama pritiskanja na čelu, jagodičnim oblastima, bedrenom grebenu i koštanim ispupčenjima na rukama i nogama. Pored toga, ženske grudi i muške genitalije su oblasti koje zahtevaju zaštitu radi prevencije povreda mekog tkiva i postoperativne nelagode. Od koristi mogu biti dušeci tapacirani želatinastom masom. Druge prihvatljive opcije su kartoni za jaja, voda i dušeci na naduvavanje.

Promene u centralnom nervnom sistemu mogu se desiti kada se cerebralni protok krvi promeni u toku rotacije glave. Anesteziolog treba da ima na umu da rotacija glave može ometati tok kroz arteriju vertebralis, kao i drenažu iz jugularnih vena. Širenje grudnog koša radi normalnog disanja zahteva posebnu pažnju u položaju kada pacijent leži potrbuške. To treba uzeti u obzir prilikom postavljanja parametara na aparatu za arteficijalnu ventilaciju u anesteziji, kao i pri praćenju spontane ventilacije ukoliko je izveden spinalni ili periduralni blok uz sedaciju. Ograničeno kretanje grudnog koša i kranijalno izmeštena dijafragma odražavaju se ograničenim kretanjem dijafragme nagore i nadole. Ukoliko pacijent u ovom položaju nije dobro postavljen, pritisak vazduha u gornjim disajnim putevima i promene vantilacije/perfuzije mogu uticati na disanje i oksigenaciju. Pravilno postavljeni valjci za telo od klavikule do ilijačne spine olakšavaju negativno dejstvo pritiska abdominalnih organa na dijafragmu i olakšavaju razmenu u plućima. Ventilacija pozitivnim pritiskom takođe može izazvati nepoželjne uticaje na disanje u položaju potrbuške.

Promene u kardiovaskularnom sistemu u ovom položaju se mogu ogledati u pritisku koji abdomen trpi i pritisku na donju šuplju venu sa efektima kao u desnom bočnom položaju. Uticaji pozitivnog pritiska ventilacije mogu pogoršati ove patofiziološke promene. Pravilno postavljanje pacijenta sa podupiračima tela koji oslobađaju abdomen olakšava venski povraćaj u srce i razmenu ventilacije u plućima.

Anesteziran pacijent pod dejstvom mišićnih relaksanata nema zaštitni mišićni tonus i ne može reagovati na nelagodnost zbog zahtevanog položaja koji ne bi mogao podneti da je budan. Može se dogoditi slučajno istezanje ili pritiskivanje nerava. Najčešće su ozlede peronealnog nerva i brahijalnog pleksusa, posebno njegovih ulnarnih i radijalnih grana. Obično se peronealni nerv može zaštititi u položaju sa kolenima pažljivo poduprtim. Oštećenja brahijalnog pleksusa mogu se sprečiti postavljanjem gornjih ekstremiteta u položaj pod uglom manjim od 90 stepeni i tako izbeći direktan pritisak ili nagnječenje klavikule na prvo rebro.

and unnecessary; such problems in view of all the demands placed before the anesthesiologists today may seem marginal and trivial. Nevertheless, long years of clinical practice have shown that many patients feel discomfort in the post-op period that cannot be neglected, and sometimes serious complications because of negligent positioning on the operation table. In the light of benefit for the patients, it seems that due attention paid to these issues and details justify our full engagement.

Poklanjanje pažnje navedenim detaljima se može učiniti napornim i nepotrebnim, a problemi ove vrste u sklopu svih zahteva koji se pred anesteziologa danas stavljaju, marginalnim i nebitnim. Ipak, dugogodišnja klinička praksa je pokazala kako veliki broj pacijenata u postoperativnom periodu podnosi često ne male neprijatnosti, pa i znatne komplikacije zbog zanemarivanja pravilnog položaja na operacionom stolu. U smislu koristi koju ima pacijent, kome je u ovom smislu posvećena dužna pažnja, čini se da briga o navedenim detaljima i specifičnostima opravdava naše puno angažovanje.

FLUID RESUSCITATION

Rod J. Rohrich recorded that "dry" liposuction was associated with blood loss of 20 to 45% of the total blood volume aspirated. With the advent of epinephrine-containing wetting solution in the 1980s, blood loss was decreased to 15 to 30%, but fluid resuscitation was still targeted toward aggressive intravenous replacement of third-space losses and prevention of hypovolemia. Autologous blood transfusions and "preloading" were common. In 1986, Fodor introduced the super-wet technique in which 1:1 ratio of infiltrate to aspirate was used. In 1987, Klein reported successful results using the "tumescent" technique, which involves infiltration to the point of tissue turgor using an infiltrate to aspirate ratio of 3:1. Both techniques are associated with blood loss of 1% of the volume aspirated. This has led to larger volume aspirations and improved results.

No longer just a method of "spot reduction", liposuction has evolved into a true circumferential body sculpting procedure. By using subcutaneous infiltration in combination with newer instrumentation and UAL techniques, the surgeon can safely remove several liters of fat. Because of the relatively large volumes of fluid being given intraoperatively, inappropriate resuscitation and its inherent complications are greater concerns, especially in patients undergoing large-volume aspiration. Although sufficient fluid administration is necessary for prevention of hypovolemia, overzealous resuscitation should be avoided. Iatrogenic fluid overload may be harmful even in the healthy patients. Gilliland and Coates reported the development of pulmonary edema in a patient undergoing tumescent liposuction. This case as well as the several deaths resulting from inappropriate fluid management should alert the surgeon and anesthesiologist to the need for a systematic approach to fluid resuscitation in the liposuction patient. Infiltration of tumescent fluid is comparable to hypodermoclysis, the injection of large volumes of fluid into subcutaneous tissues for hydration. One early study showed that when 1 L of

RESUSCITACIJA TEČNOSTI

Rod J. Rohrich navodi podatak da je "suva" liposukcija bila povezana sa gubitkom krvi od 20-45% od ukupne količine usisane tečnosti. 1980. sa pojavom epinefrina koji sadrži rastvor za infiltraciju, smanjio se i gubitak krvi na 15-30%, ali je i dalje bila ciljna tačka fluidna infiltracija nasuprot agresivne intravenozne nadoknade gubitka trećeg prostora i prevencija smanjenja zapremine krvi. Česti su bili autologna transfuzija kao i predohrana. 1986. Fodor je izložio super vlažnu tehniku u kojoj je razmera infiltriranja i usisavanja 1:1. 1987. Klein je dao izveštaj o uspešnim rezultatima pri korišćenju tehnike "otoka" koja uključuje infiltraciju tečnosti u željeni region do stvaranja tkivnog otoka koristeći odnos infiltriranja i usisavanja 3:1. Obe tehnike su vezane za gubitak krvi od 1% u odnosu na usisanu količinu. To je dovelo do većeg obima usisavanja i do poboljšanih rezultata.

Nije dugo potrajalo i liposukcija se razvila od metode "redukcije dela tela" u pravu proceduru klesanja i oblikovanja tela. Korišćenjem potkožnog ubacivanja tečnosti u kombinaciji sa novijim instrumentima i UAL tehnikama, hirurg može bezbedno da otkloni nekoliko litara masnog tkiva. Kod pacijenata koji se podvrgavaju opsežnoj liposukciji, posebna je briga nedovoljna resustitucuja velikih predela i komplikacije koje su tome svojstvene, a sve zbog davanja relativno velikih količina tečnosti u toku operacije. Iako je neophodna upotreba dovoljne količine tečnosti radi prevencije hipovolemije, treba izbegavati preterano revnosnu nadoknadu tečnosti. Preterivanje sa jatrogenom tečnošću može biti štetno čak i kod zdravih pacijenata. Gilliland i Coates su u svom izveštaju izneli slučaj razvoja plućnog edema kod pacijenta podvrgnutom liposukciji "otokom". Ovaj slučaj kao i nekoliko slučajeva smrti kao posledica neodgovarajućeg doziranja tečnosti treba da opomenu hirurga i anesteziologa na neophodnost sistematskog prilaza nadoknadi tečnosti kod pacijenata podvrgnutih liposukciji. Infiltracija fluida u oteklinu može se uporediti sa potkožnim klizmama, injekcijama velikog volumena tečnosti u potkožna tkiva radi hidratacije. Jedna

isotonic fluid was subcutaneously injected into the medial thigh, absorption took an average of 167 minutes. The rate of absorption depends on the vascularity of the injected tissue and the variables associated with the Starling equation. Quantification of infiltrate absorption is further complicated by the removal of infiltrate in the aspirate. However, studies have shown that most of the infiltrate is not removed during liposuction. Our experience coincides with reports by Sameul J. Bern and shows that 25 to 30% of the infiltrate is removed during UAL, which is in agreement with findings of other authors. Approximately 70% of the infiltrate remain after liposuction and are absorbed into the intravascular space over 6 to 12 hours after surgery. This must be considered in the patient's overall fluid resuscitation.

Perioperative fluid management during liposuction must take into account maintenance intravenous fluid, replacement of third-space losses, volume of isotonic infiltrate, and volume of aspirate. Preexisting fluid deficits are usually not considered because current preoperative guidelines allow patients to consume clear liquids up to 2 hours before surgery. We consider liposuction to represent "moderate" surgical trauma; based on standard anesthetic guidelines, administration of 5 to 6 ml/kg/hr of crystalloid is an adequate volume for maintenance fluid and third-space losses. Blood loss, which is roughly 1% of the aspirate, is considered minimal when using either the superwet or the tumescent technique and is not replaced. We advocate giving additional fluid only after removal of the first 5 L in ratio 0.25 ml of crystalloid for each milliliter aspirated.

Jeffrey M. Kenkel gave the following recommendations for intraoperative fluid delivery:

1. Crystalloid at a maintenance rate of 5mg/kg/hr adjusted according to vital signs and urine output
2. Intravenous fluid in a volume of 0.25 ml for each milliliter aspirated over 5 L.
3. Superwet infiltration.

These guidelines were developed after a review of 100 consecutive liposuction procedures using superwet infiltration and combination of SAL and UAL techniques. Standard noninvasive hemodynamic parameters and urine output were used to evaluate the patients' volume status. All patients did well and experienced no episodes of clinical hypovolemia or fluid overload. Urine output remained within an acceptable range (0.5 to 1 ml/kg/hr). Hospital courses were short and uneventful and 90% of patients were discharged by postoperative day one.

The following formula provides an intraoperative fluid ratio (IFR) of approximately 1.2 to 1.5, which we consider safe for large-volume aspirations:

ranija studija pokazala je da kada se 1l izotoničnog fluida ubrizga potkožno u srednji deo bedra, za apsorpciju je potrebno u proseku 167 minuta. Vreme apsorpcije zavisi od vaskularizacije tkiva u koje je infiltrisana tečnost i od promenljivih činilaca u Starlingovoj jednačini. Određivanje količine infiltrata koja se apsorbuje dalje je komplikovano zbog vađenja filtrata iz aspiratora. Ipak, istraživanja su pokazala da većina infiltrata ne bude odstranjena u toku liposukcije. Naša iskustva se poklapaju sa navodima Samuela J. Berna i pokazuju da se 25-30% infiltrata otkloni u toku UAL , što je u skladu i sa nalazima i drugih autora. Približno 70% infiltrata ostaje nakon liposukcije i bude apsorbovano u međuvaskularni prostor u toku prvih 6-12 časova nakon operacije. Ovo se mora uzeti u razmatranje pri ukupnoj fluidnoj resuscitaciji kod pacijenta.

Pri doziranju tečnosti u toku liposukcije mora se uzeti u obzir održavanje intravenozne tečnosti, nadoknada gubitaka trećeg prostora, količina izotoničnog infiltrata i količina aspirata. Kako je pacijentima dozvoljeno da do 2 sata pre operacije piju tečnost, ne uzima se u obzir mogućnost preoperativnog gubitka tečnosti. Smatramo liposukciju umerenom hirurškom traumom koja se bazira na klasičnoj anestetičkoj proceduri i davanju kristaloida 5-6ml/ kg/na sat, što predstavlja odgovarajuću količinu za održavanje tečnosti i gubitaka trećeg prostora. Gubitak krvi u grubom iznosu od 1% u toku usisavanja, smatra se minimalnim kada se koristi bilo supervlažna ili tehnika "otoka" i on se ne nadoknađuje. Preporučujemo dodatno davanje tečnosti samo nakon otklanjanja prvih 5 l u razmeri od 0.25ml kristaloida za svaki mililitar usisanog.

Preporuke za obezbeđivanje tečnosti u toku operacije su date od strane Jeff Reu M. Kenkela:

1. kristaloid u količini za održavanje od 5mg/kg/sat davano u skladu sa vitalnim funkcijama i proizvodnjom urina.
2. Intravenozni fluid u količini od 0.25ml za svaki mililitar usisanog preko 5litara.
3. Supervlažna infiltracija.

Do ovih uputstava se došlo nakon pregleda 100 uzastopnih liposukcija gde se koristila supervlažna infiltracija i kombinacija SAL i UAL tehnika. Koristili su se standardni hemodinamski parametri i proizvodnja urina, kako bi se utvrdilo stanje pacijenta. Svim pacijentima je bilo dobro i nije bilo slučajeva kliničke hipovolemije ili preterivanja sa tečnošću. Proizvodnja urina je ostala u granicama prihvatljivog (0.5-1ml/kg/sat). Bolnički tok je bio kratak i bez nekih posebnosti i 90% pacijenata bilo je otpušteno prvog postoperativnog dana.

Ovo je formula koja obezbeđuje razmeru tečnosti u toku operacije (IFR=Intraoperativna Fluidna Razmera) otprilike 1.2 do 1.5 koju autor smatra bezbednom za usisavanje velikih površina:

IFR = (intravenous fluid+infiltrate): volume suctioned = 1.2 to 1.5

If this formula is used, the patient having small volumes aspirated will have a larger IFR of approximately 2.0, which is acceptable for aspiration of less than 5 l.

Of course, these guidelines must be supplemented by clinical judgement. Standard intraoperative monitoring during liposuction includes the use of pulse oximetry, EKG, FiO_2 analyser, noninvasive blood pressure determination, and measurement of end-tidal CO_2. Fluid administration can then be adjusted in response to the above-measured parameters.

WETTING SOLUTIONS

Standard formulations of wetting solutions include a mixture of lidocaine and epinephrine added to 1 l of either lactated Ringer's solution or normal saline solution (0.9% NaCl). However, there are several popular variations of this formula.

KLEIN'S FORMULA

0.9% NaCl .....1000 ml
1% lidocaine .....50 ml
8.4% $NaHCo_3$.....12.5 ml
1:1000 epinephrine 1ml

HUNSTAD'S FORMULA

Ringer's lactate solution .....1000 ml at 38-40 °C
1% lidocaine 50ml
1:1000 epinephrine 1ml

FODOR'S FORMULA

Ringer's solution.....1000ml
aspirates <2000ml
1:500 epinephrine 1ml
aspirates 2000-4000ml
1:1000 epinephrine 1ml
aspirates >4000ml
1:1500 epinephrine 1ml

SOUTHWESTERN TEXAS UNIVERSITY MEDICAL CENTER'S FORMULA

Ringer's solution.....1000ml at 21°C
Aspirates < 5000 ml
1% lidocaine 30ml
aspirates > 5000 ml
1% lidocaine 15ml
1:000 epinephrine 1ml

IFR= (fluid intravenozno + infiltrat): količina usisanog = 1,2 do1,5

Ako se koristi ova formula, pacijenti sa manjim reduciranim površinama imaće veći IFR od otprilike 2.0, što je prihvatljivo za usisavanja manja od 5l.

Naravno, ova uputstva se moraju potkrepiti kliničkom procenom. Standardna procedura praćenja u toku zahvata liposukcijom podrazumeva diurezu pulsnu oksimetriju, EKG, analizu FiO_2, merenje krvnog pritiska i merenje CO_2 u ekspiratorijumu. U skladu sa gornjim merenjima može se administrirati tečnost.

RASTVORI ZA INFILTRACIJU

Standardno formula za rastvore za infiltraciju uključuje mešavinu lidokaina i epinefrina dodatu u 1litar Ringer rastvora ili 0,9%NaCl rastvora. Ipak, postoji nekoliko popularnih varijacija ove formule.

FORMULA KLEIN

0,9%NaCl..... 1000ml
1% lidokain 50ml
8.4% $NaHCo_3$.....12.5 ml
1:1000 epinefrin 1ml

FORMULA HUNSTAD

Ringer laktat ..... 1000ml na 38-40°C
1% lidokain 50ml
1:1000 epinefrin 1ml

FORMULA FODOR

Ringerov rastvor 1000ml
kod usisavanja <2000ml
1:500 epinefrin 1ml
kod usisavanja 2000-4000ml
1:1000 epinefrin 1ml
kod usisavanja >4000ml
1:1500 epinefrin 1ml

FORMULA MEDICINSKOG CENTRA JUGOZAPADNOG TEKSAŠKOG UNIVERZITETA

Ringerov rastvor .....1000ml na 21°C
kod usisavanja <5000ml
1% lidokain 30ml
kod usisavanja >5000ml
1% lidokain 15ml
1:000 epinefrin 1ml

In addition to its well-documented hemostatic and analgesic effects, subcutaneous infiltration plays an essential role in UAL. The cavitation phenomenon of UAL requires a wet environment. In addition, the wetting solution helps dissipate heat that is generated by ultrasound. Laboratory studies by Ablaza et al. showed that application of ultrasound energy in a nontumescent environment generated very high temperatures. Further clinical studies by this same group demonstrated that the infiltrate should be given at room temperature (about 21°C) not at body temperature as initially thought. Room- temperature fluids avoid temperature elevation, which could result in vasodilatation or even a burn.

Lidocaine

Lidocaine is the local anesthetic generally used in the tumescent fluid. Since lidocaine has been documented to provide clinical analgesia for up to 18 hours postoperatively, the risk posed by a more potent, longer acting agent such as bupivicaine is unwarranted. Although the recommended maximal dosage for subcutaneously injected lidocaine with epinephrine is 7mg/kg, multiple studies have shown that this limit is safely exceeded during liposuction procedures. In 1990 Klein demonstrated that tumescent fluid containing up to 35 mg/kg of lidocaine results in peak plasma levels below the toxic range of 3 μg/ml. The extensive dilution and slow infiltration of the tumescent fluid delay absorption and reduce the peak serum level. Other factors that are thought to contribute to the safety of large doses of lidocaine in tumescent fluid are the vasoconstrictive effect of epinephrine, the relative avascularity of the fatty tissue, the high lipid solubility of lidocaine, and compression of the vasculature by the large volume of tumescent fluid delivered. Other authors have advocated even higher lidocaine dosages in the 55 to 90 mg/kg. However, Rohrich's experience tells that most patients will still require supplemented postoperative analgesia and that pushing the limits of lidocaine toxicity is unnecessary. In their series of 100 patients, they never exceeded 35 mg/kg and no patient manifested clinical signs of lidocaine toxicity. The dosages of lidocaine used were as follows:

Lidocaine

Aspirate Volume (ml)	Average (mg/kg)	Range (mg/kg)
<4L	12.3	1.1-32.7
>4L	20.6	11.3-33.3

Pored dobro dokumentovanih hemostatskih i analgetskih efekata, potkožna infiltracija igra glavnu ulogu u UAL. Fenomen šupljine kod UAL zahteva vlažnu sredinu. Dodatno, rastvor pomaže rasipanje toplote nastale delovanjem ultrazvuka. Laboratorijska istraživanja koje je izveo Albaza pokazala su da upotreba energije ultrazvuka u sredini koja nije pod oteklinom razvija veoma veliku temperaturu. Dalja klinička istraživanja (isto Albaza) pokazala su da infiltrat treba da bude sobne temperature (oko 21°C) a ne telesne temperature, kako se ispočetka mislilo. Sobna temperatura omogućava normalnu telesnu temperaturu dok se izbegava rast temperature, što bi moglo izazvati vazodilataciju ili čak i opekotine

Lidokain

Lidokain je lokalni anestetik koji se uglavnom koristi u rastvoru za infiltraciju. Kako se pokazalo da lidokain obezbeđuje dobru kliničku analgeziju čak i po 18 sati postoperativno, pokazao se kao nepotreban rizik korišćenje nekog snažnijeg, dugotrajnijeg sredstva kao što je bupivakain. Iako je preporučena maksimalna doza za potkožno davanje lidokaina sa epinefrinom 7mg/kg, višestruke studije su dokazale da se ova granica može sasvim bezbedno prelaziti u toku liposukcije. 1990. Klein je demonstrirao da se tečnost za infiltraciju koja sadrži i do 35mg/kg lidokaina odražava u nivoima vrha plazma koncentracije ispod toksičnih granica od 3 mikrograma/ml. Krajnje razblažen rastvor i spora infiltracija tečnosti odlažu apsorpciju i smanjuju nivo vrha koncentracije seruma. Ostali faktori za koje se smatra da doprinose bezbednosti velikih doza lidokaina u tečnosti za infiltraciju suvazokonstriktivni efekat epinefrina, relativnu avaskularnost masnog tkiva, visoku moć lidokaina pri rastvaranju lipida, i kompresiju vaskulature kada se daje velika količina tečnosti za infiltraciju. Drugi autori su preporučili čak i veće doze lidokaina od 55-90mg/kg. Međutim, iskustvo Rohricha je da će većina pacijenata ipak zahtevati dodatnu postoperativnu analgeziju, pa je stoga nepotrebno količinu lidokaina približavati granici toksičnosti. U njihovoj seriji od 100 pacijenata, nikada nisu prešli dozu od 35mg/kg i nijedan pacijent nije pokazivao kliničke znake trovanja lidokainom. Preporučuju sledeće doziranje lidokaina:

Lidokain

Količina aspiriranog (ml)	Prosek (mg/kg)	Doza (mg/kg)
<4L	12.3	1.1-32.7
>4L	20.6	11.3-33.3

If using general anesthesia, total lidocaine dosage must be carefully monitored since early symptoms of toxicity are not readily apparent.

Alkalization of local anesthetic with bicarbonate has been shown to decrease pain. Although it is not necessary to add bicarbonate to tumescent fluid if patient is given general anesthetics, a significant reduction in patient discomfort has been reported in patients given local anesthetics alone.

The general safety of lidocaine dosages as described above has been established for the healthy patient. Lidocaine is a local amide anesthetic that is degraded in the liver, and the half-life may vary with hepatic function. Age and cardiovascular status may also affect plasma levels. These physiologic parameters should be addressed by the surgeon and anesthesiologist during the initial patient screening.

We adopted a slightly different approach. Patients operated under peridural anesthesia were not given lidocaine or any other local anesthetic in the tumescent solution. Although there are reports of lidocaine lipolitic effect, our experience was different, which is also the case with the majority of authors describing liposuction. Postoperative analgesia was obtained through a peridural catheter, incomparably more efficiently and with small medication quantity. The same applies to the group of patients given a combination of peridural and superficial anesthetics. The patients operated under general anesthetics, were added lidocaine into the tumescent solution. However, we never exceeded 7 mg/kg, and enhanced postoperative analgesia by parentheral or oral administration of analgesics.

Epinephrine (Adrenaline)

The hemostatic benefit of the addition of dilute epinephrine to the subcutaneous infiltrate is well documented in liposuction. The presence of epinephrine also decreases the rate of vascular absorption of lidocaine and potentates local anesthetics. The safety of epinephrine dosing has not been studied as extensively as that of lidocaine. Toxicity is manifested as tachycardia, hypertension, and arrhythmia. Burk at al. have proposed an upper safety limit of 10 mg. We have obtained consistently excellent hemostasis with the addition of 1ml of 1:1000 epinephrine (1mg) to each liter of infiltrate. Total epinephrine dosages have ranged from 0.3 to 12 mg and no patients in our series have shown evidence of toxicity.

Inhalation anesthetics, particularly halothane, can sensitize the heart to catecholamines. This means that less epinephrine is required to induce ventricular arrhythmia in patients given volatile inhalation anesthetics than in awake patients. Both clinical and laboratory

Ako se koristi opšta anestezija, ukupna doza lidokaina mora pažljivo da se prati jer se rani simptomi predoziranja lako mogu prevideti.

Alkalinizacija lokalnih anestetika sa bikarbonatom dokazala se kod olakšavanja bolova. Iako nije neophodno da se doda bikarbonat u tečnost za infiltraciju, kada je pacijentu data opšta anestezija, zabeleženo je značajno smanjenje neugodnosti kada je pacijentu davan samo lokalni anestetik.

Gore navedene doze lidokaina su ustanovljene kao bezbedne po zdravlje pacijenta. Lidokain je srednji lokalni anestetik koji se razgrađuje u jetri, i njegovo vreme razlaganja može varirati sa funkcijom jetre. Godine i kardiovaskularno stanje takođe mogu uticati na nivoe plazme. Ovi fiziološki parametri moraju da budu uputni za hirurga i anesteziologa u toku inicijalnog pregleda pacijenta.

Naš pristup je nešto drugačiji. Za pacijente koje smo operisali u periduralnoj anesteziji nismo koristili lidokain, niti bilo koji drugi lokalni anestetik u tečnosti za infiltraciju. Iako je u pojedinim tekstovima opisan lipolitički efekat lidokaina, u svojoj praksi nismo stekli slično iskustvo, niti je to slučaj sa većinom autora o liposukciji. Postoperativnu analgeziju smo obezbeđivali preko periduralnog katetera, neuporedivo efikasnije i sa malom količinom medikamenata. Isto se odnosi i na grupu pacijenata koji su primili kombinaciju periduralne i površne opšte anestezije. Pacijentima koji su operisani iz bilo kog razloga u opštoj anesteziji, dodavali smo lidokain u tečnost za infiltraciju, ali nikad više od 7 mg/kg, a postoperativnu analgeziju smo potencirali davanjem analgetika parenteralno ili oralno.

Epinefrin

U liposukciji se dobro dokazao hemostatički uticaj koji se postiže dodavanjem epinefrina u potkožni infiltrat. Prisustvo epinefrina, takođe, smanjuje porast vaskularne apsorpcije lidokaina i mogućih lokalnih anestetika. Bezbednost doziranja epinefrina nije se intenzivno proučavala kao u slučaju lidokaina. Predoziranje se manifestuje tahikardijom, povišenim krvnim pritiskom i aritmijom. Burk je predočio gornju bezbedonosnu granicu od 10mg. Mi smo stalno postizali odličnu hemostazu dodavanjem 1ml razblaženog 1:1000 epinefrina (1mg) na svaki litar infiltrata. Krajnja količina epinefrina dostizala je 0.3-12mg i ni jedan pacijent iz naše serije nije pokazivao ikakve znake predoziranja.

Anestetici koji se inhaliraju, posebno halotan, mogu senzibilizovati srce na kateholamine. To znači da je potrebno manje epinefrina da bi se izazvala ventikularna aritmija kod pacijenata koji su udisali isparljive anestetike, nego kod budnih pacijenata. I klinička i laboratorijska

studies have shown halothane to be more arrhythmogenic than other inhalation agents in the presence of epinephrine. These findings suggest that although lidocaine may be protective against arrhythmia, halothane should not be used during liposuction.

istraživanja pokazala su da halotan u prisustvu epinfrina stvara više aritmija nego bilo koje drugo sredstvo za inhalaciju. Ovi nalazi upućuju da iako je lidokain zaštita protiv aritmije, halotan ne bi trebao da se koristi u procesu liposukcije.

Postoperative Care

Postoperative Nausea and Vomiting

We find that postoperative nausea and vomiting is generally well controlled by prophylactic treatment. If the patient experiences nausea and vomiting during recovery, the addition of 12.5 mg I.V. phenergan may be useful.

Hydration

The patient's fluid status is followed carefully in the postoperative setting. Although we are concerned about overresuscitation, third-space losses can continue, and the patient's urine output and vital signs are monitored closely to adjust administration of maintenance fluid. Foley catheters placed in patients having large-volume liposuction are removed on the first postoperative morning.

Ambulation and Discharge

Early postoperative ambulation is essential for prevention of deep vein thrombosis and pulmonary embolism. It is necessary to mention at this point that all our patients were given such well-adjusted analgesic doses of the local anesthetic perioperatively administered through the peridural catheter that they were able to stand and walk almost immediately after the completion of the surgery. Since these doses attain only insignificant blockade of the motor neuron, it was raised by inducting peridural catheter, not by increasing volume and concentration of the local anesthetic. In this way, the

Postoperativna nega

Postoperativna mučnina i povraćanje

Otkrili smo da su postoperativna mučnina i povraćanje pod dobrom kontrolom ukoliko se sproveo profilaktički tretman. Ako pacijent pati od mučnine i povraćanja u toku oporavka, od pomoći može biti dodatnih 12.5mg i.v. fenergana.

Hidratacija

Stanje tečnost kod pacijenta se pažljivo meri u postoperativnom toku. Iako smo zabrinuti zbog preterane nadoknade tečnošću, može se nastaviti gubitak u trećem prostoru, tako da se proizvodnja urina i vitalni znaci pažljivo prate da bi se ispravno administrirala tečnost za nadoknadu. Prvog posteperativnog jutra uklanjaju se folijevi katetri koji se postavljaju kod pacijenata sa obimnom liposukcijom.

Ambulacija i otpust

Rana postoperativna ambulacija je neophodna za prevenciju tromboze dubokih vena i plućne embolije. Ovde je bitno napomenuti da su svi naši pacijenti zahvaljujući prilagođenoj analgetičkoj dozi lokalnog anestetika koja je davana kroz periduralni kateter perioperativno bili u mogućnosti da ustanu i hodaju skoro neposredno posle završetka operativnog zahvata. S obzirom da navedeno doziranje samo neznatno vrši blok motornog neurona, a da smo visinu bloka postizali visinom uvođenja periduralnog katetera, a ne volumenom i koncentracijom lokalnog anestetika i uticaj na simpatikus je

simpathicus was less affected and prolonged hypotension periods were avoided so that the patients could leave the bed earlier.

Patients having small volumes removed are usually discharged on the same day of surgery. After large-volume aspiration patients begin ambulating on the night of surgery and are usually discharged on the first postoperative day.

bio manji. Tako su izbegnuti dugi periodi hipotenzije i omogućeno ranije ustajanje.

Pacijenti kojima je liposukcijom otklonjena mala količina masnog tkiva, otpuštaju se istog dana po zahvatu. Nakon usisavanja velikih količina pacijenti se ambuliraju te noći nakon operacije i bivaju obično otpušteni prvog postoperativnog dana.

Appendix / Dodatak

Equipment for UAL and SAL
Oprema za UAL i SAL

What do you need to start your aesthetic plastic surgery work?

Ultrasound Generators

Alone or combined with sainfiltration-aspiration systems.

1. *SMEI Sculpture* (solid probe, Generator 23 kHz), US$ 27,000
2. *Mentor Counter Genesis* (Hollow and Solid probe, 27 kHz, Infiltration and Aspiration system included), US$ 45,000
3. *LySonix 2000* (hollow and solid probe, 22.5 kHz; infiltration and aspiration system included)







Infiltration - Irrigation System

Madtec Infiltration pump (US$ 1500 - 2000)
Nouvag Infiltration pump (US$ 1500 - 2000)

Aspiration Systems

Aesculap (D) (oil pump), US$ 4000
ATMOS (D) (membrane pump), US$ 4000
Nouvag - (CH) (membrane pump), US$ 3500

Šta vam je potrebno da bi ste počeli sa radom u estetskoj plastičnoj hirurgiji?

Ultrazvučni generatori

Samostalno ili u kombinaciji sa sistemima za sainfiltraciju-spiraciju.

1. *SMEI Sculpture* (sonda, generator 23kHz), US$ 27.000
2. *Mentor Counter Genesis* (šuplja i čvrsta sonda, 27 kHz, sa uključenim sistemom za infiltraciju i aspiraciju), US$ 45.000
3. *LySonix 2000* (šuplja i čvrsta sonda, 22,5 kHz, sa uključenim sistemom za infiltraciju i aspiraciju)

Sistem za infiltraciju - irigaciju

Madtec infiltraciona pumpa (US$ 1500 - 2000)
Nouvag infiltraciona pumpa (US$ 1500 - 2000)

Sistemi za aspiraciju

Aesculap (D) (uljna pumpa), US$ 4000
ATMOS (D) (membranska pumpa), US$ 4000
Nouvag - (CH) (membranska pumpa), US$ 3500

Infiltration & Aspiration Cannulas

Madtec -Medicon .....US$ 80-150

Kanile za infiltraciju i aspiraciju

Madtec -Medicon .....US$ 80-150

Compression Garments

(Compression Postoperative Garments) EU Prices,
Mad-Tec Superpanty

Superpanty Long .....US$ 200
Superpanty Short.....US$ 200
Abdominal Panty.....US$ 105
Abdominal Bandage .....US$ 100

Note:
All prices are approximate, based on the information we received from the manufacturers and does not include VAT and other expenses. We do not guarantee for any information regarding technical data or prices. They are only approximate and serve only as guidelines. For all orders, please contact either *Madtec International Belgrade* or *Madtec GmbH in Germany*.

Kompresivni veš

(Kompresivni postoperativni veš) evropske cene,
Mad-Tec Superpanty

Superpanty dugačke.....US$ 200
Superpanty kratke.....US$ 200
Abdominal Panty (za stomak) .....US$ 105
Abdominal Bandage (zavoj za stomak).....US$ 100

Napomena:
Sve cene su približne, na osnovu informacija dobijenih od proizvođača, in e uključuju porez i ostale troškove. Ne garantujemo za informacije o tehničkim podacima i cenama. Oni su samo približni. Za sve porudžbine molimo da kontaktirate *Madtec International Belgrade ili Madtec GmbH u Nemačkoj*.

Bibliography / Literatura:

UAL (Ultrasound Assisted liposuction) & SAL (Suction Assisted Liposuction)/
Ultrazvukom asistirana liposukcija i Sukcijom asistirana liposukcija

1. Rorhich, Beran, Kenkel, *Ultrasound Assisted Liposuction*, Quality Medical Publishing, Inc. St. Louis, Missouri, 1998.
2. Klein JA, *The Tumescent Technique for Liposuction Surgery*. Am J Cosmetic surgery 4:263, 1987.
3. Fodor PB. *Wetting Solutions in Aspirative Lipoplasty: A Plea of Safety in Liposuction Surgery*, Aesthetic Plastic Surgery, 18:372, 1995.
4. Pitman GH, Liposuction and Aesthetic Surgery: St. Louis, Quality Medical Publishing, 1993.
5. Zocchi M., *Ultrasonic Assisted Lipoplasty*. *Technical Refinements and Clinical Evaluations*, Clin Plast Surg 23:575, 1996.
6. Zocchi M. *Prospective in Lipoplasty: The Ultrasonic-Assisted Lipoplasty (UAL)*. Paper presented at the French Society of Aesthetic Surgery. May, 1988.
7. Bandic, *Ciric personal communication*, 1999.
8. Gasparotti, *Superficial Liposuction*; Book issued.
9. Gasparotti, *Ciric personal communication*, 1994.
10. Katalinic, *Ciric personal communication*, 1997.
11. Malivukovic, *Ciric personal communication*, 1999.
12. Ciric, Malivukovic, *Lecture on World Congress on Liposuction Surgery*, 14.10.2000.
13. Dr. Santiago Trunó Reina: *Extract from Medicina Estetika,* published by the Spanish Association of Aesthetic Medicine, Barcelona.
14. Lemperle, *Aesthetische Chirugie*, 1999.
15. *Medicon and Madtec company information*, 1998/1999.

Laser and Radiofrequency Assisted Horizontal Abdominoplasty/
Laserom i radiofrekvencijom asistirana horizontalna abdominoplastika

1. Katalinic, Ciric Personal Communication: *Combined CO_2 and Nd:YAG Laser Beam and bloodless cut*, Nuremberg, Germany, 1996.
2. Ethicon and Madtec representatives and Ciric personal communication: *Bipolar Madtec Radiofrequency Unit and Ethicon Bipolar Scissors in the field of Plastic and Reconstructive Surgery,* 1999.

Histological structure of the skin/
Histološka organizacija kože

1. Baker H: *The skin as a barrier*, in: Textbook of dermatology, Eds. A Rook et al, 4th Ed, Blackwell, Oxford, 355-365, 1990.
2. Boyce ST: *Epidermis as a secretory tissue*, J Invest Dermatol 102, 8, 1994.
3. Damjanov I: *Histopathology*, Williams and Wilkins, Baltimore, 395-410, 1996.
4. Fitzpatrick T, et al: *Dermatology in general medicine*, McGraw-Hill, New York, 1987.
5. Freedberg IM: *Epidermal differentiation and keratinization*, in: Dermatology in general medicine, Eds. T Fitzpatrick et al, McGraw-Hill, New York, 174-184,1987.
6. Hoolbrook KA, Wolff k: *The structure and development of skin*, in: Dermatology in general medicine, Eds. T Fitzpatrick et al, Mcgraw-Hill, New York, 95-131, 1987.
7. Kerr JB: *Atlas of functional histology*. Mosby, London, 2000.
8. Lačković V: *Histologija-Epitelna tkiva*, Nauka, Beograd, 1998.
9. Lačković V, Bumbaširavić V, Vuzevski V: *Histološki atlas*, Vladimir, Beograd, 2000.
10. Lačković V, Trpinac D. *Histološka organizacija kože*, u Virusne osipne gronznice, Zavod za udžbenike i nastavna sredstva , Beograd, 2001, 3-19.
11. Lever WF, Schaumburg-Lever G: *Histopathology of the skin*, 7th Ed, JB Lippincot Company, Philadelphia, 1990.
12. Nashimura H: *Atlas of human prenatal histology*, Igaky-Shoin, Tokio, 5-18, 1983.
13. Ortonne J-P, Prota G: *Hair melanins and color: Ultrastructural and biochemical aspects,* J Invest Dermatol 101, 82, 1993.
14. Robertshaw d: *Biology of apocrine sweat glands,* Dermatology in general medicine, Eds. T Fitzpatrick et al, McGraw-Hill, New York, 209-212,1987.
15. Sato K: *Biology of eccrine sweat glands*, in: Dermatology in general medicine, Eds. T Fitzpatrick et al, McGraw-Hill, New York, 195-208, 1987.
16. Stevens A, Lowe J.: *Human histology*. Mosby, London, 1997.
17. Stevens A, Lowe J.: *Pathology*. Mosby, Edinburgh, London, 2000.